

# A modified sandwich technique in osteolytic lesions around knee: A prospective study for functional and radiological outcome

Jayant Sharma<sup>1</sup>, Prashant Upadhyaya<sup>2,\*</sup>

<sup>1</sup>Professor, <sup>2</sup>Assistant Professor, Dept. of Orthopaedics, Index Medical College and Research Centre, Indore, Madhya Pradesh, <sup>2</sup>Amaltas Medical College, Indore, Madhya Pradesh, India

**\*Corresponding Author: Prashant Upadhyaya**

Email: [jayantjaikishansharma@gmail.com](mailto:jayantjaikishansharma@gmail.com)

## Abstract

**Aim:** The purpose of the study was to evaluate the functional and radiological results of bone grafting combined with cementing with a gel foam mettle (sandwich technique) in osteolytic lesions around the knee, which include Giant cell tumors and Chondromyxoid fibroma, and Chondroblastoma.

**Materials and Methods:** We had 14 patients of such tumours who were evaluated and treated with extended curettage phenol painting followed by reconstruction of the cavity using a layer of gel foam followed by bone graft and bone cement. The modified technique which we followed included gel foam followed by bone graft followed by another layer of gel foam then bone cement. The period of study was from 2015 to 2019. With average follow up of 2 years.

**Result:** The results were evaluated using the musculoskeletal tumor society scoring (MSTS) and average score in our patient was 24. There were no recurrence noted as lysis of more than 5mm at bone cement interface.

**Conclusion:** We conclude that Modified Sandwich technique provided better prognosis and early resuming of activity. This technique with low rate of recurrence can be applied to all juxta articular tumors with good to excellent results. The only drawback of series was a short follow up.

**Keywords:** Chondromyxoid fibroma, Chondroblastoma, Giant cell tumors, Modified Sandwich technique.

## Introduction

The osteolytic lesions around the knee are most commonly seen in second or third decade of life in otherwise active patients, as a chance diagnosis for pain and swelling around the knee.

The commonly occurring lesions around knee include, Giant cell tumour, Chondromyxoid fibroma, Chondroblastoma to name a few.

Tumours like Simple bone cyst, Aneurysmal bone cyst are lower physeal tumours comparatively.

The epiphyseal tumours have a problem of breach of the physis on weight bearing, and some are locally aggressive which can damage the weight bearing cartilage, in the form of thinning out.

Previously the tumours were treated by curettage alone or with carbolic cauterization or cryosurgery, or curettage and bone grafting or only cementing.

All these techniques have a high rate of recurrence in locally aggressive tumours in variable degrees. Sandwich technique involves use of intralesional curettage, phenol carbolization of cavity filling with gel foam bone grafts and bone cement, and this has the advantage as it could help to restore the articular depression and prevent the recurrence.

In our series of 14 cases, we evaluated the radiological outcome, and functional outcome which was graded on MSTS scale.

## Materials and Methods

14 patients were included in our study who came for treatment between April 2015 to February 2019, these were evaluated radiologically, including the knee series x-rays, chest x-rays, and haematological survey was performed.

MRI was done to find out the extent, soft tissue spilling, and epiphyseal thinning or defect.

The cases of Giant cell tumor were graded according to Campanacci Grading, (1) as,

Grade I = Well defined margins and intact cortex.

Grade II = Relatively well defined margin with no radioopaque rim and thinned out cortex, moderately expanded cortex.

Grade III = Indistinct borders and cortical destruction

We had 2 cases of Chondromyxoid fibroma, 1 case of Chondroblastoma and remaining 11 cases were of Giant cell tumor. Mainly involving tibia in 9 cases, and 5 cases were of femoral condyles out of which 2 were medial condyle of femur and 3 lateral condyle.

## Modified Technique

Through a large cortical window, the tumor were curetted until normal punctate bleeding bone. The cavity was inspected with a dental mirror. Then cleaned with pulsatile lavage, 5% phenol and phenol soaked gauze was placed inside the cavity for 5 mins. Care was taken not to spill the phenol in surrounding tissue. A layer of gel foam was applied all around the cavity as a layer mainly on the under surface of subchondral bone. This prevented the dislodgement of the bone graft and penetration into the joint. Also it helped in maintaining the contour of the articular surface.

Bone grafts were then placed next, below the gel foam layer around 2cm thick slivers were placed, this was followed by Gel foam lastly the whole of the remaining cavity is packed with bone cement.

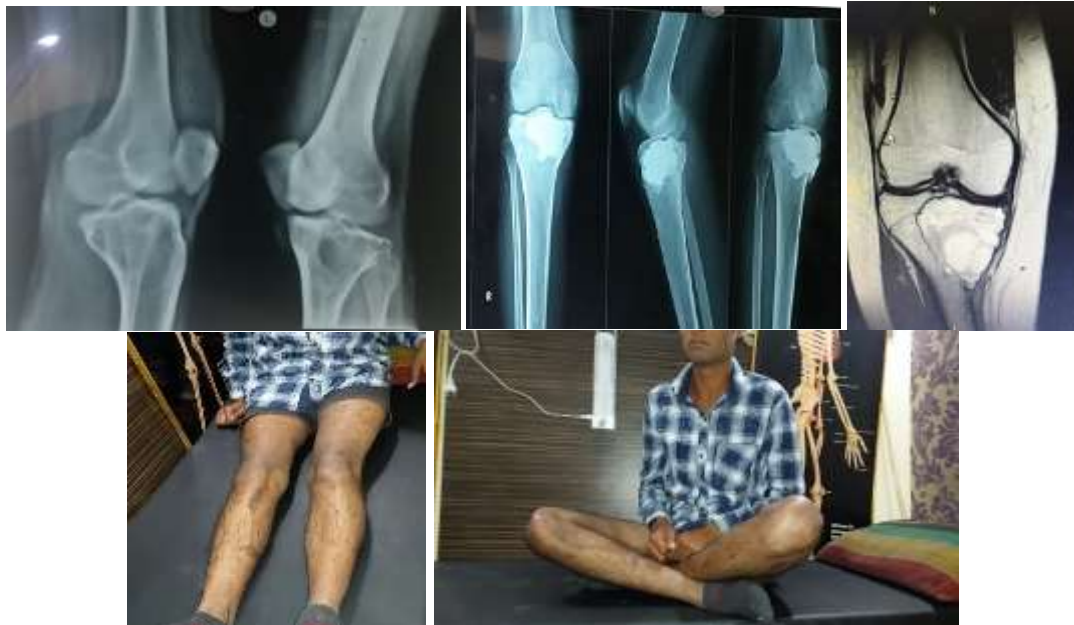Postoperatively, non-weight bearing crutch walking was started immediately and full weight bearing was allowed after 16 weeks.

All the patients were given a long knee brace for 4 weeks followed by knee ROM brace for a period of further 16 weeks. Bisphosphonates, Vitamin D and Calcium were used in all patients. None of the patients were given any fixation, external or internal.

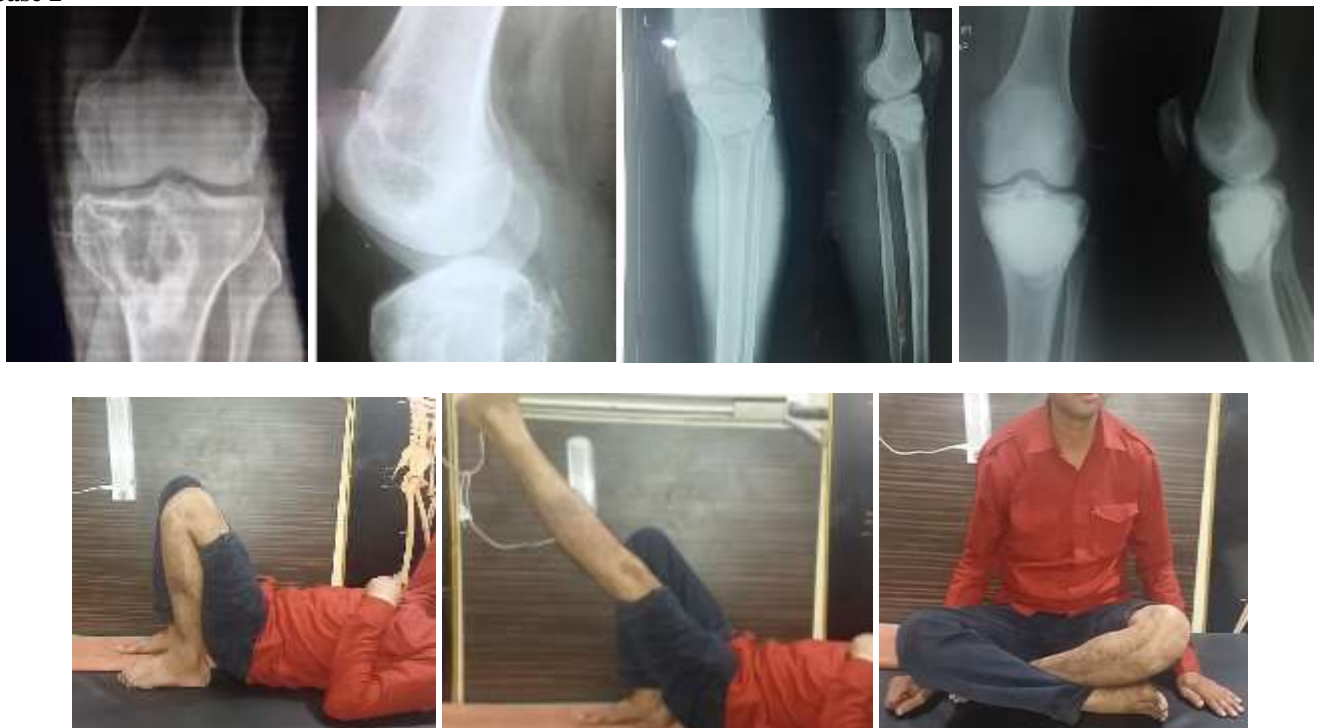Radiological outcome was assessed as progressive lysis of 5mm at bone cement interface or absence of sclerotic rim at bone cement interface.

Functional outcome was assessed using musculoskeletal tumor society score, which included 6 parameteres namely, pain functional, emotional acceptance, use of walking aid, walking ability and gait.

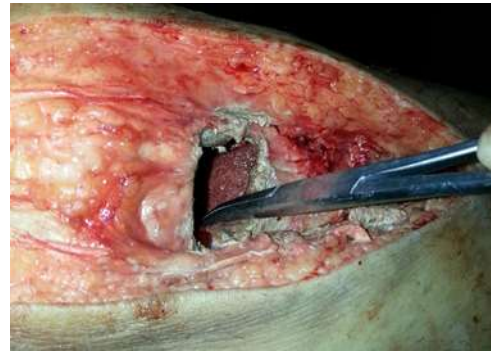
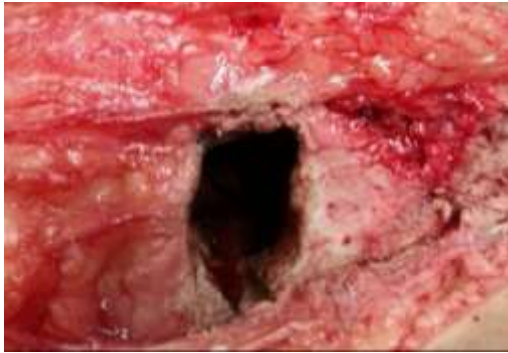**Case 1**



**Case 2**



### Intraoperative Cavity curetted, & Gel foam placement



### Result

The mean follow up of the study cases was 2 years and 6 months. And the Mean MSTS was 24. The age gender tumor grade and recurrence did not affect functional outcome.

There was no radiological lysis at the end of two and half years. No patient had any malignant transformation.

There were no cases with any infection or pathological fracture.

### Discussion

The preservation of joint function after a juxta articular tumor reconstruction is the mainstay in management and to achieve good functional results. The recurrence can be prevented by thorough curettage and lavage along with proper packing of bone graft and cement.

The age sex ratio in our series was similar and comparable to various available studies. In our series the age predilection was second and third decade with slightly male preponderance.<sup>2,3</sup>

The tumors like GCT and Chondroblastoma are locally aggressive and require aggressive treatment.<sup>1,4</sup>

Because of high rate of recurrence and major complications of en bloc resection, intralesional treatment was revisited with introduction of PMMA bone cement.<sup>5,6</sup>

O' Donnell in his series reported a rate of 25% recurrence with curettage and bone cement, but there are acceptable rate of local control with autogenous bone graft packing.<sup>7-10</sup>

There are various studies which state the efficacy of cementing with low rate of recurrence, like, Kafichitsas in 2010 in his series had a rate of only 23% which was lower than 52.9% with only cancellous bone grafting.<sup>4-6</sup>

In the series of Ward et al.<sup>11</sup> only 6.4% recurrence rate was found with curettage, phenol, hydrogen peroxide, mechanical burring, and reconstructing with PMMA.

We sparingly avoided use of Phenol to only those cases where there was no soft tissue extension of tumour to avoid its toxicity. This has been reported in available series.<sup>12</sup>

The use of Bisphosphonates, Vitamin D and calcium supplement inhibit bone resorption by osteoclasts, as both multinucleated giant cells and osteoclasts are similar as they resorb the bones<sup>13,14</sup> and they have no effect on reparative mechanism and osteoblasts.

The early functional results were encouraging as the MSTS was upto 24 signifying that there was a good quality of life achieved in these tumorous conditions in our series

Change in functional grade had no correlation to Gender, in our series alike to series of Tain Hsuing Chen et al.<sup>15</sup>

The cellular atypia was not seen in even stage III Campanacci, by Jones et al<sup>16</sup> hence the recurrence was not due to cellular atypia but local seedlings left over or incomplete curettage.

Similarly Tain Hsuing Chen also did not show any correlation in grade and functional and radiological outcome.<sup>15</sup>

### Conclusion

In our series we got significantly heartening result in the form of good functional regainment along with no recurrence and no radiological loss of cement bone interface, signifies the need of aggressive management of these type of tumours. However a longer follow up and large series is required to reproduce it in majority of patients.

**Conflict of Interest:** None.

### References

1. Campanacci M. Giant cell tumor. In: Gaggi A (ed) Bone and soft-tissue tumors. Springer, Bologna: 1990;117-153.
2. Ankening WF. Staging of Musculo Skeletal tumors: Ankening WF editor Musculoskeletal Tumor surgery. New York: Churchill Livingstone. 1983;69-88.
3. Bessiony A, Abdel Rehman M, Abdel Hady A. Resection arthrodesis for management of aggressive Giant Cell Tumor of Distal Femur. *Indian J Ortho* 2009;43(1): 67-71
4. Blackley HR, Wunder JS, Davis AM, treatment of Giant Cell Tumor of long bone with curettage and bone grafting. *JBJS AM* 1999;81(6):811-820.
5. Capanna R, Fabbri N, Bettli G. Curettage of GCT. Effect of adjuvants on local recurrence. *Chir Organi Mov* 1990;75(1):206.
6. O'donnell R J, Spring field DS, Motwani HK. Recurrence of Giant cell tumors after curettage and packing with cement. *JBJS AM* 1994;76(12):1827-1833.
7. Goldenberg RR, Campbell CJ. Giant cell tumor, an analysis of 218 cases. *JBJS Am* 1970;52(4)619-624.
8. Mastu F, Ushigome S, FujiK. Giant cell tumors clinicopathological study of prognostic factors. *Pathol Int* 1998 48(9),723-734.

9. Enneking WF, Dunham W, Gebhardt MC. A system for the functional evaluation of reconstructive procedures after surgical treatment of tumors. *CORR* 1993;286:241-246
10. Von Steyresen Fv, Kristinnason I, Jonsson K. GCT of knee, the condition of cartilage after treatment by curettage and cementing. *JBJS Br* 2007;89(3):361-365.
11. Ward WG SR, Dory F, Kelly C. Lesson from massive tumor endo prosthesis. *Seminars in Arthroplasty* 1999;10(3):124-132.
12. Balke M Streit, Buerger A, Budny T. Treatment and outcome of GCT of Pelvis. *Acta Orthopaedia* 2009;80(5):590-596
13. Green JR. Antitumor effect of bisphosphonate. *Cancer* 2003;97(3):840-847.
14. Rogers MJ, Gordon S, Coxon FP. Cellular and Molecular mechanism of action of bisphosphonates. *Cancer* 2000; 88(12): 2961-2978
15. Thin-Hsiung Chen, Yu-Ping Su, Ming Chen. GCT of the knee, Subchondral Bone integrity affects the outcome *Int Orthop (SICOT)* 2005;29:30-34.
16. Arbeits Gemeinschaft Konchentumoren, Becker WT, Dohle J, Braun A. Local recurrence of GCT after intra lesional treatment with or without adjuvant therapy. *JBJS Am* 2008;90(5):160-167.

**How to cite this article:** Sharma J, Upadhyaya P. A modified sandwich technique in osteolytic lesions around knee. A prospective study for functional and radiological outcome. *Indian J Orthop Surg* 2019;5(1):95-98.