

Effect of encercage wiring with intermedullary nailing in subtrochanteric fractures of femur

Ravindra Patil¹, Sowen Modi^{2*}, Sreeharsha Rajoli³, Ratish Kumar⁴, Gunjan Ghelani⁵

¹Assistant Professor, ²⁻⁵Junior Resident, Dept. of Orthopaedics, D.Y. Patil Medical College and Hospital, Kolhapur, Maharashtra, India

***Corresponding Author: Sowen Modi**

Email: doc.sowen@gmail.com

Abstract

Introduction: Subtrochanteric typically defined as area from lesser trochanter to 5cm distal. Treating a subtrochanteric fractures is associated with difficulties due to anatomical and biomechanical factors comprising mainly due to poor reduction, varus deformity, non union, poor bone quality, comorbidities. Encercage wire helps in reduction but its use remains controversial due to disturbance of blood supply to the underlying bone and soft tissue damage. This study was undertaken to study the use of encercage wire for fracture reduction and associated complications.

Materials and Methods: Retrospective analysis of patients of age group 20 years and above having subtrochanteric femur fracture, admitted and treated with Long PFN between June 2016 and Sept 2018 were considered in this study. After exclusion 34 patients with an average follow up of 16.8 months were included in this study. Indications for encercage were fracture patterns like long oblique, spiral, spiral wedge or comminuted fracture with butterfly fragment. Cerclage wire was employed in 15 patients and wire passed through cerclage wire passer. Assessment was done in terms of operation time, quality of reduction, neck shaft angle, union time, complications and final functional outcome by Harris Hip Score.

Result: Average operation time and blood loss was significantly higher in cerclage group as compared to without encercage ($p = 0.042$), anatomical reduction was achieved by in 93% in encercage group as compared to 79% in non encercage group. Postoperative Neck shaft angle was 132.8° versus 132.1°. Mean Union rate was 14.3 weeks versus 15.6 weeks. 3 patient in non encercage developed non-union of which 2 patients had nail breakage superficial wound infection was seen in 1 patient in encercage group and was resolved with regular dressing. Mean range of hip flexion was 123.6° and extension was 14.8°.

Conclusion: Encercage wire gives a better outcome for fracture reduction, decreases varus deformity, and overall there are no major complications. It is although associated with increased operation time and blood loss.

Keywords: Subtrochanteric fractures, femur, Proximal femoral nail, Encercage.

Introduction

Subtrochanteric typically defined as area from lesser trochanter to 5cm distal fractures with an associated intertrochanteric component may be called

1. Intertrochanteric fracture with subtrochanteric extension
2. Peritrochanteric fracture

The subtrochanteric region is an area of high stress concentration that is subject to multiple deforming forces, making anatomic reduction of a fracture difficult. The greater trochanter is the site of insertion of the powerful hip abductors (gluteus medius and minimus) and short external rotators of the hip. The lesser trochanter is a posteromedial bony eminence at the inferior aspect of the intertrochanteric ridge that provides attachment to the iliacus and psoas hip flexors. These muscles act on the proximal fragment of a subtrochanteric femur fracture, resulting in a flexed, abducted, and externally rotated position. The distal fragment is shortened and adducted by the hamstrings and hip adductors, resulting in an overall varus and anterior apex deformity at the fracture site.⁶

The classic clinical presentation of a hip fracture is an elderly patient who sustained a low-energy fall and now has groin pain and is unable to bear weight.¹ Pain may be referred to the supracondylar knee. On examination, the affected extremity is often shortened and unnaturally, externally rotated compared to the unaffected leg.²

Causes

Subtrochanteric fractures are generally associated with high velocity trauma in young patients mostly caused by road traffic accidents. Associated in elderly with fall or many a times a fall due to pathological fracture. The most common causes of weakness in bone are Osteoporosis, increased Homocystein levels, a toxic 'natural' amino acid linked to the cause of heart disease, Other metabolic bone diseases such as Paget's disease, osteomalacia, osteopetrosis and osteogenesis imperfecta. Stress fractures may occur in the hip region with metabolic bone disease, Benign or malignant primary bone tumors are rare causes of hip fractures, Metastatic cancer deposits in the proximal femur, Infection in the bone is a rare cause of hip fracture, Smoking (associated with osteoporosis).

1. The goals of therapy for subtrochanteric fractures include the following:
2. Anatomic alignment
3. Early mobilization
4. Effective rehabilitation

Today, treatment of these fractures in adults is almost exclusively surgical. With the improvements in surgical techniques and implants, most of the treatment goals can typically be achieved by surgical means.

Materials and Methods

In this study, all cases of subtrochanteric fractures, admitted & treated with intermedullary nailing (Long

Proximal femoral nail).²² All patients with mature skeleton <20 years having subtrochanteric fracture were included in this study. All patients with open fractures with multiple trauma, pathological fractures, use of bisphosphonates, previous fracture of same hip were excluded from the study. Patients operated with subtrochanteric fracture operated with other implants other than IM nail were also excluded from our study. After exclusion 34 patients of subtrochanteric fracture treated with IM nailing were analysed for our study. Of these 15 patients were treated with cerclage wire along with PFN while remaining were treated with PFN only.

Soon after the admission, clinical data of all patients was recorded. The diagnosis was based on clinical examination and supported by radiological (X-ray) examination. In all the cases, primarily routine investigation were carried out. Then X-ray examination of the pelvis with both hips in AP and lateral view of affected hip were carried out. On admission, primary line of management, investigations and skin traction was applied till the day of surgery. Subtrochanteric fracture were classified on the basis of Seinsheimer's 5 type classification. Of these 5 were type I & IIa (undisplaced fracture with <2 mm displacement or simple transverse fracture), 12 were type IIc (2 Part spiral fracture with Lesser trochanter attached to distal fragment), 4 type IIIa (3 Part spiral fracture in which lesser trochanter is part of third fragment, which has an inferior spike of varying length), 9 were type IIIb b (3 Part spiral fracture in which third part is a butterfly fragment), 4 were type IV (Comminuted fractures with four or more fragments).

Surgical Procedure

All patient were operated under spinal anaesthesia with patient in supine position on fracture table. All patients were treated with Proximal Femoral nailing. Before scrubbing and drapping fracture was reduced with adduction manipulation under the image intensifier and confirmed with AP and Lat images. All fractures which were satisfactory reduced were treated with IM nailing, while in patients where satisfactory reduction could not be achieved were treated with mini open clamp assisted reduction with/without encerclage with 1 or 2 wires around the fragment. Incision was taken 5cm proximal to the greater trochanter and sharp dissection done. Entry taken through the piriformis fossa with the help of guide wire after which manual reamer passed to increase the size of entry point and followed by reaming of the medullary canal. Nail passed with help of zig and fixed with 2 proximal cc screws and distally locked with 1 or 2 cortical screw. After completion of procedure thorough wash given to wound and closed in layers.

Post Operative Protocol

Patients were mobilized from post operative day one with static quadriceps strengthening exercises and range of motion exercises. Depending on the fixation were started with toe touch weight bearing or non-weight bearing for 6 weeks followed by assisted walking with walker for further 4-6 weeks. Full weight bearing was begun after clinical and radiological signs of union.

Follow up and Outcome

Patients were regularly followed up after every 4 weeks interval in outpatient department till time of fracture union and later after every 12 weeks for final evaluation. Outcome was measured on basis of deep infection, non-union, displacement of lateral wall, duration of surgery and blood loss and change in femoral neck angle or neck shaft angle. Deep infection was defined as return to theatre for debridement of the infection. Radiological union was defined as bridging callus of atleast 3 of 4 cortices on AP and Lat radiographs along with obliteration of fracture line. Those who could not follow up answered the questionnaire on phone. Reduction was judged based on maximum cortical displacement and angulation on AP and lateral radiographs. They were graded on basis of maximum cortical displacement and varus angulation. Difference in neck shaft angle was measured on weight bearing pelvic radiograph at any point in time and compared with normal hip. Grading was excellent if maximum cortical displacement was ≤ 5 mm and angulation $\leq 10^\circ$, acceptable if either of the cortical displacement was ≤ 5 mm or angulation $\leq 10^\circ$, and poor if cortical displacement was ≥ 5 mm and angulation $\geq 10^\circ$. Lateral femoral displacement was measure on 1st postoperative AP radiograph. At final follow up limb length discrepancy was adjudged by comparing with the normal limb and evaluated for limb shortening, mobility status, screw positioning, implant failure or any other implant related complications (screw cut out, breakage or z effect) or need for resurgery.

Functional ability of patients with respect to ambulatory status, ability to squat, sit cross legged and walk for varying distance was assessed on basis of Harris Hip Score.

Total Harris Hip Score

Excellent	60-100
Good	15-59
Poor	<14

Results

In our study maximum aged patient was 75 years with mean average age of 52.6 years. There was a slightly higher proportion of patients with high energy trauma requiring encrclage but values did not reach significance. After exclusion there were 20 male patients and remaining were females suggesting no significant preponderance of any gender. Complete clinical and radiologic follow-up for an average of 15.8 months (range 13 to 22 months) were available of 34 patients; 19 of whom were operated without the use of cerclage wire, and the rest 15 patients with one or two cerclage wire depending on the fracture configuration. Patients were operated on average within 5 days after patients were hospitalized. The mean duration for surgery was significantly longer in cerclage group as compared to group without encrclage (96.74 ± 24.53 min vs 62.95 ± 16.35 min; $p < 0.001$). Similarly it was observed that patients treated with encrclage prior to nailing had significantly larger blood loss

as compared to patient without encerclage (median blood loss 180 ml vs 120 ml; p 0.004).

Application of cerclage wire significantly affected the quality of reduction achieved in terms of neck shaft angle with less varus deformity (p value 0.003 and 0.045 respectively). 14 patients (93.33%) were adjudged to have achieved post-operative good reduction, and 1 patient (6.67%) had acceptable reduction in cerclage group (Fig. 2 and 3). Whereas, 15 patients (78.94%) had good reduction, 2(10.52%) acceptable reduction, and rest 2 patients (10.52%) had demonstrated poor reduction without encerclage. It was found that mean union time was shorter in encerclage group (15.41 ± 3.36 weeks vs 16.55 ± 2.13 weeks), however it was not statistically significant. Mean baseline neck-shaft angle of the uninjured hip was $132^\circ \pm 2.3^\circ$ across all patients; post-operative neck-shaft angle of the operated hip was $130.1^\circ \pm 2.2^\circ$ in encerclage group and $127.7^\circ \pm 2.5^\circ$, in non-cerclage. Comparison of differences between uninjured and operated hip neck-shaft angle was found to be favourable in cerclage group (p 0.011). Varus reduction ($>5^\circ$) was observed in (22.22%) patients in non-cerclage group, 2 of them had uneventful union; whereas, 1 patient operated with cerclage wire showed varus reduction, but patient did not have any post op complications and showed good union.

3 patients developed non-union in non-cerclage group (13.33%) and had presented with nail breakage during the course of their follow up while 1 patient had uneventful

delayed union. No significant fracture redisplacement or implant related complications were seen in cerclage group. 2 patients presented with shortening of < 2 cm in the non encerclage group, but these patients had severe comminution. Only 1 patient developed superficial infection in encerclage group and was it healed with regular dressing. No complications were also noticed during passage of wire. On a whole all patients had a satisfactory range of movements postoperatively. At final follow-up, average Harris Hip Score was 89.25 and 88.12 in non-cerclage and cerclage group respectively suggestive of excellent result and range of movements in majority of patients. Most of the patients treated were able to ambulate to their pre injury levels at the time of their final follow up except patients of geriatric < 65 years age group who continued to use crutches or cane for walking.

Baseline demographic characteristics of study patients.

Table 1

Variables	Non-cerclage	Cerclage
Age (mean \pm SD) in years	53.5 \pm 19.3	48.9 \pm 19.7
Sex (%)		
Male	12(63.15%)	9(60%)
Female	7(36.84)	6(40%)

Table 2: Summarized depiction of perioperative data and results

Parameters	Non-cerclage group	Cerclage group	p value
OT time(SD, min)	78.8	96.8	0.001
Blood loss (range,ml)	120	180	0.004
Maximum cortical displacement (range, mm)	4.2 (0e8)	1.3 (0e5)	0.003
Angulation(range, $^\circ$)	5 (0e12)	1 (0e10)	0.045
Reduction (%)			
Good	15 (78.94)	14 (93.33)	0.11
Acceptable	2 (10.52)	1 (6.67)	
Poor	2 (10.52)		
Neck-shaft angle			
Neck-shaft angle of operated hip (SD, $^\circ$)	127.7 \pm 2.5(3.68)	130.1 \pm 2.2(2.39)	
Varus reduction ($>5^\circ$, %)	4 (21.05)	1 (6.67)	0.11
LLD (<2 cm, %)	2 (10.52)	0	
Union time (SD, week)	15.6 (2.13)	14.5(3.29)	0.208
Reoperation	3 Patients had broken nail and screw backout and were treated with implant removal and bipolar prosthesis		
Mean Harris Hip Score	88.12(3.13)	89.25 (1.01)	0.02

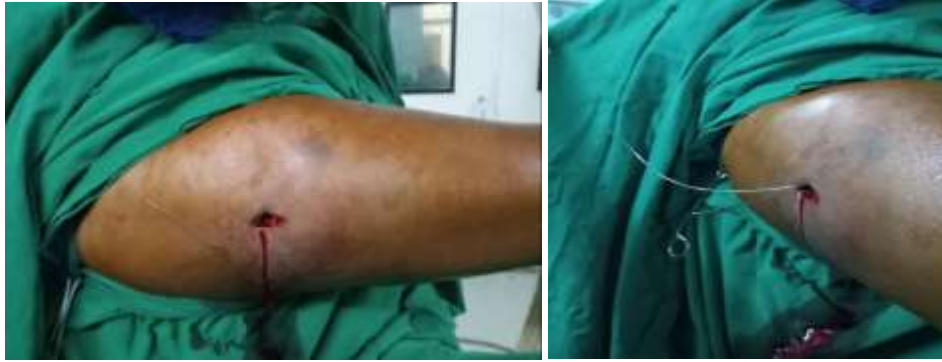

Fig. 1

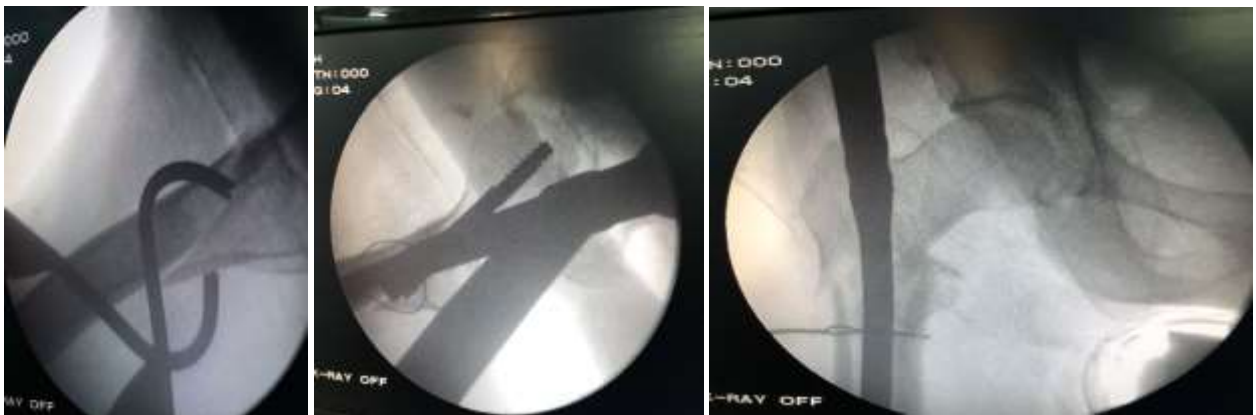

Fig. 2

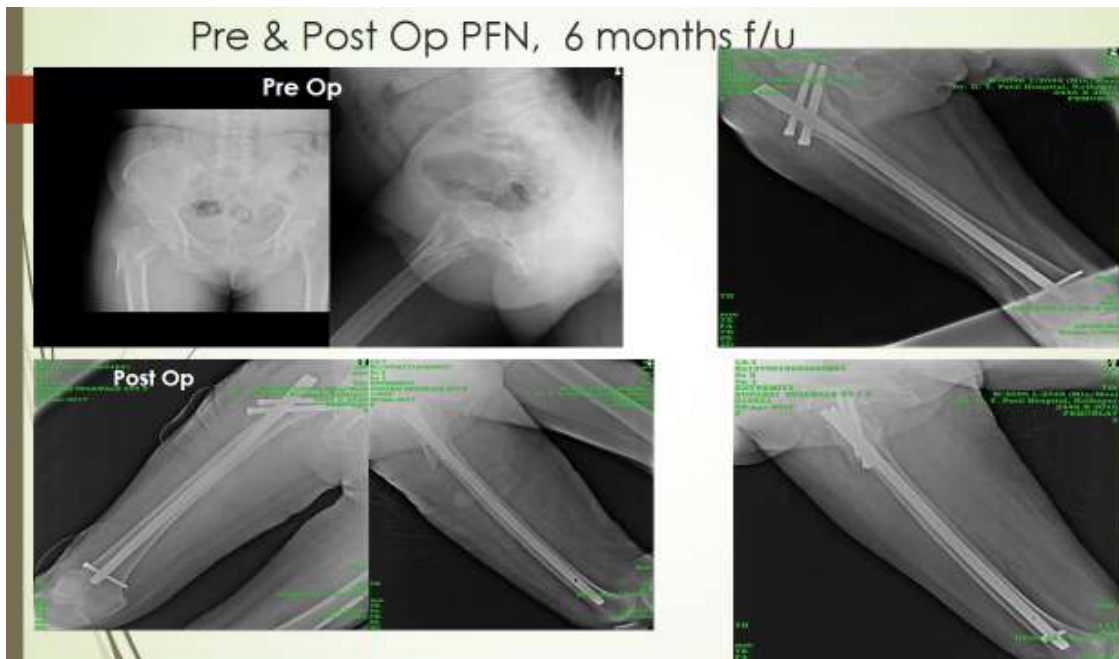


Fig. 3:



Fig. 4:

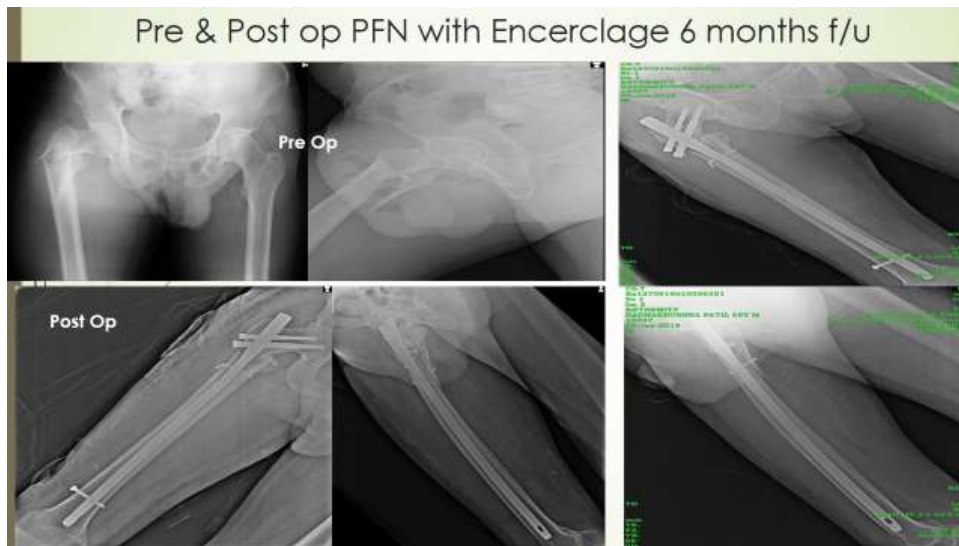


Fig. 5

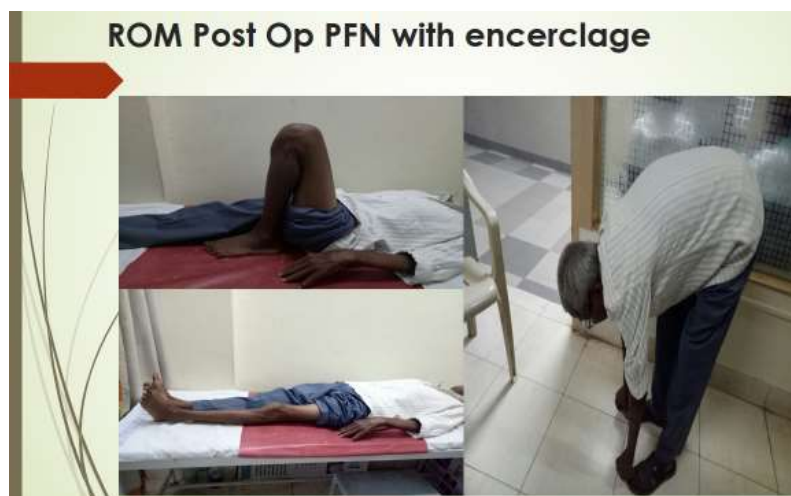

Fig. 6

Discussion

The characteristic anatomy, biomechanical stress and forces acting at subtrochanteric region makes it difficult to manage. Young patients usually sustain high energy trauma which results in comminuted fracture and in older population fractures are seen after history of trivial fall.⁴ According to study by Lei-Sheng Jiang, et al of subtrochanteric fracture it was concluded that long PFN is a reliable implant for subtrochanteric fractures, leading to high rate of bone union and minimal soft tissue damage.¹⁶ But it was noted that for all subtrochanteric fractures only closed reduction and nailing was not enough to achieve a good stable reduction and maintain bone to bone contact and medial continuity which led to complications like implant failure, non union or varus collapse.

Shukla et al³ in their study identified malreduction (varus alignment) to be the most important factor in non-union. All non-unions occurred in the study occurred in the 'closed reduction group', furthermore the hospital stay for patients with a malreduction was longer than for patients with a neutral postoperative alignment. To improve the overall outcome and to strengthen the construct there is renewed interest in encercage wiring difficult subtrochanteric fractures outcome. Shukla et al have noted that apart from its excellent ability to anatomically reduce the fracture, it increases the overall construct stability and strength, and therefore, increases the load sharing capacity of the construct, and minimizes fixation failure.^{8,9} Fracture reduction before starting nailing procedure helps substantially to accurately localize the starting point of nail, which is of paramount importance.^{10,11} Müller et al⁵ in their biomechanical studies observed noted that additional wire cerclage significantly reduced osteosynthesis failure (100 vs 10%) after IM nailing of subtrochanteric fractures. The beneficial effect is attributed to the preservation and maintenance of biomechanically important medial cortical buttress by cerclage in complex fractures, which facilitate fracture healing. The benefits of wire cerclage; anatomic reduction was achieved in 93.33% of cases as opposed to 78.94% without cerclage use in our study which is comparable to the other studies which are suggestive of increased stability of subtrochanteric fractures. In our study additional encercage wire application significantly improved the maximum cortical displacement and neck shaft angle compared to non encercage group ($p < 0.05$) which is comparable to study by Vivek Trikha et al.¹⁷ After fracture union range of movements was measured in all patients. Average Range of flexion of hip across all patients was 126.4°. Mean range of knee flexion was 118.2°. Mean range of hip extension was and knee extension were equal to the normal side. Mean range of abduction was 28.5°, and adduction was 25.6°. Internal rotation was 28.9° and external rotation was 34.9°. This results were similar to study by Yadkikar SV et al¹⁸ and Hotz et al.¹⁹

The current general idea that placing cables or wires around the bone will cause ischemia arises from the communications of Sir John Charnley in 1950 who spoke of the evil effects of the circumferential suture.¹⁴ However, the blood supply to the bone is thought to be circumferential,

rather than longitudinal. Placing a cerclage wire has only minimal interference with this circumferential blood supply. As Perren et al. showed in cadaveric study, the ischaemic zone underneath a cerclage cable is only 0.36mm wide.¹² In support of this, recent experimental and cadaveric studies did not find any deleterious effect of cerclage on bone blood supply.²¹ Recent clinical studies also could not find any significant harmful effect on vascularity or healing of fracture.^{7,14} Furthermore, Apivatthakakul et al. showed with a cadaveric study on 18 femurs that percutaneous cerclage wiring resulted in only minimal disruption of the femoral blood supply, and that rupture of one or more perforators was compensated by their anastomoses.¹³ Hoskins et al. in their study of all subtrochanteric fractures observed that no cases with encercage wire had return to theatre for revision surgery⁷ which is similar to our study. Our results are also comparable to study by Kennedy et al. were subtrochanteric fractures were treated with an intramedullary nail and encercage and all patients had good functional outcome. Ban et al. in study of subtrochanteric fractures, all patients treated with encercage as augmentation of the intramedullary nail the application of circumferential wires is an option as it provides good primary reduction with no apparent increase in reoperation rate.^{8,15} The numerous clinical studies are also supported by a biomechanical study by Müller et al. who showed that cerclage wire application may substantially reduce the risk of osteosynthesis failure in complex fractures.⁵

Encercage wires with all the advantages related to fracture reduction and stability construct have their share of drawbacks. There was significant increase in operation time and blood loss in the encercage group as compared to non encercage group. Although postulated that higher operation time and blood loss could lead to higher chances of infection but in our study there was only 1 instance of superficial wound infection which was not significant and was healed by antibiotics which is similar to findings of Mingo-Robinet et al²⁰ in his study. Our results are also in close agreement to those previously reported. Union time was comparatively shorter in cerclage group but was not statistically significant. Only 1 patient had delayed union which was a case of comminuted subtrochanteric fracture operated with cerclage use, which later healed uneventfully without patient requiring revision surgery, whereas 3 (15.78%) patients in non-cerclage group developed non-union. We had used cerclage passer (DepuySynthes®) for all patients without directly visualizing the fracture and additional soft-tissue or periosteal stripping, and employed one or maximum two cerclage wire depending on fracture geometry.

The most important limitations to our study is the collection of retrospective data evaluation is based on retrospective database analysis, sample size was small, follow up is not controlled, loss of follow up for some patients and underreporting of complications. We have tried for the best achievable reduction and had kept a low threshold for minimally invasive percutaneous clamp assisted reduction and encercage wire application whenever needed. The other drawback of encercage wire is the long learning

curve required to master this technique. But with practice surgical time and blood loss can be reduced.

Conclusion

In our study we compared patients that were treated for a subtrochanteric fracture with or without additional cerclage wires and although there is slight difference in union rate with early union in encerclage it was statistically not significant, nor an increase in infection rate when cerclage was used. Although these results should be interpreted with caution, they are in line with conclusions of numerous recent studies showing that the use of cerclage wires is not detrimental for fracture healing. We find that the potential benefit of an anatomical reduction outweighs the minor complications associated with an open reduction and advocate the use of open reduction with cerclage wire when closed reduction is not satisfactory. Cerclage is not suitable for all subtrochanteric fractures; fractures with long oblique, spiral geometry, and spiral wedge or comminuted fracture with butterfly fragments can benefit substantially from additional cerclage application.

Conflict of Interest: None.

References

- Essentials of musculoskeletal care. Sarwark, John F. Rosemont, Ill.: American Academy of Orthopaedic Surgeons. 2010. ISBN 9780892035793. OCLC 706805938.
- Papadakis, Maxine A., McPhee, Stephen J., Rabow, Michael W. Current medical diagnosis & treatment 2018. (Fifty-seventh edition ed.). New York. ISBN 9781259861482. OCLC 959649794.
- Shukla S, Johnston P, Ahmad MA. Outcome of traumatic subtrochanteric femoral fractures fixed using cephalomedullary nails. *Inj* 2007;38:1286e1293.
- Rockwood and Green "Fracture in adults, 4th edition, 1998, Vol. 2, Chapter 26. Lippincott Raven Publishers.
- Müller T, Topp T, Kühne CA, Gebhart G, Ruchholtz S, Zettl R. The benefit of wire cerclage stabilisation of the medial hinge in intramedullary nailing for the treatment of subtrochanteric femoral fractures: A biomechanical study. *Int Orthop* 2011;35(8):1237–1243.
- Bedi A, Le Toan T. Subtrochanteric femur fractures. *Orthop Clin North Am* 2004;35:473–483. doi:10.1016/j.ocl.2004.05.006.
- Hoskins W, Bingham R, Joseph S, Liew D, Love D, Bucknill A, et al. Subtrochanteric fracture: The effect of cerclage wire on fracture reduction and outcome. *Inj* Elsevier Ltd; 2015;46(10):1992–1995. Available from <http://dx.doi.org/10.1016/j.injury.2015.07.001>
- Ban I, Birkelund L, Palm H. Circumferential wires as a supplement to intramedullary nailing in unstable trochanteric hip fractures: 4 reoperations in 60 patients followed for 1 year. *Acta Orthop* 2012;83:240e243.
- Finsen V. The effect of cerclage wires on the strength of diaphyseal bone. *Inj* 1995;26:159e161.
- Toma's J, Teixidor J, Batalla L. Subtrochanteric fractures: treatment with cerclage wire and long intramedullary nail. *J Orthop Trauma* 2013;27:e157ee160.
- Kim JW, Park KC, Oh JK. Percutaneous cerclage wiring followed by intramedullary nailing for subtrochanteric femoral fractures: a technical note with clinical results. *Arch Orthop Trauma Surg* 2014;134:1227e1235.
- Perren SM, Fernandez Dell a. Cerclage, evolution and potential of a Cinderella technology. An overview with reference to periprosthetic fractures. *Acta Chir OrthopTraumatol Cech* 2011;78(3):190–199.
- Apivatthakakul T, Phaliphot J, Leuvitooonvechkit S. Percutaneous cerclage wiring, does it disrupt femoral blood supply? A cadaveric injection study. *Injury* [Internet]. Elsevier Ltd; 2013;44(2):168–74. Available from <http://dx.doi.org/10.1016/j.injury.2012.10.016>
- Charnley J. The closed treatment of common fractures. Fourth ed. Cambridge university press; 2009. 272 p.
- Afsari A, Liporace F, Lindvall E, Infante A, Sagi HC, Haidukewych GJ. Clampassisted reduction of high subtrochanteric fractures of the femur. *J Bone Joint Surg Am* 2009;91(8):1913–1918. Available from: <http://www.ncbi.nlm.nih.gov/pubmed/19651949>.
- Lei-Sheng Jiang. Intramedullary Fixation of Subtrochanteric Fractures with Long Proximal Femoral Nail or Long Gamma Nail: Technical Notes and Preliminary Results. *Ann Acad Med Singapore* 2007;36:821-826.
- Vivek Trikha. Role of percutaneous cerclage wire in the management of subtrochanteric fractures treated with intramedullary nails. *Chin J Traumatol* 21(2018):42e49.
- Yadkikar SV, Yadkikar VS, Prasad DV, Marawar A. Prospective study of proximal femoral nail in management of trochanteric and subtrochanteric fractures of femur. *Int J Biomed Adv Res* 2015;6(04):349-354.
- Hotz TK, Zellwegwe R, Kach KP. Invasive treatment of proximal femur fractures with the long Gamma nail: indications, technique, results. *J Trauma* 1999;47(5):942-945.
- Mingo-Robinet J, Torres-Torres M, Moreno-Barrero M, et al. Minimally invasive clamp-assisted reduction and cephalomedullary nailing without cerclage cables for subtrochanteric femur fractures in the elderly: surgical technique and results. *Inj* 2015;46:1036e1041.
- Lenz M, Perren SM, Gueorguiev B. Underneath the cerclage: an ex vivo study on the cerclage-bone interface mechanics. *Arch Orthop Trauma Surg* 2012;132:1467e1472.
- Lunsjo K, Ceder L, Thorngren KG, Skytting B, Tidermark J, Burntson PO. Extramedullary fixation of 569 unstable intertrochanteric fractures. *Acta Orthop Scand* 2001;72:133-140.

How to cite this article: Patil R, Modi S, Rajoli S, Kumar R, Ghelani G. Effect of encerclage wiring with intermedullary nailing insubtrochanteric fractures of femur. *Indian J Orthop Surg* 2019;5(1):35-41.