

**International Journal  
of Ayurveda and  
Pharmaceutical  
Chemistry**



Volume 7 Issue 3 2017

[www.ijapc.com](http://www.ijapc.com)

**e ISSN 2350-0204**



Greentree Group



## An Ethno-medicinal Plant: Cutaneous Wound Healing Properties of Aqueous Extracts of *Stevia rebaudiana* Leaves in Rats

Amir Amiri-Paryan<sup>1</sup>, Milad Khazaei<sup>2</sup>, Mohammad Mahdi Zangeneh<sup>2\*</sup>, Masoud Shamohammadi<sup>2</sup>, Milad Alahmoradi<sup>2</sup>, Reza Tahvilian<sup>3</sup>, Akram Zangeneh<sup>1</sup>, Maryam Almasi<sup>1</sup>, Rohallah Moradi<sup>3,4</sup>

<sup>1</sup>Department of Microbiology section, Pathobiology & Basic Sciences, Faculty of Veterinary Medicine, Razi University, Kermanshah, Iran

<sup>2</sup>Department of Clinical Sciences, Faculty of Veterinary Medicine, Razi University, Kermanshah, Iran

<sup>3</sup>Research Pharmaceutical Center, School of Pharmacy, Kermanshah University of Medical Sciences, Kermanshah, Iran

<sup>4</sup>Department of Chemistry, Payame Noor University, Tehran, Iran

### ABSTRACT

Wounds are the result of injuries to the skin that interrupt the other soft tissues. Cutaneous wound healing is a complex and protracted process of tissue mending and remodelling in response to injury. Several plant products are in use for treatment of wounds over the years. *Stevia rebaudiana* is used in folk medicine as an antioxidant, anti-inflammatory, antipyretic, antibacterial, and anti-fungal agent. The recent study was conducted to investigate the healing properties of aqueous extracts of leaves of *S. rebaudiana* on cutaneous wounds in rats. A full thickness excisional wound (2×2 cm) was induced on the back of 32 rats. Rats were divided into four groups as follows; control (untreated), (treated) with 1ml basal cream, (treated) with 10%, 1ml *S. rebaudiana* aqueous extract, and 3%, 1ml tetracycline for 30 days. Animals of each group were euthanized at 30<sup>th</sup> day post-injury and wounds were assessed through gross and histopathological analyses. The data was analysed by one way variance analysis and Duncan's test using SPSS 21. Treatment with *S. rebaudiana* indicated a considerable reduction in the wound area during the experiment compared to other groups ( $p < 0.05$ ). Parameters such as arrangement of the healing tissue, re-epithelialization and epithelial formation demonstrated pivotal changes as compared to the control. In addition, treatment with *S. rebaudiana* decreased



**Greentree Group**

Received 03/10/17 Accepted 13/10/17 Published 10/11/17

total cells, neutrophils and lymphocytes numbers and increased the fibrocytes numbers and ratio fibrocytes/fibroblasts at 30 day ( $p<0.05$ ). The present study showed that *S. rebaudiana* leaves extract applied topically promotes healing of wounds more significantly as compared to other groups.

## KEYWORDS

*Stevia rebaudiana*; Aqueous extract; Wound Healing; Rat



**Greentree Group**

Received 03/10/17 Accepted 13/10/17 Published 10/11/17



## INTRODUCTION

Medicinal plants or simply herbs have been identified and used since prehistoric times<sup>1,2</sup>. Newly, medicinal plants as a source of useful chemical compounds received much attention in traditional medicine for inhibition, control and treatment of many diseases and elevation of human health<sup>3-5</sup>. One of extraction methods of compounds of medicinal plant is using of distilled water, which the produced extract is called aqueous extract<sup>6,7</sup>. Aqueous extracts can act as antioxidant and anti-inflammatory factors through preventing lipid proxidation, scavenging free radicals and chelating metal ions and treat several disease<sup>8-10</sup>.

Plants have immense potential for the management and remedy of wounds<sup>11</sup>. Cutaneous wounds Healing by medicinal plant depend on many factor including types of wound, factors affecting wound healing (infection at the wound site, improper diet, diabetes and other disease conditions), mechanism of wound healing and effects of some medicinal plants that indicated wound healing activity<sup>12</sup>. A list of medicinal plants that are consumed for their healing properties on cutaneous wounds include *Trigonella foenum-graecum*, *Sesamum indicum*, *Punica granatum*, *Pterocarpus santalinus*, *Prosopis Cineraria*, *Napoleona*

*Imperialis*, *Morinda citrifolia*, *Lycopodium serratum*, *Lawsonia alba*, *Ginkgo biloba*, *Euphorbia hirta*, *Clerodendrum serratum*, *Cecropia peltata*, *Catharanthus roseus* and *Alternanthera sessilis*<sup>13,14</sup>.

One of the most momentous herbal medicines, which is widely used in Iranian traditional medicine for control and treatment cutaneous wounds is *Stevia rebaudiana* from order Asterales, Asteraceae family, Eupatorieae tribe, *Stevia* genus<sup>15</sup>. *S. rebaudiana* is commonly cultivated for its sweet leaves, which are the source of steviol glycosides (mainly rebaudioside and stevioside). *S. rebaudiana* is 250–300 times the sweetness of sugar, so it is used in industry as a sweetener additive. *S. rebaudiana* is one of the eatable plants which have generated a lot of interest throughout human history as a medicinal plant<sup>16,17</sup>. In traditional medicine, different extracts of this plant are traditionally used in treating several inflammatory, gastric ulcer, diabetes, bacterial, parasitic, viral and fungal diseases<sup>18,19</sup>. As far as we know, there is a very little data about cutaneous wound healing properties of *S. rebaudiana* aqueous extract collected from Kermanshah province, in the west of Iran. Hence, the aim of the recent study was evaluation of effect



of the aqueous extract of *S. rebaudiana* on cutaneous wound healing in rats.

## MATERIALS AND METHODS

### *Plant sample collection*

In this study, medicinal plant was collected from Kermanshah in October 2016. The botanical identification of the plant was done by a certified botanist. Ethical committee approval number for conduction of clinical trial RU-RE-1396-86-IR.

### *Preparation of aqueous extract*

The plant material was first cleaned and then dried at 25 °C temperature without exposure to direct sunshine. Amount 150g of the powdered leaf was extracted with 1.5 liters of distilled water in a cold maceration process for 48 hours. The crude aqueous extract was concentrated using a rotary evaporator. Before the concentration process, the mixture was allowed to settle, it was elutriated and the supernatant was filtered initially with a white handkerchief and then with a filter paper. The evaporator was kept at a temperature of 40 °C. Amount 1ml of the extract was taken and dried to get the extracted value of 0.22mg.

### *Animal*

In first, thirty two male Sprague-Dawley rats weighing 200–220 g were applied. The animals were housed under at 25±3 °C

temperature and 12:12 h light-dark and feed with standard pellet diet and water *ad libitum* conditions (standard environmental and nutritional) during the study.

### *Wound creation*

In beginning of experiment, the animals were anaesthetized by intraperitoneal injection of 1mg/kg Xylazine HCl (Xylazine 2%; Alfasan) as premedication and 1 mg/kg Ketamine HCl (Ketamine 5%; TRITTAU, Germany) for anesthesia in 1:3 ratio, respectively. In the cervical region, a square shape full thickness incision of 2×2 cm was made in skin and the incised piece was removed. The wound was left undressed and no systemic or local anti-microbial factors were used.

### *Study design*

After wounding, the animals were randomly divided into four main groups (n=8) groups, representing 30 day after injury. The groups were numbered as follows:

- (1) Control: In the control group, no material was used in the injured area, which was left uncovered.
- (2) Basal cream: In the basal cream group, the injured area was covered with 1ml basal cream (eucerin) daily, for 30 days post-injury (DPI).
- (3) *S. rebaudiana* aqueous extract: In *S. rebaudiana* group the injured area was



covered with 1ml *S. rebaudiana* aqueous extract 10% (10 g *S. rebaudiana* aqueous extract were suspended in 90 g eucerin) for 30 DPI.

(4) Tetracycline: In the tetracycline group, the injured area was covered with 1ml basal cream and tetracycline (3%) daily for 30 days<sup>20</sup>.

#### *Sample collection*

At the end of 30 DPI, the animals were euthanized by intraperitoneal injection of 1mg/kg Xylazine HCl (Xylazine 2%; Alfasan) and Ketamine HCl (Ketamine 5%; TRITTAU, Germany) ratio of 1 to 3 respectively, and sampling was done. Full thickness skin samples from the wound site including epidermis, dermis and subcutaneous were carefully dissected and harvested for histopathological studies. The tissue samples were fixed in 10% neutral-buffered formalin, processed routinely, embedded in paraffin, sectioned at 5  $\mu$ m thickness, stained with Hematoxylin-Eosin and studied with a routine light microscope.

#### *Histological evaluation*

The pictures were taken by a digital camera (Dino capture; version 1.2.7) and transferred to the computer software (Photoshop CS-4; Adobe) for digital analysis. Twenty photomicrographs, equivalent to twenty microscopic fields from all tissue samples in

all groups, were applied for histopathologic analysis. The criteria that were studied in histopathological sections consisted of cornification of the epithelium, re-epithelialization, revascularizations, hemorrhage, fibrin deposition, mononuclear cell and polymorphonuclear cell infiltration, macrophage content, necrosis, presence of fibroblasts, fibrocytes, maturation and organization of collagen. The number of total cells and blood vessels (magnification  $\times 200$ ) and fibroblasts, fibrocytes, neutrophils, lymphocytes, and macrophages (magnification  $\times 800$ ) of the injured area were counted<sup>21</sup>.

#### *Statistical analysis*

All data are expressed as mean and standard deviation. Statistical comparison of the MEAN of all the groups were done through one-way ANOVA followed by Duncan's post-hoc test using SPSS 21.  $p < 0.05$  was considered as significant.

## **RESULTS AND DISCUSSION**

Wound healing is a hemostatic process to return physiological equilibrium which includes restoration of the damaged structures by complex interactions between reconstruction and inflammatory cells<sup>22</sup>. There are three main phases for healing of cutaneous wounds in the injured area; (1)



inflammatory phase, (2) proliferative phase, (3) remodeling phase. The aim of wound care includes decreasing risk factors that limit wound healing, enhancing the healing mechanism and extenuating the incidence of infections of wound<sup>22</sup>. The great costs of recent medicines demonstrate that alternative strategies are essential for better management of wounds and its related problems. The combination of new knowledge and traditional especially in the field of traditional medicinal plants can produce better natural drugs for cutaneous wound healing with fewer side effects<sup>23-25</sup>. Therefore, the use of natural ethno medicinal plant has been widely welcomed. *S. rebaudiana* as an Iranian traditional plant has been indicated to have some optimal treatment effects, due to its antioxidant activities in both in vitro and in vivo. It also reported protective activities against toxicity of most of body organs<sup>15</sup>. But, to our knowledge, this is the first time aqueous extract of *S. rebaudiana* has been used from on experimentally induced cutaneous wound defects in rats and, except its antioxidant and anti-inflammatory properties; there is no information about other beneficial potential of aqueous extract of *S. rebaudiana* on wound healing.

### **General observation**

At 30 DPI, the wounds presented the formation of a scar covering a thick granulation tissue in all rats; but, treatment with aqueous extract of *S. rebaudiana* produced more scar tissue than other groups. In all groups, although the epidermis was thick and disorganized, especially when compared with the adjacent normal skin, but its size was decreased and its alignment was ameliorate in the *S. rebaudiana* treated lesions compared to other groups ( $p < 0.05$ ; Table 1; Figure 1, 2). Also, the results of the new study indicated that topical application of *S. rebaudiana* was able to significantly increase the wound contraction and re-epithelization rate in rats at the short term (Table 1; Figure 1, 2). In wound healing, wound contracture is a process that may occur during wound healing when an over plus of wound contraction, a normal healing process, leads to physical deformity characterized by skin constriction and functional limitations<sup>26</sup>. Epithelialization is an indispensable and inseparable part of cutaneous wound healing used as a defining factor of a favored wound closure. The epithelialization process is defective in all types of wounds. A cutaneous wound cannot treat completely without re-epithelialization<sup>27</sup>. A great deal of research effort has been focused on understanding





these processes in both chronic and acute cutaneous wounds. One of the main results in this study was the notable discrepancy in wound contraction and re-epithelization rate between *S. rebaudiana* group and the other groups. The increased rate of wound contraction and decreasing in healing time in treated lesions with *S. rebaudiana* might be due to the antioxidant and anti-inflammatory potential of this plant together with its activity on maturation and organization of the granulation tissue (Table 1; Figure 1, 2).

There was no evidence of pus accumulation,

or polymorphonuclear cell infiltration, fibrin deposition or edema in the lesions of animals in all groups (Table 1; Figure 1, 2).

In this experiment, the granulation tissue formation was precipitated by applying aqueous extract of *S. rebaudiana*. This ability was especially distinct when these observations were compared with those of other groups (Table 1; Figure 1, 2). Also, the enhancing in dry granulation tissue weight in the treated animals offered higher protein content.

**Table 1** Mean  $\pm$  SD of wound surface area ( $\text{cm}^2$ ) in groups on 30 days.

Day	Control	Basal Cream	<i>S. rebaudiana</i> aqueous extract	Tetracycline
30	0.47 $\pm$ 0.03 <sup>a</sup>	0.36 $\pm$ 0.02 <sup>b</sup>	0.11 $\pm$ 0.03 <sup>d</sup>	0.18 $\pm$ 0.03 <sup>c</sup>

Values bearing different superscripts in a row differ significantly ( $p < 0.05$ )

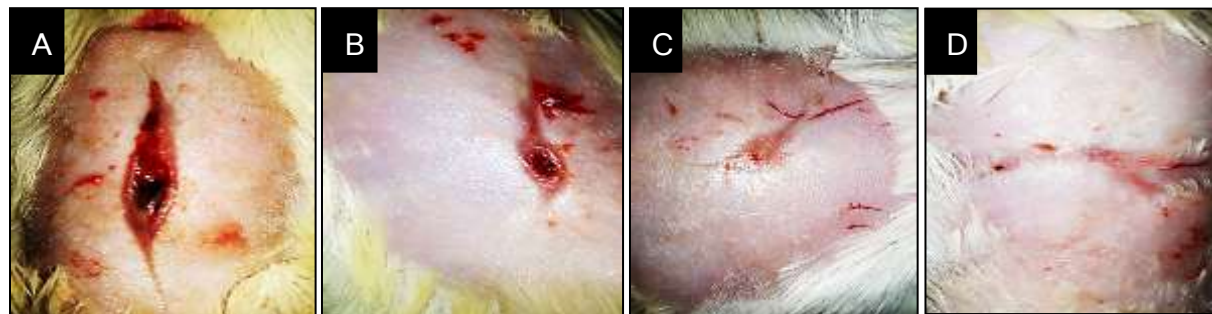

Figure 1 Macroscopic wound images. A: Control, B: Basal cream, C: *S. rebaudiana* aqueous extract and D: Tetracycline.

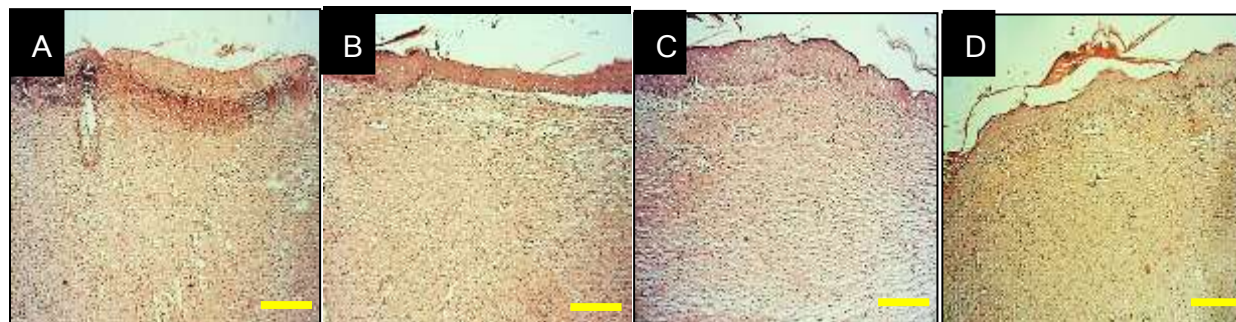


Figure 2: Longitudinal sections (scale bar for 60 $\mu\text{m}$ ) with Hematoxylin-Eosin staining. A: Control, B: Basal cream, C: *S. rebaudiana* aqueous extract and D: Tetracycline





### Quantitative analysis

Fibroblast and fibrocytes as main components of wound healing are the most usual cells of connective tissue in injured area. They (especially fibrocytes) with making collagen and reduced cellularity in wound area. Collagen is the most plentiful structural protein in body and is the component that retains the whole body together. In skin, collagen by decreasing cellularity accelerated wound healing in the injured region. Also, collagen plays a main role in hemostasis<sup>28, 29</sup>. In fact when

collagen is made accessible to the wound bed, closure can happen. In this study, aqueous extract of *S. rebaudiana* group, significantly enhanced the number of fibrocytes and ratio fibrocytes to fibroblasts compared with the other groups. ( $p < 0.05$ ; Tables 2, 3; Figure 3, 4). The collagen fibers indicated a more organized pattern and the tissue alignment was greater in the *S. rebaudiana* group when compared to the other groups (Figure 2-4).

**Table 2** Histopathologic and histomorphometric analysis of total cell and vascular blood number (magnification  $\times 200$ ).

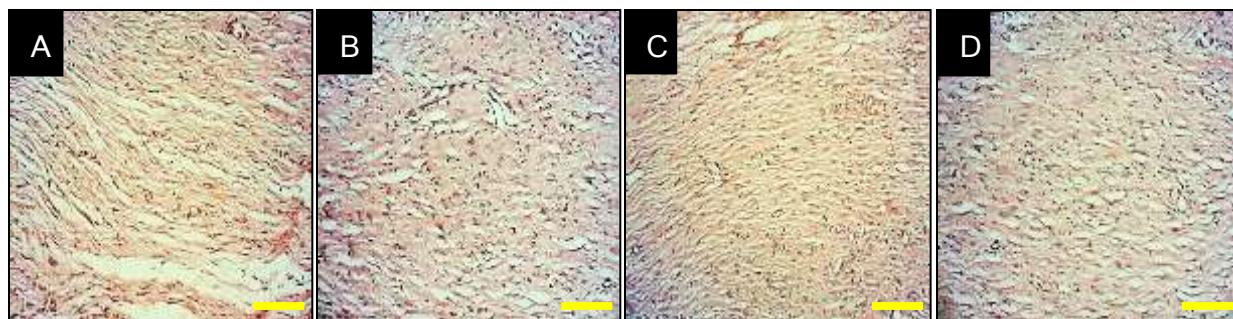
30 Day	Control	Basal Cream	<i>S. rebaudiana</i> aqueous extract	Tetracycline
<b>Total cell</b>	936.87 $\pm$ 15.25 <sup>a</sup>	877.75 $\pm$ 24.44 <sup>b</sup>	494.37 $\pm$ 17.99 <sup>d</sup>	564.37 $\pm$ 18.81 <sup>c</sup>
<b>Vascular no.</b>	5.62 $\pm$ 0.51 <sup>b</sup>	9.5 $\pm$ 0.75 <sup>a</sup>	5.12 $\pm$ 0.35 <sup>b</sup>	5.75 $\pm$ 0.46 <sup>b</sup>

Values bearing different superscripts in a row differ significantly ( $p < 0.05$ ).

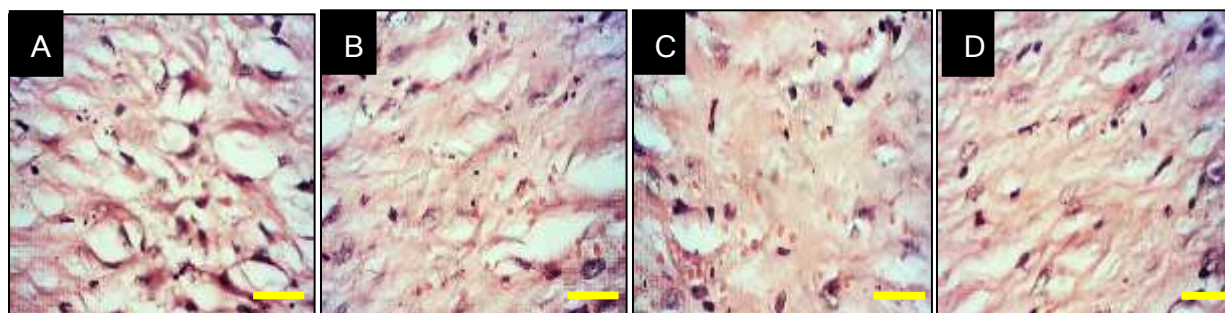
**Table 3** Histopathologic and histomorphometric analysis of fibrocytes and fibroblasts (magnification  $\times 800$ )

Day 30	Control	Basal Cream	<i>S. rebaudiana</i> aqueous extract	Tetracycline
<b>Fibrocytes</b>	5.87 $\pm$ 0.64 <sup>c</sup>	5.5 $\pm$ 0.53 <sup>c</sup>	12.12 $\pm$ 1.24 <sup>a</sup>	7.37 $\pm$ 0.51 <sup>b</sup>
<b>Fibroblasts</b>	30.75 $\pm$ 2.25 <sup>b</sup>	43 $\pm$ 1.3 <sup>a</sup>	14.87 $\pm$ 1.55 <sup>c</sup>	11.75 $\pm$ 0.7 <sup>d</sup>
<b>Ratio Fibrocytes to Fibroblasts</b>	.018 $\pm$ .002 <sup>c</sup>	.012 $\pm$ .001 <sup>c</sup>	.082 $\pm$ .013 <sup>a</sup>	.062 $\pm$ .005 <sup>b</sup>

Values bearing different superscripts in a row differ significantly ( $p < 0.05$ ).



**Figure 3** Longitudinal sections (scale bar for 150  $\mu\text{m}$ ) with Hematoxylin-Eosin staining. A: Control, B: Basal cream, C: *S. rebaudiana* aqueous extract and D: Tetracycline.



**Figure 4** Longitudinal sections (scale bar for 600 $\mu\text{m}$ ) with Hematoxylin-Eosin staining. A: Control, B: Basal cream, C: *S. rebaudiana* aqueous extract and D: Tetracycline.

Infection of the wound is most likely reason for impaired healing of cutaneous wounds. Once skin is injured, micro-organisms that are usually sequestered at the skin surface obtain access to the underlying tissues. The state of infection and replication status of the micro-organisms determine whether the wound is classified as having contamination, colonization, local infection/critical colonization, and/or spreading invasive infection. *Pseudomonas aeruginosa*, *Escherichia coli*, *Streptococcus pyogenes*, *Staphylococcus aureus* and

*Corynebacterium sp.*, are some main bacteria causing wound infection<sup>30</sup>. In this study, the lower levels of inflammation in *S. rebaudiana* group can be due to the attendance of some phytoconstituents in this plant species which inhibited the activities of inflammatory cells and production of chemical mediators and consequently reduced inflammation and subsequently enhanced the organization. *S. rebaudiana* decreased the number of neutrophils and lymphocytes in comparison of other groups ( $p < 0.05$ ; Tables 4; Figure 3, 4).

**Table 4** Histopathologic and histomorphometric analysis of inflammatory cells (magnification  $\times 800$ ).

Day 30	Control	Basal Cream	<i>S. rebaudiana</i> aqueous extract	Tetracycline
Neutrophils	4.12 $\pm$ 0.35 <sup>a</sup>	3.25 $\pm$ 0.46 <sup>b</sup>	1.75 $\pm$ 0.46 <sup>d</sup>	2.62 $\pm$ 0.51 <sup>c</sup>
Lymphocytes	2.37 $\pm$ 0.51 <sup>a</sup>	1.75 $\pm$ 0.46 <sup>ab</sup>	0.25 $\pm$ 0.46 <sup>c</sup>	1.25 $\pm$ 0.46 <sup>b</sup>
Macrophages	1.62 $\pm$ 0.51 <sup>a</sup>	0.5 $\pm$ 0.53 <sup>b</sup>	0 <sup>b</sup>	0.37 $\pm$ 0.51 <sup>b</sup>

Values bearing different superscripts in a row differ significantly ( $p < 0.05$ ).

## CONCLUSION

Based on the results obtained, aqueous extract of *S. rebaudiana* 10% ameliorated re-epithelization rate, fibrocytic response, collagen content and decrease total cell numbers, and wound size significantly, so it is normal that *S. rebaudiana* decrease cutaneous wound area, neutrophils and lymphocytes numbers and increased the number of fibrocytes and ratio fibrocytes to fibroblasts during the experiment compared to other groups ( $p < 0.05$ ). Thus the results of this study indicate, for the first time, the healing activity of aqueous extract of *S. rebaudiana* in the therapy of skin wounds. Therefore there is a need for further studies into the stability of the extract to ensure an efficacious formulation of products for cutaneous wound healing.

## Declaration of interest

The authors declare that they have no conflict of interest. The authors alone are responsible for the content of the paper.



## REFERENCES

1. Faramarzi E., Zangeneh M.M., Zangeneh A., Moradi R. Effect of Cinnamomum zelanicum oil on hyponeophagia anxiety test in Balb C male mice. *Onl J Vet Res.* 2017; 21(2): 77-80.
2. Foroughi A., Pournaghi P., Najafi F., Zangeneh A., Zangeneh M.M., Moradi R. Medicinal Plants: Antibacterial Effects and Chemical Composition of Essential Oil of *Foeniculum vulgare*. *IJCPR.* 2017; 8(1): 13-17.
3. Foroughi A., Pournaghi P., Najafi F., Zangeneh A., Zangeneh M.M., Moradi R. Antibacterial effect and phytochemical screening of essential oil of *Pimpinella anisum* against *Escherichia coli O157:H7* and *Staphylococcus aureus*. *IJCMPR.* 2016; 7(6): 367-371.
4. Tahvilian R., Moradi R., Zhale H., Zangeneh M.M., Zangeneh A., Yazdani H., Hajialiani M. Ethnomedicinal Plants: In vitro antibacterial effect of essential oil of *Pistacia khinjuk*. *Inter J Sci Eng Res.* 2016; 7(10): 437-447.
5. Najafi F., Tahvilian R., Zangeneh M.M., Zangeneh A., Moradi R. Screening of essential oil of *Allium sativum* for antibacterial effects against *Bacillus subtilis*. *Inter J Rec Sci Res.* 2016; 7(11): 14172-14176.
6. Foroughi A., Zangeneh M.M., Kazemi N., Zangeneh A. An in vitro study on antimicrobial properties of *Allium noeanumreut ex regel*: An ethnomedicinal plant. *Iranian J Publ Health.* 2016; 45(2): 32.
7. Pooyanmehr M., Zangeneh M.M., Zangeneh A., Almasi M. Effect of *Verbascum thapsus* aqueous extract on *Escherichia coli O157:H7*. *Onl J Vet Res.* 2017; 21(9): 580-583.
8. Zangeneh M.M., Tahvilian R., Najafi F., Zangeneh A., Souri N., Moeini-Arya M., Zhaleh S. Evaluation of the in vitro antibacterial effect of the hydroalcoholic extract of *Scrophularia striata*. *Int J Sci Eng Res.* 2016; 7(10): 1693-1702.
9. Moradi R., Hajialiani M., Zangeneh M.M., Zangeneh A., Tahvilian R., Hidaryan H., Rezaeeas N., Kohneshin A. Antibacterial Properties of an Iranian Ethnomedicinal Plant. *Int J Ayu Pharm Chem.* 2017; 6(3): 128-137.
10. Moradi R., Hajialiani M., Zangeneh M.M., Zangeneh A., Faizi S., Zoalfaghari M., Marabi A. Study a plant extract as an antibacterial agent. *IJCMPR.* 2017; 3(2): 1360-1362.
11. Hosamani K.M., Ganjihah S.S., Chavadi D.V. *Alternanthera triandra* seed oil: A moderate source of ricinoleic acid and its



- possible industrial utilization. *Indus Crop Prod.* 2004; 19: 133-136.
12. Schultz G.S. Molecular Regulation of Wound Healing. In: Acute and Chronic Wounds: Nursing Management, Bryant, R.A. (Ed.). 2nd Edn, *WB Saunders Publisher*, USA. 1999: 413-429.
13. Nagori BP., Solanki R. Role of Medicinal Plants in Wound Healing. *Res J Med Plants.* 2011; 5: 392-405.
14. Faramarzi E., Goorani S., Zangeneh M.M., Zangeneh A., Amiri-Paryan A., Almasi M., Najafi F., Tahvilian R. Effect of *Punica granatum* on wound healing in male Sprague Dawley rats. *Onl J Vet Res.* 2017; 21(9): 543-548.
15. Hagh-Nazari L., Goodarzi N., Zangeneh M.M., Zamgeneh A., Tahvilin R., Moradi R. Stereological study of kidney in streptozotocin-induced diabetic mice treated with ethanolic extract of *Stevia rebaudiana* (bitter fraction). *Comp Clin Pathol.* 2017; 26 (2): 455–63.
16. Zangeneh M.M., Najafi F., Tahvilian R., Haghazari L., Zangeneh A., Abiari M., Moradi R. Study on the in vitro antibacterial properties of alcoholic extract of *Stevia rebaudiana* in west of Iran. *Int J Sci Eng Res.* 2016; 7 (11): 1352-1359.
17. Zangeneh M.M., Najafi F., Moradi R., Tahvilian R., Haghazari L., Zangeneh A. Evaluation of the in vitro antibacterial activities of alcoholic extract of *Stevia rebaudiana* against *Escherichia coli* O157: H7 (ATCC No. 25922). *Asian J Pharm Anal Med Chem.* 2016; 4(3): 131- 136.
18. Zangeneh M.M., Poyanmehr M., Najafi F., Zangeneh A., Moradi R., Tahvilian R., Haghazari L. In vitro antibacterial activities of ethanolic extract of *Stevia rebaudiana* against *Bacillus subtilis* (ATCC No. 21332). *Int J Res Pharma Nano Sci.* 2016; 5(6): 320-325.
19. Zangeneh M.M., Najafi F., Tahvilian R., Salmani S., Haghazari L., Zangeneh A., Moradi R. Ethnomedicinal Plants: *In vitro* Antibacterial Effects of Ethanolic Extract of *Stevia rebaudiana*. *Int J Ayu Pharm Chem.* 2017; 6(1): 251-259.
20. Oryan A., Tabatabaieinaieni A., Moshiri A., Mohammadalipour A., Tabandeh M.R. Modulation of cutaneous wound healing by Silymarin in rats. *J Wound Care.* 2012; 21: 457-64.
21. Oryan A., Mohammadalipour A., Moshiri A., Mohammad R., Tabandeh M.R. Avocado/soybean unsaponifiables: a novel regulator of cutaneous wound healing, modelling and remodeling. *Int Wound J.* 2015; 12(6): 674-85.
22. Chitra S., Patil M.B., Ravi K. Wound healing activity of *Hyptis suaveolens* (L)





- poit (Laminiaceae). *Int J Pharm Technol Res.* 2009; 1: 737-744.
23. Buganza-Tepole A., Kuhl E. Systems-based approaches toward wound healing. *Pediatric research.* 2013; 73: 553-563.
24. Falanga V. Wound healing and its impairment in the diabetic foot. *Lancet.* 2005; 366: 1736-43.
25. Singh M.P., Sharma C.S. Wound healing activity of Terminalia Chebula in experimentally induced diabetic rats. *Int J Pharm Technol Res.* 2009; 4(1): 1267-1270.
26. Shin D., Minn K.W. The effect of myofibroblast on contracture of hypertrophic scar. *Plast Reconstr Surg.* 2004; 113: 633-640.
27. Langton A.K., Herrick S.E., Headon D.J. An extended epidermal response heals cutaneous wounds in the absence of a hair follicle stem cell contribution. *J Invest Dermatol.* 2008; 128: 1311.
28. Courtois M.C., Sapoval M., Del-Giudice C., Ducloux R., Mirault T., Messas E. Distal revascularization in diabetic patients with chronic limb ischemia. *J Mal Vasc.* 2015; 40: 24-36.
29. Nayak B.S., Pinto-Pereira L.M. *Catharanthus roseus* flower extract has wound-healing activity in Sprague Dawley rats. *Complement Altern Med.* 2006; 21(6): 41-47.
30. Kumar M.S., Sripriya R., Raghavan H.V., Sehgal P.K. Wound healing potential of *Cassia fistula* on infected albino rat model. *J Surg Res.* 2006; 131: 283-289.