

## Bilateral ovarian carcinoma in a young women

Divya<sup>1,\*</sup>, Saritha Shamsunder<sup>2</sup>, Supriti Kumari<sup>3</sup>, Srividya Thangavelu<sup>4</sup>, Rupali Dewan<sup>5</sup>

<sup>1</sup>Research Officer, <sup>2</sup>Associate Professor, <sup>3</sup>Senior Resident, <sup>4</sup>Post Graduate, <sup>5</sup>Professor & Consultant, Dept. of Obstetrics & Gynecology, Vardhman Mahavir Medical College and Safdarjung Hospital, New Delhi, India

**\*Corresponding Author: Divya**

Email: divambbs@gmail.com

**Received:** 20<sup>th</sup> September, 2018

**Accepted:** 12<sup>th</sup> February, 2019

### Abstract

**Introduction:** We present a case report of mucinous cystadenoma ovary in a 27 year old multiparous female who presented in SJH gynae outpatient department.

**Case Report:** Patient presented with abdominal mass which was rapidly growing and associated with pain abdomen since 2 months. On General examination patient's condition was fair and she was thin built. On palpation- an abdominal mass of around 20 cm size whose lower margins could not be reached and was firm in consistency. Tumor mass was moving side to side, it's margins were ill defined and extending till xiphisternum and reaching iliac fossa both sides.

Her CA125 levels were 219 IU/ml and S.LDH level was 553 IU/ml. All other tumour markers are normal. Ultrasound examination showed entire abdomen and pelvis was occupied by a multicystic mass which showed septae within it. No significant omental thickening noted. Uterus is normal and shows ET-4mm. ovaries cannot be visualised separately.

CECT whole abdomen and pelvis showed large multiloculated multicystic lesion appears to be originating from the right adnexa of size ~19.8\*10.5\*21.8cm in the abdomino-pelvic region with enhancing septae and internal vascularity was seen. Few of the septae appears thickened. Another small solid cystic lesion of size 86\*40\*85mm is seen in left adnexa with enhancing solid component and enhancing thickened septae with internal vascularity within. Uterus is seen separately and appears normal. There is no free fluid in abdomen.

Explorative laprotomy was planned. A midline incision was given and after excision of mass the specimen was sent for scrape cytology and findings were suggestive of malignant epithelial tumour (possibly mucinous) of ovary. Excision of Left sided ovarian mass and total hysterectomy with partial omentectomy was performed.

The examination of the pelvis, abdominal walls, diaphragmatic surface, and peritoneum did not show any implants or metastases but omental metastases were present. Free fluid was absent in the abdomen. There was no normal ovarian tissue on both sides so bilateral salpingo-oophorectomy was performed.

Histopathological examination gave confirmatory diagnosis of mucinous cystadenoma of the ovary. Patient and relative were counselled for further treatment and prognosis. On 14<sup>th</sup> day suture removal done and patient sent for chemotherapy and was discharged in good condition.

**Keywords:** Bilateral, Mucinous cystadenoma, CA125.

### Introduction

In the contemporary age of medicine, regular gynecological examinations and ultrasound Imaging have helped us in early detection of tumors so a huge bilateral ovarian tumor is a rare finding. These enormous tumors usually causes mechanical pressure on respiratory and urinary systems. Hence management of such tumours is essential to negate the secondary effects along with treatment of the primary ovarian tumour.<sup>1</sup> Mucinous cystadenomas represents 15-20% of all ovarian tumors. These tumors become so enormous that they extend upwards into the abdomen. Here we present a rare case of mucinous cystadenoma in a 27 year old female.

### Case Summary

A 27 years old multiparous women presented in gynaecology outpatients department in Safdarjung hospital with abdominal mass which was rapidly growing and was associated with pain abdomen since 2 months. Patient had h/o multiple blood transfusions 3months back i/v/o severe anaemia followed by jaundice. Patient underwent c- section two years back and had h/o pulmonary tuberculosis 4 years back. There was no other significant medical or surgical history. General physical examination of patie was good. She

was thin built and weighed 42kgs. Respiratory and cardiovascular examination was normal on palpation- an abdominal mass was of ~20 cm size, lower margin could not be reached, firm in consistency. Tumor mass was mobile side to side, margins were not defined and it was extending upwards till xiphisternum and was reaching iliac fossa on both the sides.

Her CA125 levels were 219 IU/ml and S.LDH level was 553 IU/ml. All other tumour markers are normal. Ultrasound examination showed entire abdomen and pelvis was occupied by a multicystic mass which showed septae within it. No significant omental thickening noted. Uterus is normal and shows ET-4mm. ovaries cannot be visualised separately.

CECT whole abdomen and pelvis showed large multiloculated cystic lesion of size ~19.8\*10.5\*21.8cm in the abdomino-pelvic region with enhancing septae and internal vascularity (Fig. 1). Few of the septae appears thickened measuring approx 4-5mm thickness. The cystic lesion appears to be originating from the right adnexa and causing superior displacement of the bowel loops. Another small solid cystic lesion of size 86\*40\*85mm is seen in left adnexa with enhancing solid component and enhancing thickened septae with internal vascularity within (Fig. 2). Uterus is seen separately and appears normal. There was no free fluid seen

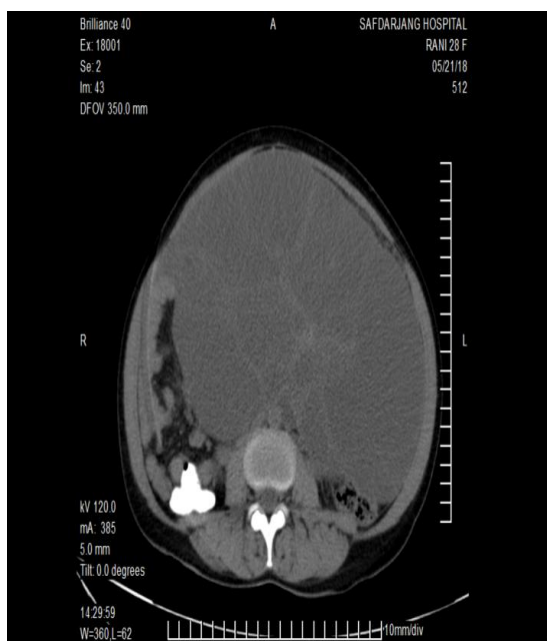
in abdominal cavity. Great vessels in view (IVC& aorta) are unremarkable. No evidence of significant lymphadenopathy is seen.

Explorative laprotomy was planned. A midline incision was given. A huge smooth surfaced mass could be seen in the abdomen. At surgical exploration, it was found that tumour was arising from the right ovary. After excision of mass the specimen was sent for scrape cytology and findings were suggestive of malignant epithelial tumour (possibly mucinous) of ovary. Excision of Left sided ovarian mass with total hysterectomy and partial omentectomy was performed.

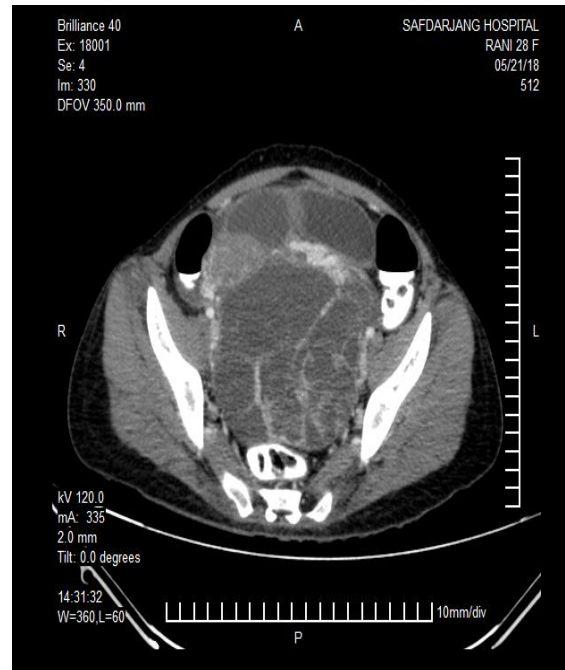
Pelvis, abdominal walls, diaphragmatic surface, and peritoneum did not show any implants or metastases but omental metastases could be seen on examination. Free fluid was absent in the abdomen. There was no normal ovarian tissue on both sides so bilateral salpingo-oophorectomy was performed. The right and left ovarian tumour measured 20×15×15cm (Fig. 3-5) and 10×15×15cm (Fig. 6) respectively.

Macroscopic examination revealed that the tumor was filled with material which was smooth surfaced, tumor had solid areas, was white in colour and vascularity was more on the tumour surface. On gross examination, the cystic mass was filled with thick tenacious mucinous material, and it had multiloculation with thin septations. Histopathologic examination showed cystic structure lined with mucinous epithelium and cysts did not have papillary formations. The diagnosis of mucinous cystadenoma of the ovary was confirmed.

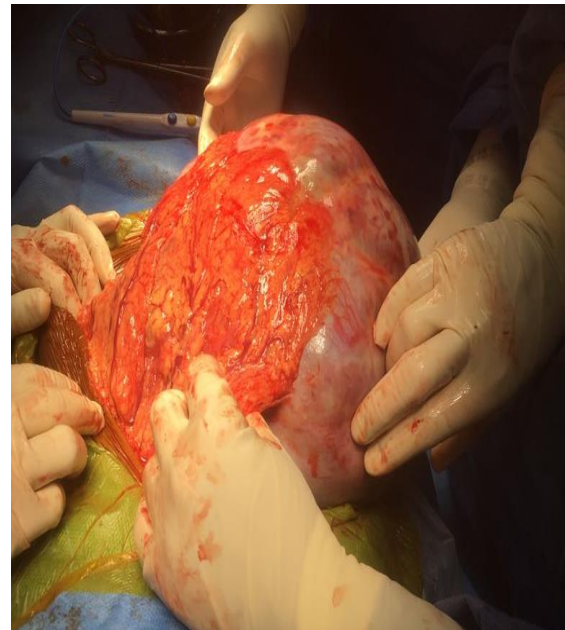
Patient and relative were counselled for further treatment and prognosis. On 14<sup>th</sup> day suture removal done and patient sent for chemotherapy and was discharged in good condition.



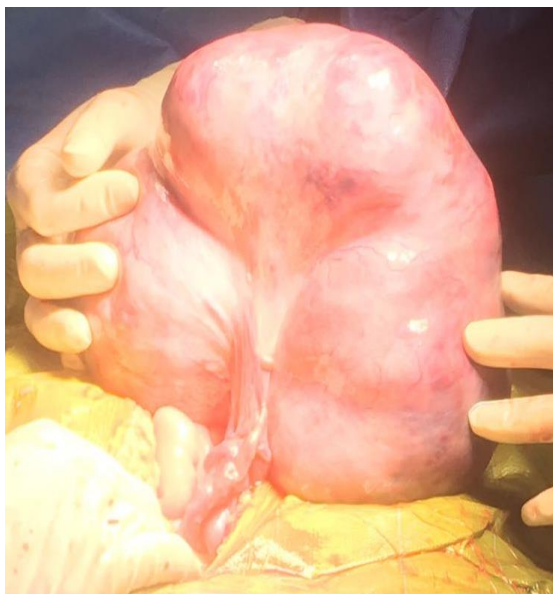**Fig. 1:** CECT whole abdomen shows right sided ovarian mass



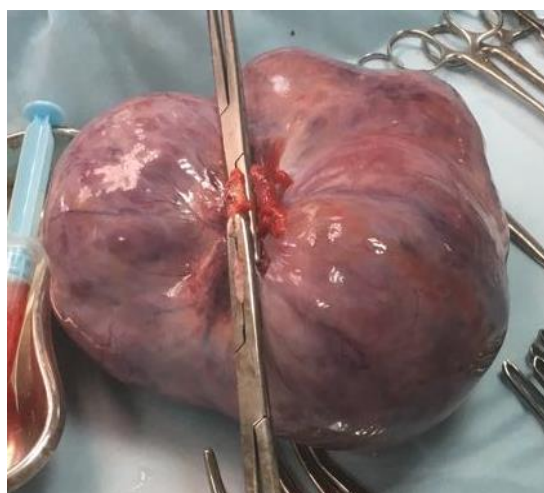
**Fig. 2:** CECT whole abdomen shows left ovarian mass



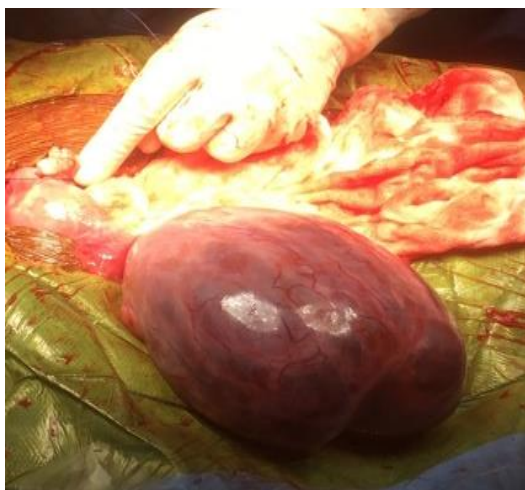
**Fig. 3:** Intraoperative picture showing omental attachment with the mass



**Fig. 4:** Intraoperative picture showing tubal attachment



**Fig. 5:** Complete unruptured right ovarian mass



**Fig. 6:** Left sided ovarian mass

## Discussion

Ovarian tumors are of 4 types of tumors

1. Epithelial tumors (65%-75%) - serous or mucinous cystadenoma/carcinoma, clear cell carcinoma, Brenner tumor;
2. Germ cell tumors (15%)
3. Sex-chord-stromal tumors (5%-10%)
4. Metastatic tumors (10%)

These ovarian tumors may be multi loculated or multi-septated. They can present as cystic masses with thin walls. They may have variable ounces of solid tissue which could have proliferating stromal tissue, papillae, or malignant tumor cells. Tumour markers may also help us to determine the origin of tumour. Mucinous cystadenomas are of three types: benign, borderline, and malignant. Prognosis is good with 10 year survival rate of 100% for benign tumors, 60% for borderline tumors, and only 34% for the malignant subtype. Benign mucinous tumors are usually detected earlier in life than malignant tumours

Mucinous cystadenomas usually occurs between 30-50 years of age. Benign tumors are bilateral in 5%-10% of cases. Malignant mucinous cystadenoms are rare, and encompass 10% of mucinous ovarian tumors and 5%-10% of primary malignant ovarian neoplasms overall. They are bilateral in 15% 30% of cases and have a peak incidence between 40 - 70 years of age.<sup>2</sup>

Giant mucinous cystadenocarcinoma of ovary with bilateralism with huge abdominal mass is very rare. Cyst's epithelium is usually cylindrical and has a cuboidal epithelium which is mono or multi- stratified. Pressure inside the cyst causes the classical cells to show clear cytoplasm and a hyper-chromatic nucleus at the base.<sup>3</sup>

Young patient with huge abdominal mass with sudden progression and bilateralism is very rare in mucinous cystadenocarcinoma of ovary. Our objective of case report is to give attention to ovarian epithelial tumours in OPD and PHC services to decrease incidence in any undiagnosed or mis-diagnosed cases.

Ovarian tumours are usually diagnosed incidentally during imaging. Ultrasonography is the first line modality to detect any pathology larger masses and metastatic involvement are usually detected by Computed tomography and magnetic resonance imaging scans. Serial measurements of the biomarker CA-125 can be of great help.<sup>3</sup> Surgery is the primary treatment for larger tumours even if it's benign. The contralateral ovary is also carefully examined. Hunter et al reported that rupture of the cyst capsule and greater dissemination can be prevented by gradual decompression. Tumour seeding of peritoneal cavity, bleeding, infection, and increased adhesions can be associated with repeated paracentesis so should be avoided.<sup>5</sup>

Differential diagnoses of ovarian masses include congenital splenic cyst, mesenchymal hamartoma, choledochal cyst, hydrops of the gallbladder, pancreatic pseudocyst, pancreatic cystadenoma and many more. So differential diagnosis should be kept in mind. Early diagnosis is important for early and timely management.

## Conclusion

In developing countries, ovarian tumours are usually found during advanced stages of the disease. Fortunately, in our case, the tumours were removed successfully without any dissemination despite a delay in diagnosis.

## Abbreviations

S. CA 125 = Serum Cancer Antigen

S. LDH = Serum Lactate Dehydrogenase

S. CEA= Serum Carcinoembryogenic Antigen

Beta HCG= Beta Human Chorionic Gonadotrophin

OPD= Outpatients Department

PHC= Primary Health Centre

**Conflict of Interest:** None.

## References

1. Sebastin A, Thomas A, Regi A. Giant benign mucinous cystadenoma: A case report. *Open J Obstet Gynaecol* 2012;2:220-222.
2. Katke RD, Huge Mucinous Cystadenocarcinoma with Mucocoele of Appendix in a Postmenopausal Women: Extremely Rare Case Report with Review of Literature. *Gynaecol Obstet (Sunnyvale)* 2015;5:279. doi:10.4172/2161-0932.1000279
3. A 9-kg ovarian mucinous cystadenoma in a 14-year old premenarchal girl. *Am J Case Rep* 2014;15:326-329
4. Kotis A, Karatapani S, Papamargaritis V, Ligos P, Sisamotos G. A Case of a large ovarian tumour. *BMJ Case Rep* 2011;2011.
5. Hunter DJS. Management of a massive ovarian cyst. *Obstet Gynaecol* 1980;56:254-255.

**How to cite this article:** Divya, Shamsunder S, Kumari S, Thangavelu S, Dewan R. Bilateral ovarian carcinoma in a young women. *Indian J Obstet Gynecol Res* 2019;6(1):101-104.