

A rare case report of vaginal delivery of term conjoined twins with traumatic PPH: patient surviving the ordeal at the cost of the womb

Dhwani Mehta^{1,*}, Kritika², Akansha³, Nimish Pandya⁴

¹2nd Year Resident, ²Senior Resident, ³Assistant Professor, ⁴HOD, Dept. of Obstetrics and Gynecology, Gujarat Adani Institute of Medical Sciences, Gujarat, India

***Corresponding Author: Dhwani Mehta**

Email: dhwanimehta02@gmail.com

Received: 30th August, 2018

Accepted: 16th October, 2018

Abstract

Conjoined Twin – “An extremely rare phenomenon “has its incidence from 1 in 49,000 to 1 in 1,89,000 with higher incidence in south east Asia and Africa. Its fetal and maternal outcome depends on the age of gestation, the site of fusion and most of them are still birth babies with the survivors being the female ones. Khavda district of Kachchh (Bhuj, Gujarat, India) witnessed such a delivery of a Cephalothoracophagus conjoined twin in a multigravida who developed traumatic post partum haemorrhage after a normal vaginal delivery and was referred to our hospital which is the only tertiary care centre of Kachchh district, i.e Bhuj. **Case:** A 35 year old female patient P7L6D2, presented with severe post partum haemorrhage after vaginal delivery of a full term conjoined twin at community health centre, Khavda. On examination it was a case of traumatic post partum haemorrhage with right colporrhexis with traumatic rupture of uterus. Patient was taken for exploration of tear and colporrhexis and obstetric Hystrectomy was performed. She was saved at the cost of her uterus which bore her a Boon. Where illiteracy prevails; prevails the tradition of multigravid pregnancy with unawareness regarding prenatal screening and antenatal visits which at times costs the patient her life.

Keywords: Multigravida, Conjoined twin, Cephalothoracophagus, Colporrhexis, Obstetric hystrectomy, Traumatic post partum haemorrhage.

Introduction

Kutch district (also known as Kachchh) is the largest district of India located in the Gujarat State covering an area of 45,674 square kilometres. It comprises of 939 villages and approximately has 10 talukas or districts with only 30 percentage of people living in the urban area. All the districts are well equipped with community health centre which happens to be the first door step for any pregnant female patient either for routine antenatal visit or for conducting deliveries.

Our hospital in Bhuj is the only tertiary care referral centre for high risk pregnancies in Kachchh district. With majority of people living in the rural areas where illiteracy is a predominant factor and other being staunch religious beliefs, people here are not willing for antenatal check up or antenatal ultrasound. For the same reason they are not adopting contraceptives and family planning methods resulting in multiparity. If people here understand the basic need of obstetric ultrasound scanning various congenital malformations, twin pregnancies can be diagnosed beforehand and mishaps can be avoided as in our case where conjoined twins were diagnosed after delivery.

Conjoined Twins represent one of the rarest form of twin pregnancy with incidence ranging from 1 in 50,000 to 1 in 1,00,000 live births. As the situation carries high risk, early diagnosis and management is extremely important with ultrasound having a pivotal role. If diagnosed near term caesarean section is the mode of delivery for terminating the pregnancy.

Case

A 35 year old female patient, was referred to our hospital from Khavda Community Health Centre for post partum haemorrhage. She was an unbooked and an uninvestigated case where normal vaginal delivery was done by the trained birth attendant at the CHC and term conjoined twins were delivered unknowingly which was even a surprise to them. Soon after the delivery of the placenta she developed post partum haemorrhage which continued even after giving drugs. After Vaginal packing she was immediately referred to our centre. (Fig. 1)

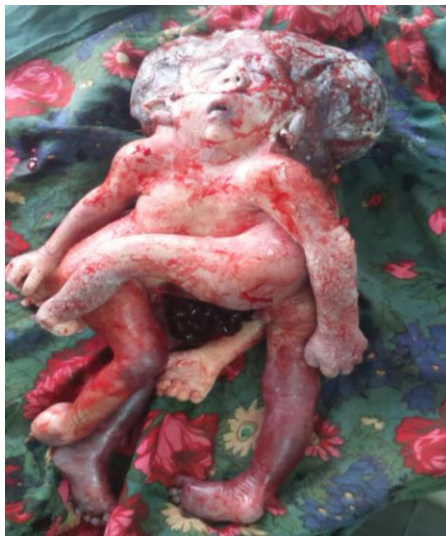

Fig. 1: Delivered cephalothoracophagus conjoined twins

On examination her vitals were – Pulse 120 beats per minute with blood pressure 90/50 mm hg with respiratory rate of 14 per minute with cold extremities. she appeared to be in hypovolemic shock.

On per abdomen examination - uterus was contracted 24 weeks size. After removing the vaginal packs per speculum examination was conducted which revealed clots and gush of bleeding. Per vaginal examination revealed a large cervical tear was present which was involving the lower uterine segment.

Immediately, the patient was shifted to the operation theatre for exploration under general anaesthesia. Adequate products of packed cell volume and platelet products were arranged. Under adequate light exposure and general anaesthesia in the lithotomy position, tear was found to extend in right vagina, fornix, cervix and lower uterine segment. Therefore general anaesthesia was administered for an explorative laprotomy. Proper aseptic precautions were maintained and a midline sub umbilical incision was made over the abdomen. Abdomen was opened in layers. Once the peritoneum was opened - a huge right side broad ligament haematoma extending from round ligament until cornua to upper one third of vagina was found of approximately 8* 7 cm size with right colporrhexis. (Fig. 2)

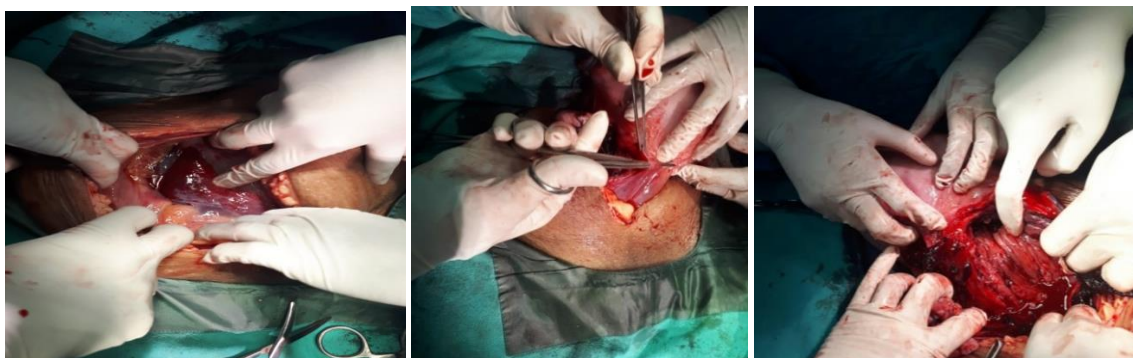

Fig. 2: Right sided broad ligament haematoma and right side colporrhexis

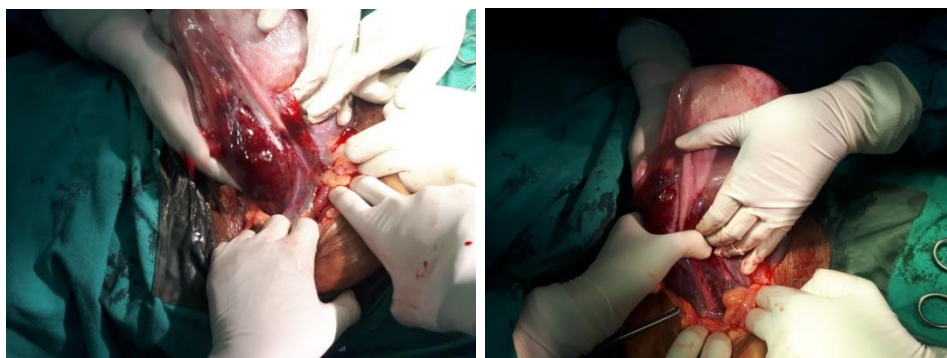


Fig. 3: Right sided broad ligament haematoma

Consent for obstetric Hysterectomy was sought for as conserving the uterus was not possible.

Heaney's clamp were applied (Fig. 3) on either side of the cornua - Round ligament, fallopian tube, utero-ovarian ligament clamped cut and ligated. Vesico uterine fold of peritoneum opened, bladder was

dissected below by fine mayo tissue cutting scissor. 4 The huge right broad ligament haematoma was evacuated and uterine artery was identified which was bleeding and was ligated left side uterine artery ligated clamped cut and ligated doubly.

Clamp was applied on mackernrods ligament, which was bilaterally clamped cut and ligated two clamps applied on either side.

Upper end of vagina caught with long Allis forceps the vault sutured and ends suspended with the uterosacral ligament pedicles. Tear at the lower end of vagina on the right side identified, held with allis forceps and sutured with delayed absorbable sutures in a continuous manner upto right angle of vagina taken. Complete hemostasis was achieved. Visceral peitonization of vaginal vault was done. Intra-abdominal drain was placed.

Pedicles checked for hemostasis. Closure was done of abdomen in layers. Vaginal toileting done. (Fig. 4)

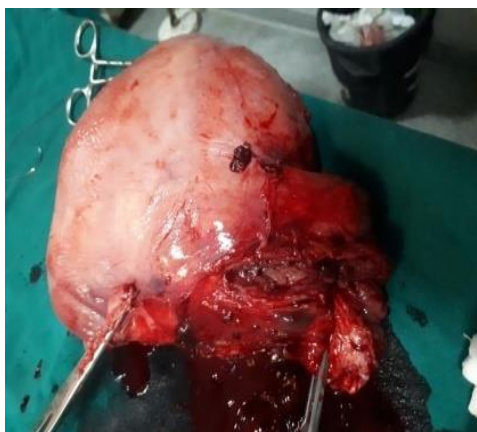

Fig. 4: The specimen after obstetric hysterectomy

The patient was finally saved. She had an uneventful hospital course of ten days. She was kept nil by mouth two days with antibiotic coverage of third generation cephalosporins, metronidazole and amikacin with adequate antacids and analgesics. Her intra-abdominal drain was removed on fifth post operative day and her stitches were removed on tenth day and was discharged.

Discussion

Conjoined twins are derived from one ovum and are monochorionic and monoamniotic. There are two theories which have been proposed to describe the conjoined twinning. According the first theory there occurs incomplete fission of a single embryonic disc 13 to 15 days after the fertilization of the ovum. The second theory proposed by Spencer was that the fertilized ovum divides completely into two embryonic discs whose unusual proximity results in a secondary fusion and results in conjoined twin pregnancy.²

Where access to technology is limited, where the general population is illiterate and where sensitization to antenatal check up, ante natal ultrasonography is not there, diagnosing conjoined twins ante partum is next to impossible. Such happened in our case. Diagnosis of conjoined twins before birth allows the obstetrician to timely intervene and plan a safe mode of delivery rather

than ending up in a situation of traumatic post partum haemorrhage and endangering one's own life.

First and second trimester detection of conjoined twins enables obstetrician to counsel the parents about potential termination or gives room for preparedness about the delivery and fetal outcome.

Approximately 40 percentage are still born, 35 percentage die in the first 24 hours and 60 percentage surgically treated survive.

Vaginal deliveries have been reported but it results in dystocia, uterine rupture, maternal soft tissue injury. Vaginal delivery can be conducted if maceration or anencephaly is suspected with destructive procedures like craniotomy, decapitation, evisceration if needed.

Lest ceaserean section is the ultimate mode of delivery.

The woman lost her womb but her life got saved as she got timely referred.

References

1. Khalid Kamal "Conjoined Twins Treatment & Management.
2. Carnevale FC, Borges MV, Affonso BB, Pinto RA, Tannuri U, Maksoud JG. Importance of angio graphic study in pre operative planning of conjoined twins: a case report at Sao Paulo, Brazil. *Send to Clinics (Sao Paulo)*. 2006;61(2):167-70.
3. Harma M1, Harma M, Mil Z, Oksuzler C. Vaginal delivery of dicephalic parapagus conjoined twins: case report and literature review. *Tohoku J Exp Med*. 2005;205(2):179-85.
4. Abdullah Karaer, İsmail Tanrıku, Nedim Güneş, Ediz Çakır, Afşin Öztaş. Parapagus dicephalus dipus: A case if conjoined twins. *J Turk Ger Gynecol Assoc*. 2009;10(4):241-243.
5. Pajkr E1, Jauniaux E. First-trimester diagnosis of conjoined twins. *Prenat Diagn*. 2005;25(9):820-6.
6. Rajesh Kumari, Renu Arora, Nevadita Sarda, Jyotsna Suri, Pratima Mittal. Thoracopagus conjoined twin: an unusual presentation. *Int J Reprod Contracept Obstet Gynecol*. 2014;3(1):245-247.
7. de Silva R S, Amaradivakara P W. Antenatal Diagnosis and Management of Conjoined Twins: A case Report. *Sri Lanka Journal of Obstetrics and Gynaecology*. 2015;24-26.

How to cite this article: Mehta D, Kritika, Akansha, Pandya N. A rare case report of vaginal delivery of term conjoined twins with traumatic PPH: patient surviving the ordeal at the cost of the womb. *Indian J Obstet Gynecol Res*. 2018;5(4):567-569.