

Clinical and microbiological profile of infective keratitis and their antibiotic sensitivity

Ashwini S Waghmare¹, Praveen Kumar Sadanand^{2,*}

¹Tutor, ²Assistant Professor, ¹Dept. of Microbiology, ²Dept. of Ophthalmology, Bidar Institute of Medical Sciences, Bidar, Karnataka, India

***Corresponding Author: Praveen Kumar Sadanand**

Email: drpravs@yahoo.co.in

Abstract

Introduction: Microbial keratitis is a common, potentially vision-threatening ocular infection that may be caused by bacteria, fungi, or parasites. Successful treatment of corneal ulcer requires proper diagnosis and early institution of intensive therapy with appropriate antimicrobial agents.

Aim: To determine specific pathogenic organism and clinical risk factors for infective Keratitis.

Materials and Methods: Patient with clinical features of infective keratitis attending Ophthalmology OPD were included whose corneal scrapings were subjected to Gram staining, KOH Mount and culture sensitivity. Statistical analysis done by using appropriate statistical methods.

Results: 40 cases were evaluated. 23 were males and 17 females. Age ranged from 21 to 70 years. History of trauma was present in 47.5% of patients, ocular surface disease was present in 10% while diabetes was present in 10% of patients. Based on culture reports, bacterial and fungal keratitis found in (65%) 26 patients. There was no organism isolated from rest of the 14 samples (sterile keratitis). Bacteria were isolated in 14 samples and in 12 samples fungal growth was isolated. The commonest bacterial isolate were Staphylococcus aureus followed by Pseudomonas, Coagulase negative staphylococcus and Klebsiella. Aspergillus species was isolated in 7 patients and fusarium species in 4 patients. Gram positive isolates were maximally sensitive to Ofloxacin, gram negative to Gentamicin.

Conclusion: Staphylococcus aureus was the most common bacterium while Aspergillus was the most common fungus isolated. Trauma was the commonest risk factor for corneal ulcer.

Keywords: Corneal ulcer, Staphylococcus, Aspergillus, Trauma, Culture.

Introduction

The patients with ulcerative keratitis present both diagnostic and therapeutic challenge to Ophthalmologists. Successful treatment of corneal ulcer requires proper diagnosis and early institution of intensive therapy with appropriate antimicrobial agents. Permanent visual dysfunction has been reported in a significant number of patients in both developed and developing nations.¹

In a report published from L.V. Prasad Eye Institute, Hyderabad, of the culture positive cases 63.9% were bacterial, 33% were fungal, 2.1% were parasitic and 6.2% were due to mixed infection. Common organisms responsible for bacterial keratitis are Staphylococcus aureus, S.epidermidis, Streptococcus pneumoniae, Pseudomonas aeruginosa, Enterobacteriaceae, Proteus, Enterobacter, Serratia, Citrobacter. Filamentous fungi which includes Aspergillus and Fusarium causes the bulk of the fungal corneal infections following corneal abrasion in an agricultural setting in our country².

Although strict textbook recommendation makes laboratory diagnosis mandatory, such facilities are rarely available with most Ophthalmologists. Therefore, empirical treatment has become the norm. Since bacteria cause a significant percentage of suppurative keratitis cases and many broad-spectrum bactericidal antibiotic regimen are available, only a small proportion of cases fail to respond to empirical therapy. However in India nearly 40% cases are caused by nonbacterial agents i.e., fungi and parasites.

In this region of North Karnataka, being predominantly agricultural population, risk of corneal injury is high and if not treated appropriately leads to corneal blindness. The

present study was conducted to help the Ophthalmologists in effective management of keratitis and to know the profile of organisms leading to corneal ulcer.

Materials and Methods

This is a prospective cross sectional study conducted in Microbiology Department, BRIMS, Bidar, Karnataka from October 2016 to September 2018. Institutional Ethical Committee clearance was taken and informed consent from every patients recorded.

Inclusion Criteria

Patients attending Ophthalmology Out Patient Department with clinical features of infective keratitis.

Exclusion Criteria

Patients with marginal keratitis, Mooren's ulcer, autoimmune keratitis, exposure keratitis and viral keratitis were excluded.

Collection of Sample:^{3,4}

Proper history was taken like occupation, trauma, ocular surgery, antibiotic or steroid usage. Corneal scraping is done from the leading edge and base of the ulcer by using Kimura spatula or 15No. Bard Parker sterile surgical blade by an Ophthalmologist with the help of slit lamp under aseptic conditions after instilling proparacaine anaesthetic drops. The most probable etiology was suspected by the attending Ophthalmologist as fungal/bacterial/parasitic.

One sample was used for microscopy i.e., 10% KOH and Gram's stain and another sample for fungal and bacterial culture. The scrapings were inoculated on Sheep Blood Agar and Chocolate Agar for ulcers suspected to be caused by aerobic bacteria and onto Robertson's cooked

meat broth for anaerobic bacteria and Sabouraud's dextrose agar (SDA) for fungus. All the inoculated media were incubated at 37°C and examined after 1st, 2nd and 3rd day for organisms. Various types of test were performed for identification of organisms causing keratitis. Catalase followed by coagulase test was done to identify Gram positive cocci. Oxidase test, Indole test, methyl red, Voges prokauer, urease production test, citrate utilization test, triple sugar iron test were done to identify Gram negative bacilli. Lactose phenol cotton blue mount was prepared from growth on SDA for morphological identification of organism. Cultures were considered significant when, (a) growth of same organism on 2 or more media (b) semi confluent growth on one media consistent with smear findings.⁵

Antimicrobial susceptibility of bacterial isolates to antibiotics were used by Kirby Bauer disc diffusion method against penicillin, tetracycline, chloramphenicol, gentamycin, ciprofloxacin and ofloxacin. Statistically data was analysed using percentages, mean and Microsoft windows software.

Table 2. Risk factors associated with corneal ulcer

S. No.	Risk factor	No. of patients (Out of 40 patients)	Percentage %
1	Trauma with Vegetative matter	12	30
2	Cow tail	3	7.5
3	Wood	2	5
4	Unknown	2	5
5	Diabetes mellitus	4	10
6	Steroid usage	2	5
7	Dacryocystitis	1	2.5
8	Ocular surface disease	4	10
	Total	30	75

Out of 40 cases of corneal ulcers, 30 patients (75%) had a predisposing risk factor among which trauma was most common.

Table 3: Microbial flora isolated

Growth pattern	No. of patients	Percentage %
Single bacterial isolate	14	35
Single fungal isolate	12	30
Mixed growth	2	5
No isolate	12	30
Total	40	100

Table 4: Bacterial isolates

Bacteria	No. of isolates	Percentage %
Staphylococcus aureus	6	42.8
Pseudomonas	2	14.2
Coagulase negative staphylococcus	4	28.6
Klebsiella	2	14.2
Total	14	100

Results

A total of 40 samples were collected from patients with corneal ulcer satisfying inclusion criteria. There were (57.5%) 23 males and (42.5%) 17 females. 70% of ulcers involved right eye and 30% were left eye.

Table 1: Distribution of patients based on age, sex and occupation

Age in years	21 to 40	24
	41 to 70	16
Sex	Male	23
	Female	17
Occupation	Labour	10
	Farmer	19
	Carpenter	5
	Factory worker	6

47.5% of cases of infective keratitis were encountered in farmers.

Among bacterial isolates 42.8% of cases had staphylococcus as most common isolate.

Table 5: Fungal isolates

Fungi	No. of isolates	Percentage
Aspergillus fumigatus	4	33.33
Aspergillus flavus	3	25
Fusarium	4	33.3
Candida albicans	1	8.33
Total	12	100

30% of fungal isolates were recovered out of 40 cases of corneal ulcers and Aspergillus species was most common. The most effective antibiotic was ofloxacin followed by ciprofloxacin and gentamycin.

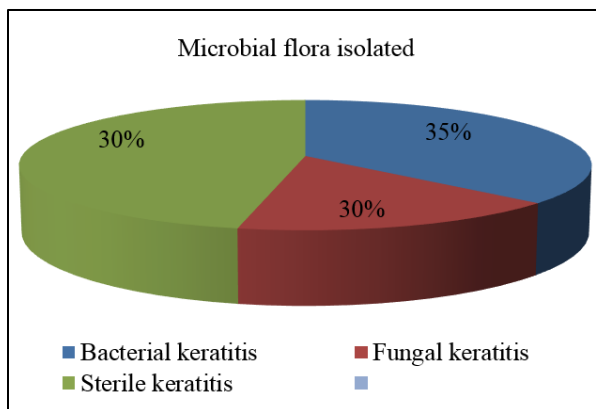


Fig. 1

5% cases mixed isolates were recovered

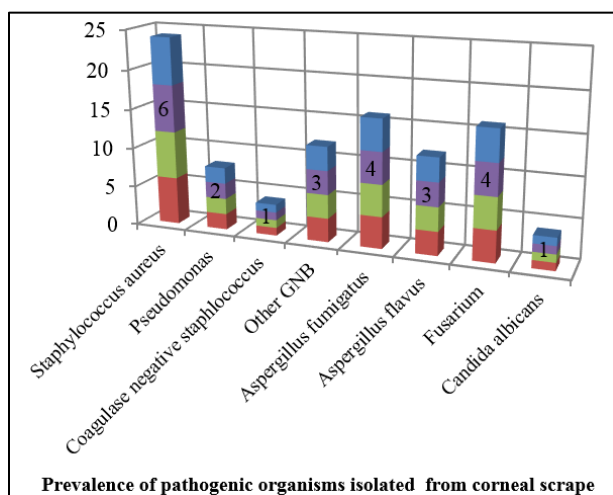


Fig. 2

Staphylococcus aureus was the most common organism isolated.

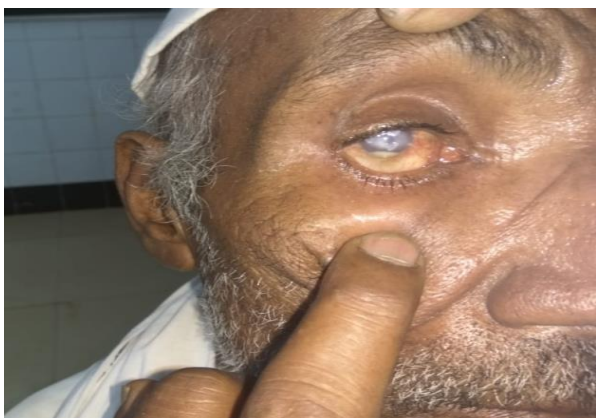

Fig. 3: Corneal ulcer with hypopyon

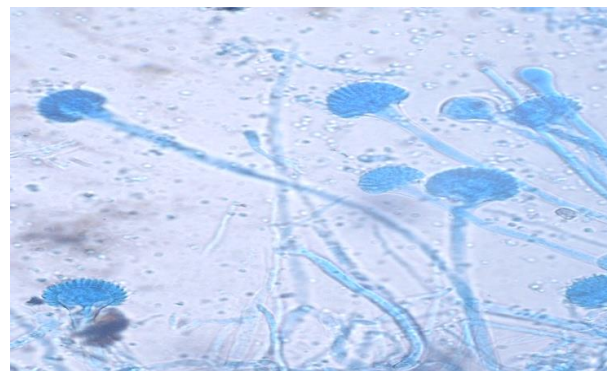


Fig. 4: LPCB mount of *A. fumigatus* (40X) showing smooth conidiophores, phialides uniseriate covering upper half to 3/4 of vesicle and parallel to stalk

Discussion

An attempt was made to know the causative microorganisms for ulcerative keratitis prevalent in our area with antimicrobial susceptibility of bacterial isolates.

In the present study 57.5% were males and 42.5% were females. 80% were from rural areas and 47.5% of patients were agricultural workers. Manual labourers and agricultural workers become prone to injuries and exposure to dust and wind with poor ocular hygiene, enhances development of corneal ulcer. As reported by Gopinathan et al, patients with agriculture based activities were at 1.33 times greater risk of developing microbial keratitis.⁶ Predisposing factors were present in 75% of cases with trauma (47.5%) being the most common and local steroid use in 5% patient. The percentage of cases preceding trauma was 65% in Madurai and 83% in Eastern India⁷. Out of 40 ulcers studied 30 cases showed presence of either bacterial or fungal elements on direct microscopy. 26 (65%) of ulcers were culture positive. Bacteria were isolated from 35% of ulcers and fungi in 30%. Similar pattern of microbial keratitis was reported by Gopinathan et al.⁶ However reports from North Karnataka have shown 41% fungal and 32% bacterial etiology.⁸

Among bacteria, review of literature shows variability in organism that is commonly isolated. The commonest bacterial isolate were *Staphylococcus aureus* followed by *Pseudomonas*, *Coagulase negative staphylococcus* and *Klebsiella*. Bacterial keratitis caused by *Psaeoroginosa* is more fulminant and associated with a worse visual prognosis than that caused by most other common bacterial pathogen. Our study is in accordance with study done by Suryawanshi Gaurav et al⁹ who isolated 12 (38.7) *staphylococcus aureus* as most common pathogenic bacteria followed by 8 (25.8%) *streptococcus pneumonia*, 6(19.35%) *pseudomonas* spp. According to observation of Bashir G et al,¹⁰ *streptococcus pneumoniae* was the commonest bacteria. The most effective antibiotic in our study was ofloxacin followed by ciprofloxacin and gentamycin. Jeng commented as the emerging resistance of bacterial infection to fluoroquinolones.

Fungal keratitis account for approximately 6 to 53% cases and up to 20% of fungal keratitis is complicated by

bacterial co infection. In our study there were 2 cases of bacterial and fungal co infection. 30% of fungal isolates were recovered out of 40 cases of corneal ulcers and *Aspergillus* species was most common. Filamentous fungi are frequent causes of corneal ulcers. *Aspergillus* spp, was the most common isolate of fungal keratitis reported in India, South Iran, Nepal and Bangladesh. *Fusarium* spp, has a more aggressive keratitis and is less responsive to treatment than *Aspergillus*. This is similar to results obtained by study done in Madurai by Sharma et al¹¹. The fungi causing keratitis are usually ubiquitous in nature and are introduced by trauma by plant origin especially among agricultural workers. 10% KOH mount (sensitivity 92%, specificity 96%) of the corneal scraping, examined by conventional microscope is a useful test in helping identification of fungi and parasites.²

30% of cases no isolates were recovered. This could be attributed to inadequate ulcer scraping sample and the fact that some of the cases were already put on empirical antibiotics.

Conclusion

Early detection and appropriate treatment are important to minimize permanent visual loss. Risk factors and predisposing factors for keratitis should be explained to high risk group i.e., agricultural workers, manual labourers and educated about the need to consult an Ophthalmologist urgently. Monitoring patterns of organisms causing keratitis, their antibiotic susceptibility can form basis for accurate management and empirical therapy.

Acknowledgement

We would like to thank staff of Ophthalmology Department for providing accurate clinical data and samples.

Source of Funding: Nil

Source of Conflict: Nil

References

1. Shah A, Sachdev A, Coggan D, Hussain P. Geographic variations in microbial keratitis. An analysis of peer reviewed literature. *Br J Ophthalmol* 2011;95(6):762-777.
2. AIOS, Ready Reckoner in Ophthalmology, 2nd edition.
3. Henry D, Isenberg, Marie P. Ocular cultures. Section 1. Essential procedures for clinical microbiology ASM Press, 1988. Page 1:131 to 1:136.
4. Tewari A, Sood N, Mehta DC. Epidemiological and microbiological profile of infective keratitis in Ahmedabad. *Indian J Ophthalmol* 2012;60:267-272.
5. Badiie P. Mycotic keratitis, a state of art review. *J Microbiol* 2013;6(5);e8561. DOI 10.5812/ijem 8561.
6. Gopinathan U, Sharma S, Garg P, Rao. GN. Review of epidemiological features, microbiological diagnosis and treatment outcome of microbial keratitis. *Ind J Ophthalmol* 2009;57:273-279.
7. Imtiaz Chaudhary. Bacterial keratitis infection: A battle between virulence factors and the immune response, common eye infection. ISBN: 978.953.51.0926.
8. Biradar S, Chandrashekar D K, Gangane R, Biradar K G, Vinod Kumar C S. Spectrum of microbial keratitis and antimicrobial susceptibility at tertiary care teaching hospital in North Karnataka. *Int J Pharm Biomed Res* 2012;3(2):117-120.
9. Suryavanshi Gaurav S. Khindria Ashish. 2013. Clinical study of causative microbial agents of suppurative keratitis. Caesin Rural Area. *Int J Res Health Sci*, Vol2 Issue 1:59 to 62.
10. Bashir G, Shah A, Thoker MA, Rashid S, Shakeel S. Bacterial and fungal profile of corneal ulcers: a prospective study. *Ind J Path Microbiol* 2005;48(2):273-277.
11. Sharma S, Srinivasan M, George C. The current status of *Fusarium* species in Mycotic keratitis in South India. *Indian J Med Microbiol* 1993;11(2):140-147.

How to cite this article: Waghmare AS, Sadanand PK. Clinical and microbiological profile of infective keratitis and their antibiotic sensitivity. *Indian J Microbiol Res* 2019;6(1):11-14.