

Anaesthetic management of endobronchial ultrasound guided trans bronchial needle aspiration: Our experience with laryngeal mask airway

Arpana Kedlaya¹, Rashmi Rani^{2,*}, Uma Devaraj³, Priya Ramachandran⁴, Uma Maheshwari⁵

^{1,2,3}Assistant Professor, ⁴Associate Professor, ⁵Professor, ^{1,2}Dept. of Anaesthesiology, ^{3,4,5}Dept. of Pulmonary Medicine, St Johns Medical College Hospital, Bangalore, Karnataka, India

***Corresponding Author: Rashmi Rani**

Email: rashmi172007@rediffmail.com

Received: 3rd July, 2018

Accepted: 9th August, 2018

Abstract

Introduction: Endobronchial Ultrasound Guided Trans bronchial needle aspiration (EBUS-TBNA) is a minimally invasive diagnostic modality for evaluating intra thoracic lymph nodes, becoming one of the important tool in the armamentarium of pulmonologists. The size of the fiberscope and sharing of the airway with the bronchoscopist poses unique challenges to the anesthesiologist. In light of these developments it is important to develop an office based anesthesia technique for this relatively new procedure. Hence we did this descriptive cohort study.

Aim: To describe the accuracy and anaesthetic management of EBUS-TBNA as a day care procedure, done with general anesthesia (GA).

Materials and Methods: Data was collected from January 2017 to December 2017 at our institute from patients who underwent EBUS-TBNA under GA using second generation laryngeal mask airway (LMA). Specifically, hemodynamic status, Oxygen saturation, duration of the procedure, diagnostic yield and complications of the procedure were recorded.

Results: 23 patients underwent EBUS-TBNA under GA. All patients were found to be hemodynamically stable with fluctuations in blood pressure and heart rate being less than 20% from the baseline with no episodes of desaturation. The average number of biopsies taken is 3.3, with average duration of the procedure being 67.0±17.6 (mean±SD) minutes. The incidence of post procedural complications like cough and sore throat were minimal. Successful diagnostic yield was found in all cases with no incidence of recall of the procedure.

Conclusion: The performance of EBUS-TBNA under general anesthesia with LMA provides great hemodynamic stability and adequate ventilation in a shared airway. It demonstrates excellent diagnostic accuracy. It provides comfort to the patient and the good examination conditions to the bronchoscopist.

Clinical Significance: Use of P-LMA solves the dilemma of managing ventilation during EBUS TBNA without affecting the diagnostic yield of the procedure.

Keywords: Endobronchial ultrasound, Trans bronchial needle aspiration, LMA, Propofol.

Introduction

Endobronchial ultrasound guided Trans bronchial needle aspiration (EBUS-TBNA) has emerged over the past decade as one of the most exciting and innovative development in the field of respiratory medicine. It is a relatively new, minimally invasive, highly effective diagnostic modality which is replacing mediastinoscopy for investigating mediastinal, hilar and intrathoracic lymph nodes. In 2003, Krasnik et al first reported the utility of convex probe EBUS-TBNA in sampling mediastinal nodes via fine needle aspiration under direct sonographic visualization.¹ Since then, this procedure is being performed with increasing frequency. EBUS has high sensitivity and specificity when compared to Computer Tomography (CT) or Positron Emission Tomography (PET) for mediastinal staging of patients with resectable lung cancer². This procedure takes a significantly long duration compared to conventional bronchoscopy due to the technicalities and experience of the pulmonologist.

Since its introduction into respiratory practice several airway management strategies have been used. EBUS-TBNA can be done using various types of

anesthesia including local anesthetic spray, mild to moderate (conscious) sedation and general anesthesia. Local anesthetic spray is used in some centers but patient comfort has not been satisfactory as reported in previous studies.³ General anesthesia with endotracheal intubation or Laryngeal mask airway (LMA) helps to achieve the anesthetic goals of providing secure airway access with adequate ventilation during this potentially distressing procedure while ensuring an acceptable work space for the bronchoscopist.

In view of these advancements, it is important to develop an office based outpatient anesthesia technique for this minimally invasive procedure. The aim of this article is to describe the accuracy and anaesthetic safety of EBUS-TBNA as a day care procedure, done with general anesthesia in diagnosing neoplasms and granulomatous diseases.

We intend to describe the appropriate choice of anesthesia for EBUS-TBNA to improve safety, comfort and procedural yield, according to the operator experience, procedural aim and institutional requirements.

Materials and Methods

The study protocol was approved by the institutional review ethical committee. We performed this descriptive observational study including all ASA I and II patients who underwent EBUS-TBNA in our tertiary care center from January 2017 to December 2017. All the patients with chronic cough and other constitutional symptoms were primarily evaluated by chest physicians thoroughly for interstitial lung disease, sarcoidosis, tubercular lymphadenitis, lymphomas etc. Patients were posted for EBUS-TBNA when all the haematological investigations, chest x-ray and contrast enhanced Computed tomography of chest were inconclusive in arriving at a diagnosis. Twenty five patients underwent the EBUS-TBNA under GA with laryngeal mask airway. But two patients had chronic renal failure and hence were excluded from the study and the rest were included. Patients' with morbid obesity, anticipated difficult airway, patients requiring endotracheal intubation for the procedure due to low saturation preoperatively and patients who underwent additional procedures like trans bronchial lung biopsy, endobronchial stents or cryobiopsy were excluded from the study. Since it is relatively new technique introduced in our institute, all the cases of EBUS-TBNA are being done under GA. All EBUS-TBNA procedures were performed by the same physician with a dedicated linear array bronchoscope (by Olympus Corporation, Tokyo, Japan). In all cases, 22 gauge fine needle aspirations was performed from enlarged lymph nodes identified on CT scan.

All patients were subjected to a thorough pre-anesthetic evaluation prior to the procedure. Written informed consent was taken from all patients for the study. All patients were examined for any signs of respiratory distress and all their preoperative investigations were recorded. Room air saturation of oxygen and the most comfortable position of the patient at rest was documented. On the day of the procedure, all the patients were instructed to be nil by mouth for 6 hours. With a secure intravenous access and all the standard monitors (NIBP, ECG, SPO₂, EtCO₂) attached, patients were pre-medicated with Inj. Glycopyrrolate 0.2mg, Inj. Ondansetron 4mg and Inj. Midazolam 1mg. We also administered Dexamethasone 4-6mg intravenously for all patients to prevent edema following airway instrumentation. After adequate pre oxygenation patients were induced with 2µg/kg of Inj Fentanyl and 1.5-2mg/kg of Inj Propofol intravenously. A size 4 ProSeal LMA (second generation Laryngeal mask airway) for females or size 5 P-LMA for males was then introduced and adequate oropharyngeal seal pressure was achieved to provide adequate ventilation. Patients were ventilated using a Bain's circuit with End Tidal Carbon di oxide (EtCO₂) monitoring. Airway insertion was considered successful if there was no air leak during bag ventilation and patient had an airway pressure of <20cm H₂O along with adequate chest

movements. A plastic swivel connector (catheter mount) was attached to LMA to allow access to the bronchoscope with a diameter of 6.9mm. Patients were then maintained with oxygen /air mixture (50%) and Propofol infusion (75-100µg/kg/min). Intermittent boluses of Inj. Fentanyl 20µg intravenously was administered when depth of anesthesia needed to be optimized. Ultrasound guided needle aspiration was done and adequate hemostasis achieved. The primary objective was the hemodynamic stability of the patient during the procedure. Anesthesia related complications such as hypotension (defined as a drop in MAP-mean arterial pressure >20% of baseline requiring fluids/vasopressors), hypertension (an increase MAP >20% from baseline requiring boluses of propofol) or hypoxemia (oxygen saturation of <90% for > 1min) were recorded. The other secondary objective was the duration of the procedure, number of punctures done, diagnostic yield (defined as the number of subjects in whom TBNA provided specific diagnosis) and EBUS related complications (i.e., bleeding {bleeding defined as bleeding requiring minimal suction to clear endoscopic view}, pneumothorax, mediastinitis, or mediastinal abscess). At the end of the procedure, a thorough check of tracheobronchial tree was done mandatorily for suctioning clots and/or secretions, before removing the bronchoscope from the airways. Patient tolerance to the procedure was also evaluated with a Likert's scale type questionnaire provided to patients before discharge after adequate recovery. A five point Likert's scale was used to rate the patients willingness to return for this procedure again in future if necessary. The choices were- definitely not, probably not, unsure, probably would and definitely would return. The patients used a 3-point Likert's scale (none, moderate, severe) to report their degree of discomfort, sore throat, throat pain, chest pain and shortness of breath.

Statistical Analysis

Since this is an observational descriptive study, no comparative or association data is presented. Results are presented as mean± SD of numbers and percentages. Continuous variables like duration of procedure are summarized using mean ± SD and categorical results like diagnostic yield are summarized using proportions.

Results

Twenty three patients were enrolled for the study between January 2017 to December 2017. All patients underwent the procedure under general anaesthesia with ProSeal laryngeal mask airway. Data relating to the performance of EBUS-TBNA procedures were recorded including clinical indications of the procedure and co-morbid illness of the patients.

Demographic data included (n=16)69.6% males and (n=7) 30.4% females. Table 1 and Fig. 1 shows the

demographic data along with duration of procedure. The average duration of the procedure under general anaesthesia was 67.0±17.6 minutes.

The majority of indications included granulomatous diseases (n=9)39.13% and neoplasms (n=8) 34.78% which are depicted in figure 2.5 examinations were performed for diagnosing mediastinal lymphadenopathy without primary neoplasms and 3 were performed for staging of diagnosed lung cancers.

All patients were found to be hemodynamically stable with fluctuations in blood pressure and heart rate being less than 20% from the baseline with no episodes of desaturation (Details in table 2). EBUS-TBNA yielded a positive diagnosis in all (100%) patients with the average number of biopsies taken being 3.3.

All patients said that if necessary, they would like to undergo the same procedure again in the future under general anaesthesia using a 5-point Likert’s scale to rate their willingness.

Likerts3-point scale as in Table 3 shows the frequency and severity of complications in patients who underwent EBUS-TBNA. The most commonly reported complication was cough (47.8%) and sore throat (60.86%) which was mild to moderate in severity and was most prominent in the initial half an hour post-operatively. Most of the episodes were self-limiting not requiring any interventions but 5 patients required steam inhalation. No other major complications like severe bleeding, pneumothorax or chest pain requiring any escalation of care /treatment in the high

dependency unit (HDU) were noted in any patients. None of the patients reported any recall of the procedure.

Table 1: Demographic data

Subjects characteristics			
		No.	%
Sex	Male	16	69.6
	Female	7	30.4
Age (Yrs)	Mean ± SD	48.3 ± 9.4	
	Range	30 - 59 Yrs	

Values are expressed as mean±SD or number of patients and percentages.SD-Standard Deviation, yrs-Years.

Table 2: Haemodynamic data of all the patients who underwent EBUS-TBNA

MAP, HR, and SPO2		
	Mean ± SD	Range
maxMAP	101.5 ± 12.5	76 - 124
minMAP	82.6 ± 10.3	65 - 98
maxHR	109.2 ± 8.2	95 - 124
minHR	91.7 ± 9.2	75 - 110
maxSPO2	99.6 ± 0.9	96 - 100
minSPO2	98.7 ± 1.8	93 - 100

Values are expressed as mean±SD and Ranges. MAP-Mean Arterial Pressure, HR-Heart Rate, SPO2-Oxygen saturation, max-Maximum, Min-Minimum.

Table 3: LIKERT’S scale of symptoms severity

Symptoms	None	Small amount	Severe (substantial)
Sore Throat/Pain	8	6	NIL
Cough	7	4	NIL
Dyspnoea	NIL	NIL	NIL
Chest pain	NIL	NIL	NIL
Bleeding	NIL	NIL	NIL

Likerts scale of severity of symptoms, Values are expressed as number of patients.

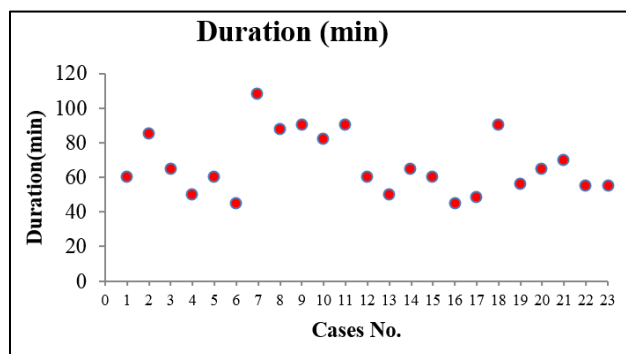


Fig. 1: Duration of the procedure in minutes

Funnel plot of duration of the procedure in minutes in all patients who underwent EBUS-TBNA.

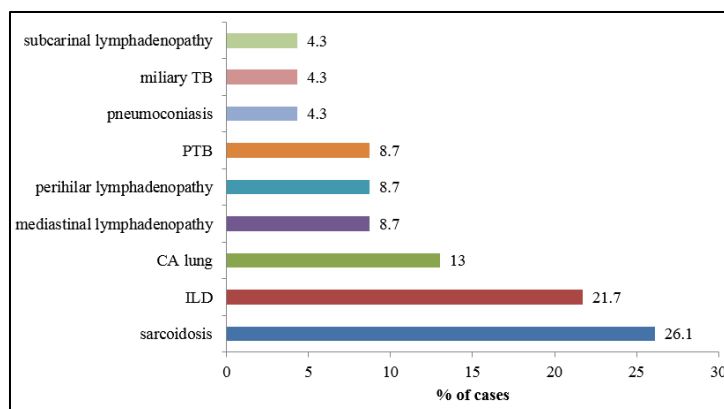


Fig. 2: Indications for EBUS-TBNA

Bar chart showing the preoperative diagnosis and indications in patients undergoing EBUS-TBNA, expressed as percentages (%). TB-Tuberculosis, PTB-Pulmonary Tuberculosis, CA-Carcinoma, ILD-Interstitial Lung Disease.

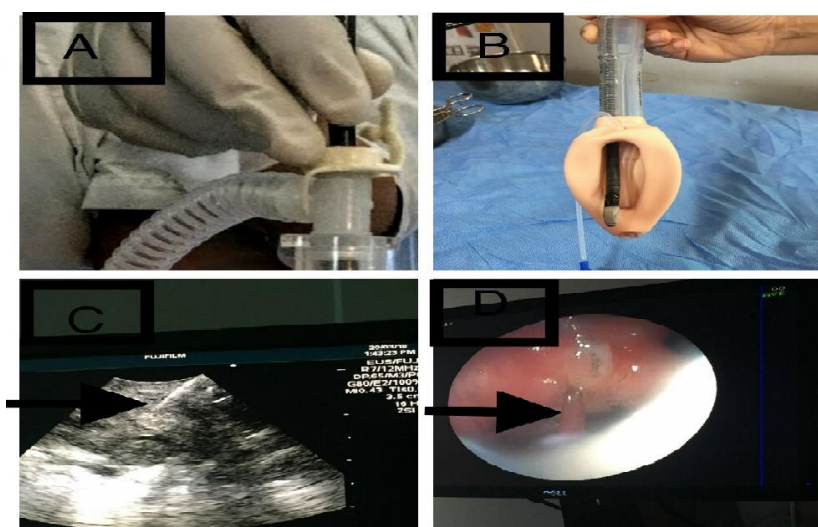


Fig. 1: Insertion of EBUS probe through the catheter mount; B: emergence of EBUS probe through the proseal LMA; C: Ultrasound image of the needle during aspiration; D: Bronchoscopic view of the needle during aspiration

Discussion

As evident by the growing number of publications, EBUS-TBNA is becoming the most exciting and innovative development which has replaced mediastinoscopy as the procedure of choice for diagnosing hilar and mediastinal lesions.⁴ EBUS uses a linear array hybrid fiberoptic scope (developed by Olympus Corporation, Tokyo, Japan) with an optical system that provides an 80° field of view at a 35° forward oblique angle. This scope also incorporates Doppler capabilities which are displayed as monocolour flow mapping to help identify mediastinal bloodvessels. Since, its introduction into respiratory practice, it has become a game changer as it is minimally invasive and provides real time imaging of the surface of the airway, bloodvessels, lung and lymph nodes and allows access to reach difficult areas and smaller lymph nodes.

EBUS-TBNA is the procedure of choice for evaluating neoplasms with diagnostic specificity of 100% and negative predictive value of 92.9%⁵ and is also associated with very high diagnostic sensitivity for inflammatory granulomatous diseases like tuberculosis and sarcoidosis.⁶ Many studies have demonstrated its diagnostic sensitivity equivalent to mediastinoscopy.⁷ American cancer guidelines have embraced EBUS-TBNA in the diagnosis and staging of lung cancer and recommended it as the initial step in staging over mediastinoscopy which helps to decide the operability of the Broncho pulmonary cancers.⁸ EBUS-TBNA has been found to be more effective than chest CT or PET with better sensitivities and specificities.³ The important advantages of this day care procedure are diagnostic accuracy, safety profile and the speed with rapid onsite pathological evaluation. But, facilities which can offer this procedure are still a minority even in developed countries.⁹ In our center it has almost replaced mediastinoscopy which has morbidity and

mortality of 2% and 0.2% respectively.¹⁰ We use EBUS-TBNA for evaluating all mediastinal lymph node irrespective of the etiological diagnosis.

The unique challenges of this procedure for the anesthesiologist are:

1. Shared airway with the bronchoscopist
2. Considering the large size of the ultrasonic bronchoscope with its large internal diameter of 6.9mm, a size 8.5mm endotracheal tube or size 4/5 LMA has to be placed in all patients irrespective of their age and gender. This helps to secure airway and provide adequate ventilation around the scope through the plastic swivel connector (catheter mount) which provides seal around the scope.
3. LMA provides access to higher mediastinal lymph nodes which would otherwise be obscured by endotracheal tube.
4. Intense mucosal contact produced by the large diameter scope causes considerable patient discomfort hence requiring good depth of anesthesia as there is an absolute need to prevent reflex cough and Broncho/laryngospasm.⁶
5. Requirement of total intravenous anesthesia (TIVA) in order to avoid theatre pollution caused by repeated disconnections of the circuit to introduce the scope.

The examination lasts for 30-45 minutes depending on the expertise of the bronchoscopist. In our study we found the average duration of the procedure under general anaesthesia was 67.0±17.6 minutes. As it is relatively new procedure at our institute, the procedural time was a little longer which can be attributed to the initial experiences of pulmonologist. As more pulmonologists are adopting EBUS in their clinical practice, there is a pressing need to understand the factors that enhance the performance and yield of this potentially distressing procedure. Various types of anesthesia have been used like local anesthetic spray to the oropharynx with/without moderate sedation, but the diagnostic yield has been less accurate due to noncooperation of the patients.¹¹ Conscious sedation is also preferred in many centers depending on the case load of patients undergoing the procedure and also availability of qualified anesthesiologist to administer the sedation.^{12,13} But general anesthesia in the operation theatre seems to be the ideal setting as it provides maximum safety and comfort to the patient and the budding pulmonologist with their learning curve and ensures maximum diagnostic yield.¹⁴

The purpose of this article is to describe the appropriate setting and practical aspects of the procedure that may help at the start of a new EBUS-TBNA programme to improve safety, comfort and procedural yield according to operator experience, procedure aim and institutional needs.

In our study, a total of 23 patients underwent EBUS-TBNA under general anaesthesia. We used ProSeal LMA which is a second generation LMA as it

provides adequate oropharyngeal seal with a port for gastric decompression. EBUS probe is integrated with a 7.5MHz ultrasound transducer at the tip which provides maximal sampling flexibility in a single diagnostic procedure. Considering this large outer diameter of the probe (6.9mm at the tip) the bronchoscope fits easily within size 4/ 5 LMA or 8.5mm Endotracheal tube². But the endotracheal tube obscures the vision of the bronchoscope in the subglottic and paratracheal stations. Hence, we preferred use of laryngeal mask airway size 4 for female patients and size 5 for male patients, which was similar to the study done by Douadi in France in which they performed EBUS-TBNA successfully on 41 patients with LMA with minimal complications.¹⁵

In a retrospective study, Yarmus and colleagues compared 163 procedures under Deep sedation (DS) (continuous IV propofol with LMA or ETT) with 116 procedures under moderate sedation (MS) (boluses of Fentanyl and midazolam).¹⁶ The diagnostic yield was higher in DS group with shortened procedure time and a higher number of nodes sampled. In another study by Casal et al, diagnostic yield and complication rates were comparable between general anaesthesia and moderate sedation but 5 patients in MS group did not tolerate the procedure even at maximal pre-established doses and hence converted to general anaesthesia.¹² In another study by Ost and colleagues, deep sedation and general anaesthesia were associated with more lymph nodes sampled per patient.¹⁷ A systematic review by Aswanetmanee et al in 2016 concluded that using moderate sedation has comparable diagnostic yield and safety profile to deep sedation¹⁸ but the decision on the method of sedation for EBUS-TBNA should be individually selected based on operator experience, patient preference and requirement of additional procedures like cryobiopsy, stent placement etc. We have chosen general anaesthesia as the procedure of choice for EBUS in our hospital similar to the study by Yu-Ping Li and colleagues.¹⁹

We used total intravenous anesthesia with propofol infusion which provided patient comfort and better performance of the pulmonologist which has been depicted with better diagnostic yield (100% tissue yield) and no major post procedural complications like haemo-pneumothorax, massive hemoptysis etc. Deep sedation using propofol has been evaluated for its use in bronchoscopy and EBUS. Sarkiss and colleagues described the use of total intravenous anesthesia (TIVA) using propofol and intermittent neuromuscular blockade for the performance of EBUS-TBNA. They performed the procedure on 200 out patients and had no major complications but they published no data regarding the diagnostic yield and/or sample adequacy.²

In our study, there was minimal haemodynamic fluctuations with a MAP variation of <20% from the baseline values. There were no episodes of desaturation. These results were comparable to the

study done by Casal et al, where there was minimal hypotension and no desaturation in general anaesthesia group.¹² None of the patients reported any post procedural "recall" and in addition there were no major post procedural complications in our study.

Propofol infusion works well for these procedures as there may be transient periods of decreased minute ventilation due to the placement of scope inside the LMA/ETT, which could lead to varying delivery of volatile agents if used for maintenance of anaesthesia.² This also provides an added advantage of reducing operation theatre pollution. Clarkson et al concluded that propofol is a useful agent in fiberoptic bronchoscopy with similar efficacy to midazolam but with a faster onset of action and rapid recovery.²⁰ We used propofol for induction and maintenance of anaesthesia, thus patients recovered rapidly with fewer adverse effects. We found that usage of propofol is ideal for outpatient EBUS-TBNA similar to the study by Yu Ping li et al.¹⁹ We found that total intravenous anaesthesia provided optimal condition for bronchoscopist to perform needle aspirations in close proximity to blood vessels in the mediastinum as it obtunds the airway reflexes and prevents patient coughing and body movements.

Limitation

This study has evaluated and described the use of general anaesthesia with laryngeal mask airway for EBUS-TBNA, but it is a single center study with a small sample size. A prospective randomized multicenter study with a large sample size is required to reveal more additional compelling data with objective results and evaluate the clinical efficacy and safety of this procedure.

Conclusion

The implementation of EBUS-TBNA under general anaesthesia with laryngeal mask airway provides great hemodynamic stability and adequate ventilation. It solves the problem of airway management difficulties of sharing a common airway. It demonstrates excellent diagnostic accuracy in addition to providing comfort to the patient and the good examination conditions to the bronchoscopist. Thus, it was possible to establish a secure airway and maintain oxygenation with Laryngeal mask airway during EBUS-TBNA with a good diagnostic yield without any major complications.

Conflict of Interest: None

References

1. Krasnik M, Vilmann P, Larsen SS, Jacobsen GK. Preliminary experience with a new method of endoscopic transbronchial real time ultrasound guided biopsy for diagnosis of mediastinal and hilar lesions. *Thorax*. 2003;58:1083-6.
2. Yasufuku K, Nakajima T, Motoori K, Sekine Y, Shibuya K, Hiroshima K, Fujisawa T. Comparison of Endobronchial ultrasound, positron emission tomography, and CT for lymphnode staging of lung cancer. *Chest*. 2006;130:710-8.
3. Sarkiss M, Kennedy M, Riedel B, Norman P, Morice R, Jilmenez, Eapen G. Anesthesia technique for Endobronchial ultrasound guided transbronchial needle aspiration of mediastinal lymph nodes. *J Cardiothoracic and Vasc Anesth*. 2007;21(6):892-6.
4. Yasufuku K, Pierre A, Darling G, de Perrot m, Waddle T, Johnston M, et al. A prospective controlled trial of Endobronchial ultrasound guided transbronchial needle aspiration compared with mediastinoscopy for mediastinal lymphnode staging of lung cancers. *J Thorac Cardiovasc Surg*. 2011;142:1393-400.
5. Bussy SF, Labarca G, Canals S, Caviedes I, Folch E, Majid A. Diagnostic yield of Endobronchial ultrasound guided transbronchial needle aspiration for mediastinal staging in lung cancer. *J Bras Pneumo*. 2015;41 (3):219-24.
6. Geaka J, Hammerschlag G, Nguyen P, Wallbridge P, Jenkin GA, Korman TM. utility of EBUS-TBNA for diagnosis of mediastinal tuberculous lymphadenitis: A Multicenter Australian Experience. *J Thorac Dis*. 2015;7(3):439-48.
7. Ernst A, Anantham D, Eberhardt R, Krasnik M, Herth FJ. Diagnosis of mediastinal adenopathy-real time endobronchial ultrasound guided needle aspiration versus mediastinoscopy. *J Thorac Oncol*. 2008;3:577-82.
8. Silvestri GA, Gonzalez AV, Jantz MA. Methods for staging non-small cell lung cancer: Diagnosis and management of lung cancer, 3rded: American College of Chest Physicians evidence based practice guidelines. *Chest*. 2013;143:e211S-50S.
9. Zhang J, Ren Y. Endobronchial Ultrasound guided transbronchial needle aspiration: a maturing technique. *J Thorac Dis*. 2014;6(12):1665-7.
10. Steinfort DP, Irving LB. Patient Satisfaction during Endobronchial Ultrasound Guided Transbronchial Needle Aspiration performed under Conscious Sedation. *Respiratory Care*. 2010;55(6):702-6.
11. Vela E, Mases A, Fernandez JL, Vela E, Gallart L. Anesthesia technique and patient and bronchoscopist satisfaction during endobronchial ultrasound guided transbronchial needle aspiration performed under conscious sedation. *European J Anesth (EJA)*. 2011;28:78.
12. Casal RF, Lazarus DR, Kuhl K, Noguera-Gonzalez G, Perusich S, Green LK, et al. Randomized trial of endobronchial ultrasound guided transbronchial needle aspiration under general anaesthesia versus moderate sedation. *Am J Respir Crit Care Med*. 2015;191:796-803.
13. Oztas S, Akturk UA, Alpay LA, Meydan B, Ogun H, Taylan M. A comparison of Propofol-Midazolam and Midazolam Alone for sedation in Endobronchial ultrasound guided transbronchial needle aspiration: A retrospective cohort study. *Clin Respir J*. 2017;11(6):935-41.
14. Canneto Barbara, Ferraroli G, falezza G, Infante MV. Ideal conditions to perform EBUS-TBNA. *J Thorac Dis*. 2017;9(5):S414-17.
15. Douadi Y, Bentayeb H, Malinowski S, Hoguet E, Lecuyer E, Boutemy M. Anesthesia for bronchial echoendoscopy: Experience with the laryngeal mask. *Revue des Maladies Respiratoires*. 2010; 27:37-41.

16. Yarmus LB, Akulian JA, Gilbert C, Mathai SC, Sathiyamoorthy, Sahetya S et al. Comparison of moderate versus deep sedation for Endobronchial Ultrasound needle aspiration. *Ann Am Thorac Soc*. 2013;10(2):121-6.
17. Ost DE, Ernst A, Lei X, Feller-Kopman D, Eapen GA, Kovitz KL, HethFj, Simnoff M; AQUIRE Bronchoscopy Registry. Diagnostic yield of endobronchial ultrasound guided transbronchial needle aspiration: results of the AQUIRE Bronchoscopy Registry. *Chest*. 2011;140:1557-1566.
18. Aswanetmanee P, Limsuwat C, Kabach M, Alraiyes AH, Kheir F. The role of sedation in Endobronchial ultrasound guided transbronchial needle aspiration: a systemic review. *Endosc Ultrasound*. 2016;5(5):300-6.
19. Li YP, Yang J, Duan RW, Jiang GN, Fan J, Zhao RM. Application of modified laryngeal mask airway in Endobronchial ultrasound guided transbronchial needle aspiration. *Acta Medica Mediterranea*. 2013;29:625.
20. Clarkson K, Power CK, O'connell F, Pathmakanthan S, Burke CM. A Comparative evaluation of propofol and midazolam as sedative agents in fiberoptic bronchoscopy. *Chest*. 1993;104(4):1029-31.

How to cite this article: Kedlaya A, Rani R, Devaraj U, Ramachandran P, Maheshwari U. Anaesthetic management of endobronchial ultrasound guided trans bronchial needle aspiration: Our experience with laryngeal mask airway. *Indian J Clin Anaesth*. 2018;5(4):479-485.