



Investigations of the Possible Utility of Wheat Germ Oil versus Diclofenac Sodium Induced Liver Toxicity in Rats

Ahmady Y Ahmed*, Amany M Gad, Ola M Abd El-Raouf

Department of Pharmacology, National Organization for Drug Control and Research, NODCAR, Giza, Egypt

*Corresponding author, e-mail: kamare_ahmady@yahoo.com

Abstract Diclofenac (DICLO) is a non-steroidal anti-inflammatory (NSAID) drug, used as an analgesic and antipyretic agent. Hepatotoxicity is uncommon with NSAIDs but with diclofenac becomes lethal complication. Wheat germ oil (WGO) is a potent antioxidant. Therefore, twenty four male rats were divided into four groups. First group served as control, second group received WGO (270 mg/kg, p.o.). Third group received DICLO (100 mg/kg, IM.), and fourth group received WGO followed by DICLO for 5 days. DICLO elicited a significant increase of liver enzymes, malondialdehyde (MDA), nitric oxide (NO), tumor necrosis factor alpha (TNF- α), and Caspase-3 (Casp-3) levels associated with a significant decline in glutathione reduced (GSH) content and Catalase activity, However, co-administration of WGO with DICLO evoked decrease of liver enzymes, MDA, NO, TNF- α , and Casp-3 levels, increased Catalase activity and GSH content. Eventually, we concluded that, WGO has ability to protect the liver against DICLO hepatotoxicity.

Keywords Diclofenac sodium, Wheat germ oil, Hepatotoxicity, Caspase-3

Introduction

One of the most important discoveries in field of medicine was synthesis of diclofenac (DICLO) which is a phenyl acetic acid derivative and a potent widely prescribed non-steroidal anti-inflammatory painkiller for treatment of human and animals. [1] It is used for management and symptomatic treatment of inflammation, fever associated with diseases or injuries [2]. DICLO is used in rheumatoid arthritis, osteoarthritis, ankylosingspondylitis, ureteric colic and surgical division controlling of dentistry, musculoskeletal, postoperative pain and acute attacks of gout [3-6]. Also, it may be used for curing of fetal developmental problems and prevention of premature birth, [7] antibacterial action through DNA synthesis inhibition [8] and produces its therapeutic effects through prostaglandin synthesis inhibition. [9,10] But shows some strange and life threatening effects like peptic ulceration, gastrointestinal bleeding, hepatotoxicity, renal papillary necrosis, renal failure, bone marrow toxicity and retardation of spermatogenesis [11-13].

DICLO is biotransformed by liver microsomal enzymes into 4-hydroxy diclofenac and other hydroxylated form by what is called glucuronidation and sulfation then excreted through urine and bile [14]. Its metabolites result in synthesis of reactive oxygen species, mitochondrial impairment and NADPH oxidation inducing hepatotoxicity [15]. Liver is the most vital large internal organ in the body, it has a major role in the metabolism and detoxification of xenobiotic [16]. Hepatic damage is related to deviation in these functions [17]. Due to absence of reliable hepatoprotective drugs, herbs play important role in regulation of liver disorders [18]. In recent years, there is an



increasing demand for extraction of antioxidants from natural sources resulting from the potential health hazards of some synthetic antioxidant [19].

Wheat germ is the highest nutritional value of wheat kernel [20]. Wheat germ oil (WGO) is an excellent natural antioxidant derived from wheat germ [21-23]. WGO is an excellent source of and vitamin E, the most powerful natural antioxidant [24] and is also rich in polyunsaturated fatty acids, mainly α -linolenic, linoleic, and oleic acids those may attenuate oxidative stress [25]. Furthermore, WGO is rich in functional phytochemicals, mainly glutathione, flavonoids, sterols and octacosanols [20]. So that, WGO is very important for protection of different body tissues, especially hepatocytes, against oxidative stress and inflammation [26]. Previously, WGO has been attenuated the hepatotoxicity of doxorubicin and Cyclosporin-A [27,28]. Thus, it was very important to investigate the protective activity of WGO against DICLO-induced hepatotoxicity in rats.

Material and Methods

Drugs and chemicals

Diclofenac sodium (Diclophen) ampoules (75 mg/3ml) was purchased from pharco pharmaceutical Co. (Alexandria Egypt). WGO was purchased from Sigma-Aldrich (St. Louis, MO).

Animals

Twenty four adult male albino rats, average body weight 200 ± 20 gm were used for this experiment. Rats were obtained from the breeding Colony of the National Organization for Drug Control and Research (NODCAR) (Giza, Egypt). Rats were housed in stainless-steel cages and kept at standard hygienically environmental and nutritional conditions throughout the experiment, allowed chow diet and water *ad-libitum* and rats were left for 7 days for acclimatization before the beginning of the experiment. The investigation complies with the Guide to Care and Use of experimental Animals. The standard guidelines of NODCAR were followed in handling the experimental animals and this by conforming to the Guide for Care and Use of Laboratory Animals published by the U.S. National Institutes of Health (NIH publication no. 85-23, revised 1996).

Experimental design

Twenty four adult albino rats divided into four equal groups; the first group served as control. The second group received WGO (270 mg/kg b wt./day, p.o.) [26]. Third group received DICLO (100 mg/kg b wt./day, IM) [29] and the fourth group received WGO followed by diclofenac for 5 days. Twenty-four hours after the last treatment, animals were anesthetized, blood samples were prepared for sorting of serum for estimation of liver parameters, Rats were sacrificed by cervical disclosure and liver was dissected, weighed and washed with ice-cold saline. Specimens of each tissue was homogenized in phosphate buffered saline (pH=7.4) to get 10 % homogenate and the obtained aliquots were stored at -80°C until used for biochemical analysis. In addition, a specimen of each liver tissue was fixed in 10% formalin for histopathological examination.

Estimation of liver enzymes (ALT and AST) in serum

The separated serum was used for estimation of alanine aminotransferase (ALT), and aspartate aminotransferase (AST) levels and determined colorimetrically using available commercial kits (Biodiagnostics, Cairo, Egypt).

Estimation of Albumin and total protein in serum

Stanbio Laboratory Kits (Boerne, TX, USA) were utilized for the determination of the serum albumin and the total protein levels.

Estimation of oxidative stress markers

10% homogenate was used for the assessment of oxidative stress markers namely; Malondialdehyde (MDA), reduced glutathione (GSH), nitric oxide (NO) levels and catalase (Cat) activity. All were estimated using a



commercial kits (Biodiagnostic, Cairo, Egypt) in accordance with the manufacturer's instructions. The absorbance was measured using a UV-VIS Spectrophotometer (Shimadzu, Tokyo, Japan).

Estimation of inflammatory marker in liver homogenate

Rat tumor necrosis factor alpha (TNF- α) concentration was measured according to the manufacturers' instructions using the rat ELISA kit obtained from RayBiotech[®] Co. Ltd. (RayBiotech, Inc., USA).

Estimation of apoptotic markers in liver homogenate

Caspase-3 activity was detected in the liver homogenates using ELISA kit (Cusabio Life Science, Inc., China). The manufacturer's instructions were followed precisely and the developed color was measured spectrophotometrically at 450 nm immediately.

Histopathological study

Autopsy samples were taken from the liver of rats in different groups and fixed in 10 % formal saline for twenty hours. Washing with tap water then serial dilutions of alcohol (methyl, ethyl and absolute ethyl) were used for dehydration. Specimens were cleared in xylene and embedded in paraffin at 56 degree in hot air oven for twenty hours. Paraffin bees wax tissue blocks were prepared for sectioning at 4 microns thickness by sledge microtome. The obtained tissue sections were collected on glass slides, deparaffinized and stained by hematoxylin & eosin stain for examination under light electric microscope [30].

Statistical analysis

Data are expressed as Mean \pm SEM. Graphs were prepared using GraphPad Prism and data was subjected to analysis of variance (ANOVA) followed by the Tukey post-hoc test. Values are considered statistically significant at $P < 0.05$.

Results

Effect of daily administration of WGO on liver enzymes (ALT and AST) as well as Albumin and Total protein

Diclofenac sodium injection induced marked hepatic damage proved by the significant elevations in serum ALT & AST activities by 224% and 52%, respectively as compared to control group, while, co-treatment with WGO abolished this elevation by 67% and 24%, respectively as compared to DICLO group. However, injection of diclofenac sodium disrupted the synthetic functions of the liver, as evidenced by the significant reduction of serum albumin and total protein levels by 31% and 35%, respectively as compared to control group. On the other hand, WGO co-treatment counteracted this reduction **Table (1)**.

Table 1: Effect of WGO on liver enzymes (ALT and AST) as well as Albumin and Total protein

Groups	ALT (U/L)	AST (U/L)	Albumin (g/ dl)	Total protein (g/ dl)
Control	32.13 \pm 2.8	35.50 \pm 4.97	4.40 \pm 0.15	6.21 \pm 0.41
Wheat Germ Oil (WGO)	33.06 \pm 2.9	45.00 \pm 0.40	3.60 \pm 0.06	5.74 \pm 0.11
Diclofenac (DICLO)	110.6 \pm 4.8 ^a	54.50 \pm 0.50 ^a	3.02 \pm 0.04 ^a	3.40 \pm 0.10 ^a
WGO +DICLO	35.78 \pm 1.7 ^b	40.75 \pm 0.94 ^b	4.06 \pm 0.22 ^b	6.54 \pm 0.29 ^b

Data represents mean of 6 rats \pm SEM.

^{ab}Significant from control and DICLO, respectively. Statistical analysis was carried out by one-way ANOVA followed by Tukey post-hoc test. Values are considered statistically significant at $P < 0.05$.

Effect of daily administration of WGO on oxidative stress parameters

Diclofenac sodium injection induced a significant decrease in GSH content (51%) and catalase activity 43%, respectively, associated with a significant elevation of MDA 462% and nitrite/nitrate (NOx) levels 345%,



respectively, as compared to control group. Treatment of animals with WGO concomitantly with Diclofenac sodium afforded a significant protection against DICLO intoxication as it could restore the normal GSH level and catalase activity. Besides, it reduced MDA level and returned NOx level to nearly normal values (Figure 1a-1D).

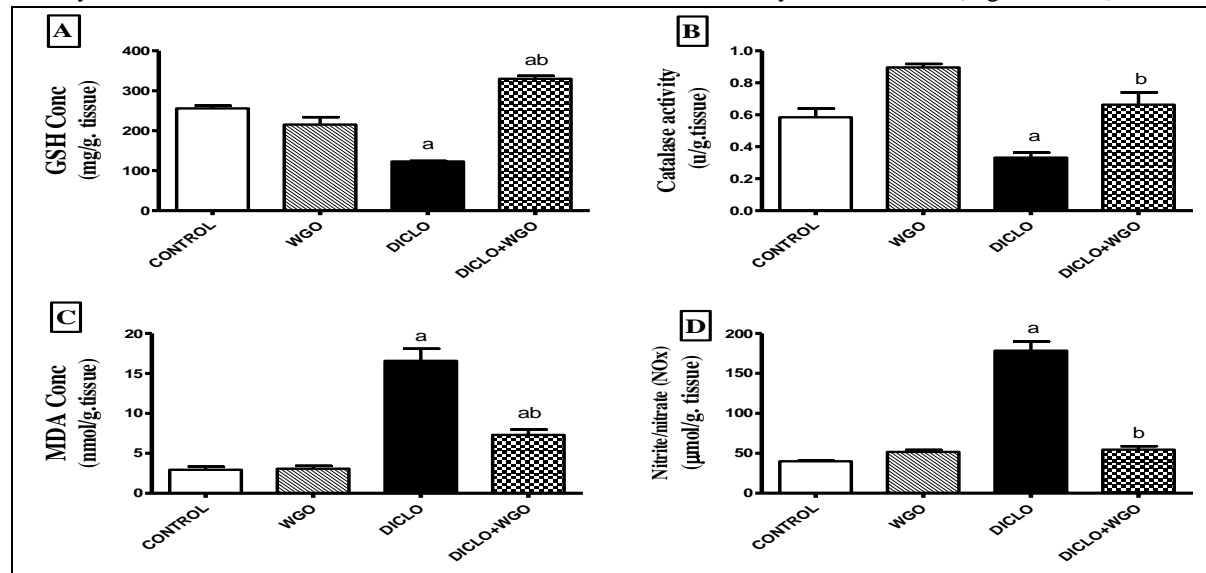


Figure 1A-1D: Effect of daily administration of WGO on oxidative stress parameters

Data represents mean of 6 rats \pm S.E.M. ^{ab} Significant from control and DICLO, respectively. Statistical analysis was carried out by one-way ANOVA followed by Tukeypost-hoc test. Values are considered statistically significant at $P < 0.05$.

Effect of daily administration of WGO on hepatic tumor necrosis factor alpha (TNF- α)

Administration of diclofenac sodium (100 mg/kg, I.M) for) significantly increased TNF- α level by (226%) as compared to control group. However, administration of WGO concomitantly with DICLO significantly decreased TNF- α level by (65%) as compared to DICLO group (Figure 2).

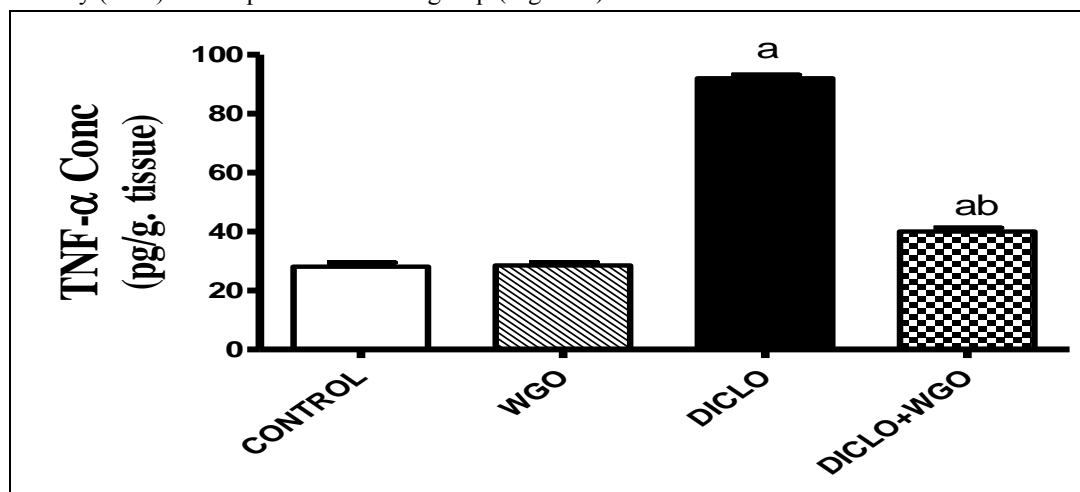


Figure 2: Effect of daily administration of WGO on hepatic tumor necrosis factor alpha (TNF- α)

Effect of daily administration of WGO on hepatic caspase -3 (Casp-3)

Administration of diclofenac sodium (100 mg/kg, I.M) significantly increased caspase-3 level by 282% as compared to control group. However, administration of WGO concomitantly with DICLO significantly decreased caspase-3 level by (51%) as compared to DICLO group (Figure 3).



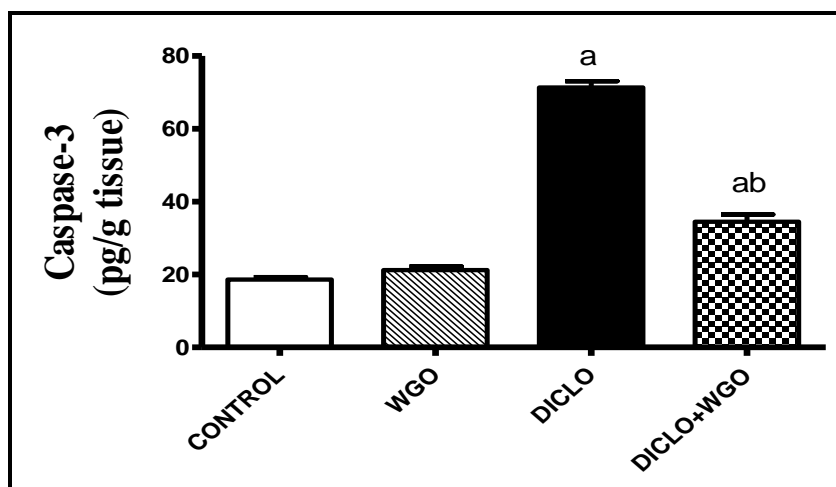


Figure 3: Effect of daily administration of WGO on hepatic caspase-3 (Casp-3)

Data represents mean of 6 rats \pm S.E.M. ^{ab} Significant from control and DICLO, respectively. Statistical analysis was carried out by one-way ANOVA followed by Tukeypost-hoc test. Values are considered statistically significant at $P < 0.05$.

Histopathological Examination by H&E

Liver sections of rat from control group showed normal histological structure of hepatic lobule and no pathological changes, liver of rats from WGO group elicited typical histological structure of hepatic lobule, while liver sections of rats treated with DICLO evoked cytoplasmic vacuolization of hepatocytes and fibroplasia in the portal triad as well as the liver pieces of rats treated with WGO and DICLO illustrated slight degeneration of some hepatocytes (H & E X 400) (Figure 4).

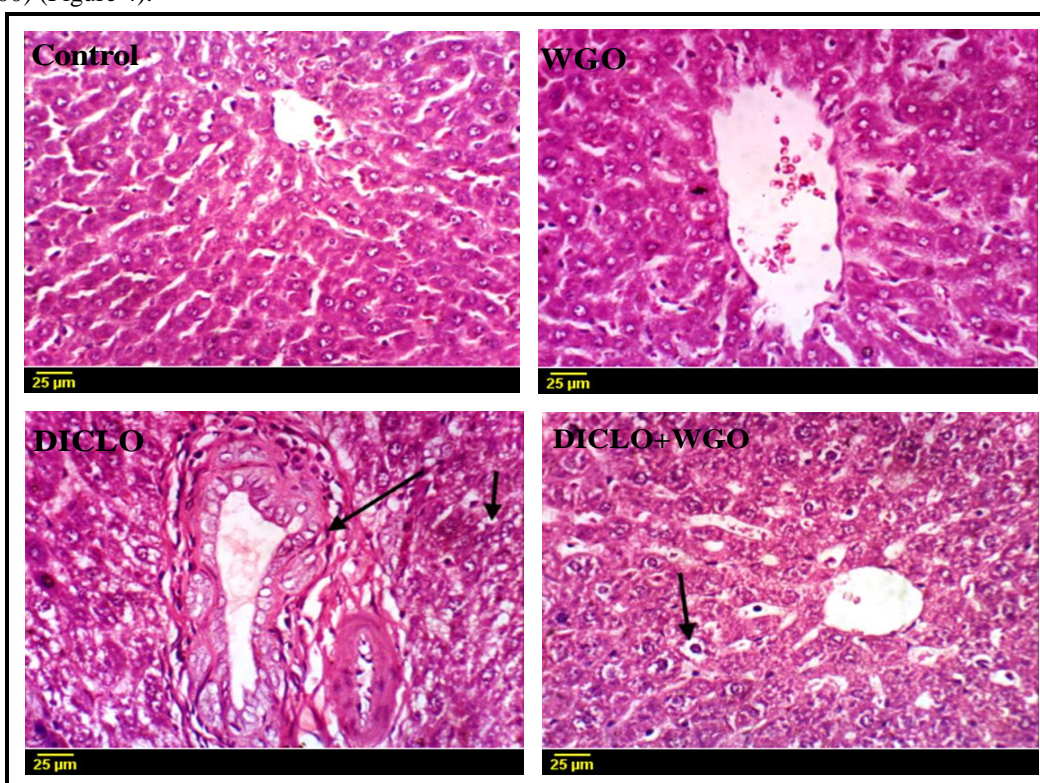


Figure 4: Representative photomicrographs of liver sections stained with H&E (X400)



Discussion

Liver is the main machine of diclofenac biotransformation. Metabolites of diclofenac are excreted in the bile (35%) [30], therefore, it is hepatotoxicant [31]. 4-OH hydroxy 3 diclofenac, 5-OH hydroxy 4 diclofenac and 5-OH hydroxy 6 diclofenac are the main diclofenac metabolites responsible for hepatotoxicity [32]. Previous studies evoked that diclofenac produces reactive oxygen species (ROS) in the liver resulting in oxidative stress followed by cell damage [33]. Diclofenac causes cellular damages including hepatic degenerative changes [34,35]. Significant alterations in the biochemical parameters used as indicators for toxicity. In this investigation, administration of diclofenac sodium induced a significant increase in ALT, AST, MDA, NO, and Caspase-expression associated with a significant decrease in total protein and albumin, furthermore, a decline of GSH and Catalase contents, these results were confirmed by histopathological picture and in line with the research of [36-46] who reported that, elevations of ALT, AST and ALT/AST as well as inhibition of albumin and total protein are coincide with severity of hepatocellular damages due to aminotransferases are intracellular enzymes so, hepatocellular rupture results in escaping of these enzymes into the circulation which agreed with the results of our study. The increase in MDA may result from lipid peroxidation induced by diclofenac such as result reported by [44] who showed that Cyclosporins-A lead to changes in the permeability of cell membrane. Also, [41] showed that, diclofenac sodium induced a significant reduction in reduced glutathione (GSH) levels and increase in malondialdehyde (MDA) content in liver homogenates similar to our findings. Hepatic damage has been elicited to be associated with induction of the pro-oxidant enzyme iNOS [47] producing NO. Our histopathological observations resemble to those studied by [41,47] who evoked alterations in the hepatic histological picture.

Herbal extractions are being increasingly used to overcome a variety of liver diseases [49]. Wheat germ oil has the ability for reducing oxidative stress and improves metabolism of lipid.[50] Moreover, administration of WGO lead to a rapid increase in vitamin E content in the liver and results in strong antioxidant protection to hepatic tissues [51,52, 21]. may be due to WGO is the richest natural dietary source of α -Tocopherol which is a potent oxidant collector preventing the aggregation of ROS in biological membranes of cell. Also, the biological activity of natural α -Tocopherol is more potent than synthetic one [53]. In present investigation wheat germ oil decreased AST, ALT, MDA, NO, and Casp-3 as well as increased GSH, Cat and improved the histopathological picture agreed with [26] who reported that, wheat germ oil reduces MDA level. Similar to [50] elicited that, administration of α -Tocopherol resulted in a decline in MDA, TNF- α , and IL-6 levels as well as elevation of GST, SOD and CAT as well as GSH concentration comparing with endotoxin group, due to α -Tocopherol is a lipophilic antioxidant protecting hepatocytes as stated by [51,54] who showed the supportive role of α -Tocopherol versus lipid peroxidation in membranes of mitochondria. WGO stimulates the tocopherol-mediated redox system inhibiting Prostaglandins synthesis, which is responsible for peroxidation of lipid [55].

Conclusion

Our observations elicited that, WGO was effective in ameliorating the histopathological alterations and Casp-3 were caused by diclofenac sodium in the liver as mentioned by [56] giving to us clear vision about protection effect of WGO.

Acknowledgment

The author would like to thank Prof. Dr. Kawkab A. Ahmed (Pathology Department, Faculty of Veterinary Medicine, Cairo University, Cairo, Egypt) for her assistance in the histopathological examinations.

References

- [1]. Fries, J.F. (1992). Assessing and understanding patient risk. *Sc and J Rheumatol.*, 92:21-24.
- [2]. George, L.W. (2003). Pain Control in Food Animals. In: *Recent Advances in Anesthetic Management of Large Domestic Animals*, E.P. Steffey (Ed.) Publisher: International Veterinary Information Service (www.ivis.org), Ithaca, New York, USA.



- [3]. Katzung, B.G. (1998). Basic and clinical pharmacology, 7th ed., Connecticut; Appleton and Lange; 587-602.
- [4]. Bhagat, H., Malhotra, K., Tyagi, C., Gangwar, N. & Pal, N., (2003). Evaluation of preoperative rectal diclofenac for perioperative analgesia in ENT surgery. *Indian J Anesthesia*, 47: 463- 466.
- [5]. Morgan G. (1999). Beneficial effects of NSAIDS in the gastrointestinal tract. *Eur J GastroenterolHepatol.*, 11: 393-400.
- [6]. Ahmad, I., Qureshi, T. A., Khan, F. A., Mughal, S. A.K., Sadique, U., Shah, Z., Khan, S. & Hassan, Z. U. (2012). Evaluation of biochemical effects of diclofenac sodium in goats. *The Journal of Animal and Plant Sciences*, 22 (2 Suppl.), 1-4
- [7]. Isen, A. G., Alparslan, G.K., Meral, N.C., Ekrem, Ü.E., Nermin, K. & Osman, G.K. (2003). Histopathologic changes in liver and renal tissues induced by different doses of diclofenac sodium in rats. *Turk J Vet Anim Sci.*, 27: 1131-1140.
- [8]. Dutta, N.K., Annadurai, K. S., Mazumdar, S.G., Dastidar, J. E., Kristiansen, J., Molnar, M. M. & Amara, L. (2000). The anti-bacterial action of diclofenac shown by inhibition of DNA synthesis. *International Journal Antimicrobial Agents*, 14(3): 249-251.
- [9]. Gilman, A. G.; Goodman, L. S. & Gilman, A. (1990). *The Pharmacological Basis of Therapeutics*. 6th Edition Macmillian Pub. Co. Inc. New York
- [10]. Klaassen, C. D. (2001). *Casarett and Doull's Toxicology: the Basic Science of Poison*. 6th Eds The McGraw-Hill Companies Inc. New York.
- [11]. Steitiea, F.M., Ali, S.S. & Muhamed, S.A. (1994). Morphological changes of the mouse testis under the influence of diclofenac sodium (Voltaren). A light and electron microscopic study. *Egyptian Journal of Anatomy*, 7: 387-340.
- [12]. Menassé, R., Hedwall, P.R., Kraetz, J., Pericin, C., Riesterer, L., Sallmann, A., Ziel, R. & Jaques, R. R. (1978). Pharmacological properties of Diclofenac sodium and its metabolites. *Scandinavian Journal of Rheumatol Suppl.*, 22: 5-16.
- [13]. Schapira, D., Bassan, L., Nahir, A.M. & Scharf, Y. (1986). Diclofenac-induced Hepatotoxicity, *Postgraduate Medical Journal*, 62, 63-65.
- [14]. Mascher, H. (1996). Comparative metabolism of the nonsteroidal anti-inflammatory drug, diclofenac, in the rat, monkey and human. *Drug Metab Dispos*, 24: 969-997.
- [15]. O'connor, N.; Dargan, P.I. & Jones, A.L. (2003). "Hepatocellular damage from nonsteroidal anti-inflammatory drugs." *J Med*. 96. 787-791.
- [16]. Ohioha, M.Q., Emeka, I.E., Lotanna, A.D. & Ogechukwu, U.B. (2013). Hepatoprotective and anti-hepatotoxic activity of aqueous leaf extract of *Tacazzeabarberi* against carbon tetrachloride induced hepatotoxicity in albino rats. *Int. Res. J. Pharm.*, 4(9): 61–65.
- [17]. Rao, G.M.M., Rao, C.V., Pushpangadan, P. & Shirwaikar, A. (2006). Hepatoprotective effects of rubiadin, a major constituent of *Rubiocordifolia* Linn. *J Ethnopharmacol*, 103(3): 484-490.
- [18]. Ambati, S., Jyothi, V. & Jyothi, A.V. (2010). Hepatoprotective activity-A review. *Int J Pharm Technol*, 2(3): 354-366.
- [19]. Mahmoud, A., Mohdaly, A. A. & Elneairy, A. A. (2015). Wheat Germ: An Overview on Nutritional Value, Antioxidant Potential and Antibacterial Characteristics *Food and Nutrition Sciences*, 5(6):265-277.
- [20]. Zhu, K., Zhou, H.M. & Qian, H.F. (2006). Proteins extracted from defatted wheat germ, nutritional and structural properties. *Cereal Chem.*, 83:69–75.
- [21]. Leenhardt, F., Fardet, A., Lyan, B., Gueux, E., Rock, E., Mazur, A., Chanliaud, E., Demigne, C. & Remesy, C.(2008). Wheat germ supplementation of a low vitamin E diet in rats affords effective antioxidant protection in tissues. *Am CollNutr.*, 27(2):222-228.
- [22]. Hassanein, M.M. & Abedel-Razek, A.G.(2009). Chromatographic quantitation of some bioactive minor components in oils of wheat germ and grape seeds produced as by-products. *J. Oleo Sci.*, 58, 227-233.



- [23]. Alessandri, J.M., Extier, A., AlGubory, K.H., Harbeby, E., Lallemand, M.S., Linard, A., Laviolle, M. & Guesnet, P. (2011). Influence of gender on DHA synthesis: The response of rat liver to low dietary α -linolenic acid evidences higher O₃ D4-desaturation index in females, *Eur. J. Nutr.*.doi.,10.1007/s00394-011-0208-1.
- [24]. Ohkatsu, Y., Kajiyama, T. & Arai, Y.(2001).Antioxidant activities of tocopherols. *Polym Degrad Stabil.*, 72:303-311.
- [25]. Lessandri, C., Pignatelli, P., Loffredo, L., Del Ben, M., Carneyale, R., Perrone, A., Ferro, D., Angelico, F. & Violi, F. (2006). α -linolenic acid-rich wheat germ oil decreases oxidative stress and CD40 ligand in patients with mild hypercholesterolemia. *Arterioscler Thromb VascBiol.*, 26:2577–2578.
- [26]. Samy, A.H., Abdel-Aal, S.A. & Elghwab, A.I.M. (2014). Biochemical role of wheat germ oil on biomarkers of oxidative stress and inflammatory response in a rat model of endotoxemia, *Benha Vet Med J.*, 27(2):157-167.
- [27]. Abdallah, M. S. (2015). Protective Effects of Wheat Germ Oil on Doxorubicin-Induced Hepatotoxicity in Male Mice. *International Journal of Research Studies in Biosciences (IJRSB)* 3(6):21-25.
- [28]. El-Sayed, A. (2015). Molecular mechanisms of the protective role of wheat germ oil against cyclosporin A-induced hepatotoxicity in rats, *Pharmaceutical Biology*, 53(9):1311-1317.
- [29]. Ahmed, Y.A., Gad, M.A. & Abd El-Raouf, M.O. (2017). Curcumin ameliorates diclofenac sodium-induced nephrotoxicity in male albino rats. *Journal of biochemical and molecular toxicology*, 31, e21951.
- [30]. Vane, J.R. & Botting, R.M. (1996). Mechanism of action of anti-inflammatory drugs. *Scandinavian Journal of Rheumatology - Supplement*, 102: 9-21.
- [31]. Castel, J.V., Gomez-Lechon, M.J., Ponsoda, X. & Bort, R. (1997).The use of cultured hepatocytes to investigate the mechanism of drug hepatotoxicity. *Cell Biology and Toxicology*, 13: 331-338.
- [32]. Daly, A.K., Aithal, G.P., Leathart, J.B., Swainsbury, R.A., Dang, T.S. & Day, C.P (2007). Genetic susceptibility to diclofenac-induced hepatotoxicity: contribution of UGT2B7, CYP2C8 and ABCC2 genotypes. *Gastroenterology*, 132: 272-281.
- [33]. Patel, N., Joseph, C., Corcoran, G.B. & Ray, S.D. (2010). Silymarin modulates doxorubicin-induced oxidative stress, BclxL and p53 expression while preventing apoptotic and necrotic cell death in the liver. *Toxicol Appl Pharmacol.* 2010; 245(2):143-152.
- [34]. Lo, V., Meadows, S.E. & Saseen, J.(2006). When should COX-2 selective NSAIDs be used for osteoarthritis and rheumatoid arthritis? *J. Fam. Pract.*, 55:260-262.
- [35]. Ong, C.K.S., Lirk, P., Tan, C.H. & Seymour, R. A. (2007). An evidence-based update on non-steroidal anti-inflammatory drugs. *Clin. Med. Res.* 5(1):19-34.
- [36]. Dufour, D.R., Lott, J.A., Nolte, F.S., Gretch, D.R., Koff, R.S. & Seeff, L. B. (2000). Diagnosis and monitoring of hepatic injury: I. Performance characteristics of laboratory tests. *ClinChem* 46: 2027-2049.
- [37]. Manov, I., Motanis, H., Frumin, I. & Iancu, T.C. (2006). Hepatotoxicity of anti-inflammatory and analgesic drugs: Ultrastructural aspects. *ActaPharmacol Sin.*, 27: 259-272.
- [38]. Ahmed, I., Qureshi, T.A., Khan, F.A., Mughal, S.A.K., Sadique, U., Shah, Z., Khan, S. & Hassan, Z.U. (2012). Evaluation of Biochemical effects of diclofenac sodium in goats. *J. Anim. Plant Sci.*, 22(2)
- [39]. Wamutu, S., Francque, S., Chatterjee, S., Musisi, E., Muyomya, G.W., Van Marek, E., Bimenya, G.S. & Michielsen, P. (2012). Vitamin C as well as beta- Carotene attenuates experimental liver fibrosis after intoxication with carbon tetrachloride in rats. *Int. J. Biol. Chem. Sci.*, 6(2):559-571.
- [40]. Basavraj, S.T., Fefar, D.T., Prajapati, K.S., Jivani, B.M., Thakor, K.B., Patel, J.H., Ghodasara, D.J., Joshi, B.P. & Undhad, V.V. (2012). Haematobiochemical alterations induced by diclofenac sodium toxicity in Swiss albino mice. *Vet. World*, 5(7):417-419.
- [41]. El-Maddawy, Z.K.H. & El-Ashmawy, I.M. (2013). Hepato-Renal and Haematological effects of diclofenac sodium in rats. *Global J. Pharmacol.*, 7(2): 123-132.



- [42]. Taha, N.R., Rabah, S.O., Shaker, S.A. & Mograby, M.M. (2015). Effect of *Moringa oleifera* Leaves on Diclofenac Sodium Induced Hepatic Injury in Albino Rats: Ultrastructural and Immunohistochemical Studies. *J Cytol Histol*, 6(2):315-322.
- [43]. Kaya, H., Koc, A., Sogut, S., Duru, M., Yilmaz, H.R., Uz, E. & Durgut, R. (2008). The protective effect of N-acetylcysteine against cyclosporine A-induced hepatotoxicity in rats. *J Appl Toxicol* 28:15–20.
- [44]. Pari, L. & Sivasankari, R. (2008). Effect of ellagic acid on cyclosporine A-induced oxidative damage in the liver of rats. *Fund Clin Pharmacol* 22:395–401.
- [45]. Galan, M.V., Gordon, S.C. & Silverman, A.L. (2001). “Celecoxib-induced cholestatic hepatitis. *Annals of Internal Medicine*, 134(3):254.
- [46]. Rostom, A., Goldkind, L. & Laine, L. (2005). “Nonsteroidal anti-inflammatory drugs and hepatic toxicity: A systematic review of randomized controlled trials in arthritis patients,” *Clinical Gastroenterology and Hepatology*, 3(5):489-498.
- [47]. Navarro, J., Redondo, M., Zaragoza, C., Alvarez, A., Fernandez, A.P., Leon, E., Rodrigo, J, Lamas, S. (2003). Role of peroxynitrite in endothelial damage mediated by cyclosporine A. *Free Radic Biol Med* 42:394-403.
- [48]. Aydin, G., Gokcimen, A., Cicek, E. & Gokalp, O. (2003). Histopathologic changes in liver and renal tissue induced by different doses in liver and renal tissue induced by different doses of diclofenac sodium in rats. *Turk J Vet Ani Sci.*, 27: 1131-1140.
- [49]. Chattopadhyay, R.R. (2003). Possible mechanism of hepatoprotective activity of *Azadirachta indica* leaf extract: part II. *J Ethnopharmacol* 89: 217-219.
- [50]. Singh, D.K., Li, L., Porter, T.D. (2006). Policosanol inhibits cholesterol synthesis in hepatoma cells by activation of AMP-kinase. *J. Pharmacol. Exp. Ther.*, 318(3): 1020-1026.
- [51]. Navarro, F., Navas, P., Burgess, J.R., Bello, R.I., Cabo, R. & Arroyo, A. (1998). Vitamin E and selenium deficiency induces expression of the ubiquinone-dependent antioxidant system at the plasma membrane. *FASEB J.* 12: 1665–1673.
- [52]. Shurpalekar, S.R. & Rao, H.P. (1977). Wheat germ. *Advances in Food Research*, 23:187-304.
- [53]. Traber, M. G. & Atkinson, J. (2007). Vitamin E, antioxidant and nothing more. *Free Radic. Biol.*, 43(1):4-15.
- [54]. Zhang, J.G., Nicholls-Grzemeski, F.A., Tirmenstein, M.A. & Fariss, M.W. (2001). α -Tocopherol succinate protects hepatocytes against the toxic effect of reactive oxygen species generated at mitochondrial complexes I and III by alkylating agents. *J. Chem. Biol. Interact.*, 138: 267-284.
- [55]. Chang, C.L., Coudron, T.A., Goodman, C. & Stanley, D. J. (2010). Wheat germ oil in larval diet influences gene expression in adult oriental fruit fly. *Insect Physiol.*, 56(4):356-365.
- [56]. Slauson, D.O., Cooper, B.J., Slauson, D.O. & Cooper, B.J. (2002). *Mechanisms of disease: a textbook of comparative general pathology*. 3rd Edn., Mosby, St. Louis, MO., USA.

