



## Effect of Feed and Feeding Strategies on Oocytes Development in *Labeo rohita*: A Histomorphological Study

Ashfauq Farooq Aga<sup>1\*</sup>, Asha Dhawan<sup>1</sup>, Neelam Bansal<sup>2</sup> and Devendra Pathak<sup>2</sup>

<sup>1</sup>Department of Aquaculture, College of Fisheries, GADVASU, Ludhiana, INDIA

<sup>2</sup>Department of Veterinary Anatomy, COVS, GADVASU, Ludhiana, INDIA

\*Corresponding author: AF Aga; Email: agaashfauq@gmail.com

Received: 07 Aug., 2016

Revised: 18 Dec., 2016

Accepted: 05 Jan., 2016

### ABSTRACT

The present study was conducted to study the effect of different diets and feeding strategies on the development of oocytes during the pre spawning and post spawning period in *Labeo rohita*. The study showed the presence of oocytes in different developmental stages viz., primary growth phase, secondary growth phase, maturation phase, post ovulatory phase and atretic oocytes during both pre spawning and post spawning period. The primary growth phase comprised of oogonia stage, chromatin nucleolus stage, early perinucleolar stage and late perinucleolar stage, whereas, the secondary growth phase was differentiated as cortical alveolus stage, early vitellogenic stage and late vitellogenic stage, and early and late types of atresia. The percentage occurrence (92-28 %) of these different stages varied during pre spawning and post spawning period respectively. The study revealed that (65%) of the oocytes were in the vitellogenic and maturation phases during pre spawning period, while as perinuclear stage and atretic oocytes (27.6%) were seen during post spawning period. All the developmental stages showed more active oocytes in the ovaries of fish fed with vitamins and minerals indicating that diet influences the reproductive efficiency of the fish

**Keywords:** Feeding strategies, histology, *Labeo rohita*, Oocytes, Ovary

The reproductive potential of fish is influenced by the ecological and nutritional factors. In fish oogenesis starts from proliferation of oogonia to form mature oocytes ultimately leading to ovulation. During this process, the stages of development, starting from oogonia upto the maturation, due to the accumulation of yolk granules which are formed under the influence of steroid hormones testosterone (T), estradiol (E2) and progesterone(P). Studies have been conducted on the histology of ovary of Sand whiting fish (Jayasankar and Alagarwami, 1994), Dusky grouper (Mandich *et al.*, 2002), Yellowfin seabream (Abou-Seedo *et al.*, 2003), Twaite shad (Pina *et al.*, 2003), the Sword fish (Corriero *et al.*, 2004), Zebra fish (Deniz Koc *et al.*, 2008) and Nile tilapia (El-Saba *et al.*, 2013), but scanty information is available on the ovarian histology of *Labeo rohita* (Lone and Hussain, 2009). So the present study was taken up to establish the impact of different feeds and feeding strategies on the developmental stages of oocytes in *Labeo rohita* during its pre spawning and post spawning periods.

### MATERIALS AND METHODS

The present study was conducted at College of fisheries, GADVASU, Ludhiana. The experimental trial comprised of eight treatments (T<sub>1</sub> to T<sub>8</sub>) with three variables viz. two supplementary feeds (D<sub>1</sub> and D<sub>2</sub>), two feeding rates (R<sub>1</sub> and R<sub>2</sub>) and two feeding frequencies (F<sub>1</sub> and F<sub>2</sub>). The detail of the diets and treatments is given in table 1 and 2. The experiment was carried out in 80 m<sup>2</sup> outdoor cemented tanks with 7.62-8.89 cm water level. Soil layer (12.7 cm) was spread at the bottom of each tank to boost the detritus food chain. All the tanks were manured with cow dung @ 160 kg tank<sup>-1</sup> year<sup>-1</sup>. Bore well water was used to fill the experimental tanks.

### Stocking of fish

Each tank was stocked with *Labeo rohita* yearlings @ 1,000 kg ha<sup>-1</sup> with an average total body length of 25-35 cm and body weight of 450-500g. in the month of April, 2014. The mature male and female fishes were differentiated

on the basis of size and weight (as females are usually larger in size), smoothness of pectoral fin in female fish, with soft and bulged abdomen and a swollen reddish vent in females (Thomas *et al.*, 2003). All the treatments (T<sub>1</sub> to T<sub>8</sub>) were carried out in duplicate. Fish were fed with dough everyday at fixed corners of the pond, throughout the culture period of eight months (April to November).

Observations were recorded during pre spawning and post spawning in the months of July and September respectively. The ovaries were collected and fixed in 10% neutral buffered formalin (10% NBF). The tissue samples were processed as per routine acetone benzene technique (Luna, 1968). The paraffin blocks were prepared, sections of 5 µm thickness were obtained on clean glass slides and these sections were stained with hematoxylin and eosin and periodic acid Schiff stains for detailed histological studies. The observations were recorded and the required photomicrographs were taken with the Nikon microscope with digital camera.

**Table 1: Percent composition of experimental diets**

Ingredients	Diet 1 (D <sub>1</sub> )	Diet 2 (D <sub>2</sub> )
Rice bran	30	30
Groundnut oil cake	50	50
Fish meal	20	18
Vitamin-mineral mixture*	—	2

\*Agrimin forte, Virbac Animal Health Pvt. Ltd, Mumbai, India. Composition: the nutritional value of vitamin mineral mixture per kg was: Vitamin A - 625000 IU; Vitamin D3 - 62500 IU; Vitamin E - 250 mg; Nicotinamide - 1g; Copper - 312 mg; Cobalt - 45 mg; Iron - 1.5 g; Zinc - 2.13 g; Iodine - 156 mg; Selenium - 10 mg; Magnesium - 6 g; Manganese - 1.2 g; Potassium - 48.05 mg; Calcium - 247.34 g; Phosphorus - 114.66 g; Sulphur - 12.2 g

**Table 2: Detail of different treatments**

Treatments	T <sub>1</sub>	T <sub>2</sub>	T <sub>3</sub>	T <sub>4</sub>	T <sub>5</sub>	T <sub>6</sub>	T <sub>7</sub>	T <sub>8</sub>
Diet	D <sub>1</sub>	D <sub>1</sub>	D <sub>1</sub>	D <sub>1</sub>	D <sub>2</sub>	D <sub>2</sub>	D <sub>2</sub>	D <sub>2</sub>
Feeding Rate (% BW)	3%	3%	4%	4%	3%	3%	4%	4%
Feeding frequency (per day)	Once	Twice	Once	Twice	Once	Twice	Once	Twice

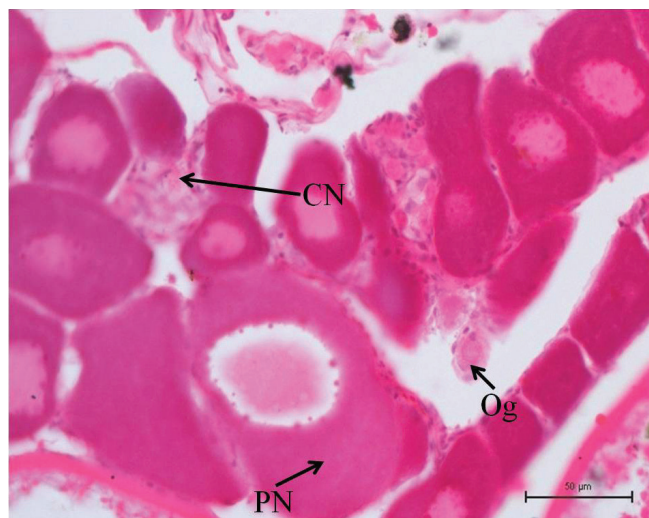
## RESULTS AND DISCUSSION

Based on the histomorphological observations, the different stages of *Labeo rohita* oocytes were seen in primary growth phase, secondary growth phase, maturation phase, post ovulatory phase and atretic oocytes. The primary growth phase included oogonia stage, chromatin nucleolus stage, early perinucleolar stage and late perinucleolar stage, whereas the secondary growth phase was subdivided into cortical alveolus stage, early vitellogenic stage and late vitellogenic stage. Two types of atresia was reported as early and late atresia. Similar classification of developmental stages in different fish species have already been described in *Sand whiting* fish (Jayasankar and Alagaraswami, 1994), *Dusky grouper* (Mandich *et al.*, 2002), *Yellowfin seabream* (Abou-Seedo *et al.*, 2003), *Twaite shad* (Pina *et al.*, 2003), the *Sword fish* (Corriero *et al.*, 2004), *Zebra fish* (Deniz Koc *et al.*, 2008), *Labeo rohita* (Lone and Hussain, 2009) and *Nile tilapia* (El-Saba *et al.*, 2013).

### Primary Growth Stage

#### Oogonia stage

Oogonia were located as cluster of few cells present in interstitial tissue of ovigerous lamellae. These oogonia were roughly small, spherical cells having large basophilic nucleoli, with a prominent nucleolus and contained scanty ooplasm (Fig. 1). According to the previous theories, it is assumed that the oogonia may be derived from the germinal epithelial cells (Bara, 1960; Arruda, 1988) or transformed from the certain cells from the empty follicles of previous spawning (Yamamoto, 1956). More oogonia were found during pre spawning period in T<sub>2</sub> and the spent ovaries in T<sub>4</sub> and T<sub>6</sub>, probably due to the effect of higher feeding frequency.



**Fig. 1:** Section of fish ovary in primary growth phase showing oogonia (Og), chromatin nucleolus (CN) and perinucleolar stage (PN). [H&E, 40 $\times$ ]

#### Chromatin nucleolus stage

The nucleus was mostly Oocytes of this stage were small rounded cells with large nucleus and thin cytoplasm (Fig. 1). lightly stained and acentric in position. The darkly stained nucleoli were distributed throughout the nucleolus. The ooplasm was homogenous and darkly stained showing basophilic reaction. Similar findings have been reported in the ovaries of Sand whiting fish (Jayasankar and Alagaraswami, 1994), Dusky grouper (Mandich *et al.*, 2002), Yellowfin seabream (Abou -Seedo *et al.*, 2003), Twaite shad (Pina *et al.*, 2003), the Sword fish (Corriero *et al.*, 2004), Zebra fish (Deniz Koc *et al.*, 2008) and Nile tilapia (El-Saba *et al.*, 2013). This stage was found to be more during pre spawning period in T<sub>4</sub> and in the spent ovaries of and T<sub>8</sub> treatments wherein fish growth increased by both the diets with highest feeding rate (4% B W) and frequency (twice a day). These differences may be due to various ecological conditions.

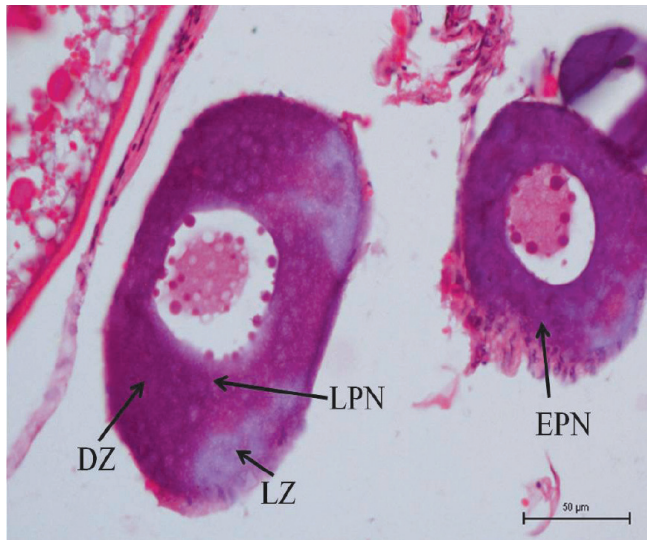
#### Early perinucleolar stage

This stage was characterized by an increase in the size of oocyte with darkly basophilic homogenous ooplasm and slightly basophilic nucleus. These oocytes had large nucleus and small amount of cytoplasm with increased nucleus to cytoplasm ratio. The nucleoli were strongly basophilic and were dispersed throughout the nucleoplasm. The number of nucleoli also increased, which indicated

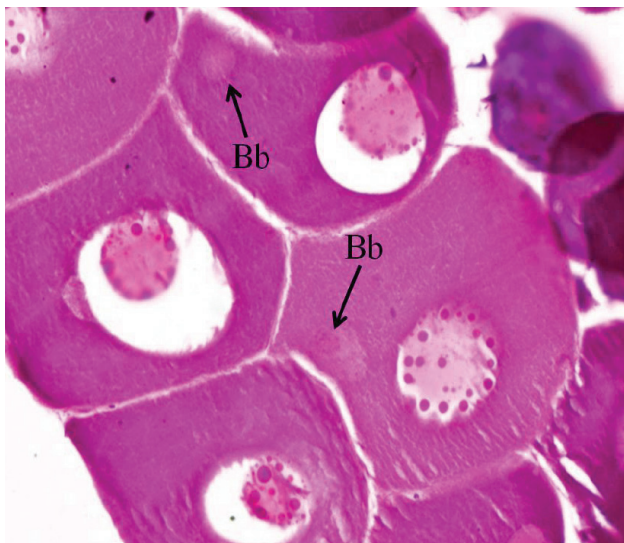
the increase in nuclear activity at this stage. As the oocyte size increases, there was reduction in nucleus size. Similar findings have been reported in the ovaries of *Sand whiting* fish (Jayasankar and Alagaraswami, 1994), *Dusky grouper* (Mandich *et al.*, 2002), *Yellowfin seabream* (Abou -Seedo *et al.*, 2003), the *Sword fish* (Corriero *et al.*, 2004), *Zebra fish* (Deniz Koc *et al.*, 2008) and *Nile tilapia* (El-Saba *et al.*, 2013). The number of perinucleolar oocytes were found to be more in the spent ovaries as reported in *Twaite shad* (Pina *et al.*, 2003). This stage was found to be more during pre spawning period in T<sub>4</sub> and in the spent ovaries in T<sub>8</sub> treatments. This may be due to improvement in ova diameter due to highest feeding rate (4% B W) and feeding frequency (twice a day)

#### Late perinucleolar stage

In this stage, the ooplasm was comparatively less basophilic, whereas the nucleus was large rounded in shape with number of small nucleoli at its periphery. The nucleoplasm appeared to be granular due to dispersion of chromatin material throughout nucleus. The ooplasm were divided into inner dense and deeply basophilic zone and outer less dense and slightly basophilic zone (Fig. 2A). A basophilic rounded mass appeared just at nuclear region in the ooplasm called as Balbiani body or yolk nucleus (Fig. 2B) that moved towards periphery in larger oocytes. The size of the Balbiani body increased with the size of the oocyte. Appearance of Balbiani's body, may be considered as a centre for the biogenesis of cell organelles (Coello and Grim, 1990). Similar structure has also been reported in the oocytes of *Twaite shad* (Pina *et al.*, 2003), the *Sword fish* (Corriero *et al.*, 2004), *Zebra fish* (Deniz Koc *et al.*, 2008) and *Nile tilapia* (El-Saba *et al.*, 2013). According to Guraya (1986), it is composed of a yolk nucleus and the pallial substance. A flattened follicular layer around the oocyte were also differentiated at this stage. The oocyte at this stage may be referred as resting stage, as described by Forberg (1982). This is the last stage of primary growth phase and found during pre spawning period in T<sub>2</sub> and in the spent ovaries in T<sub>1</sub> and T<sub>2</sub>. There is a definite correlation between the diets fed with and without vitamin mineral supplementation as diets without vitamin mineral supplementation resulted in comparatively less basophilic ooplasm in T<sub>1</sub> and T<sub>2</sub> treatments in the development of oocytes.



(A)



(B)

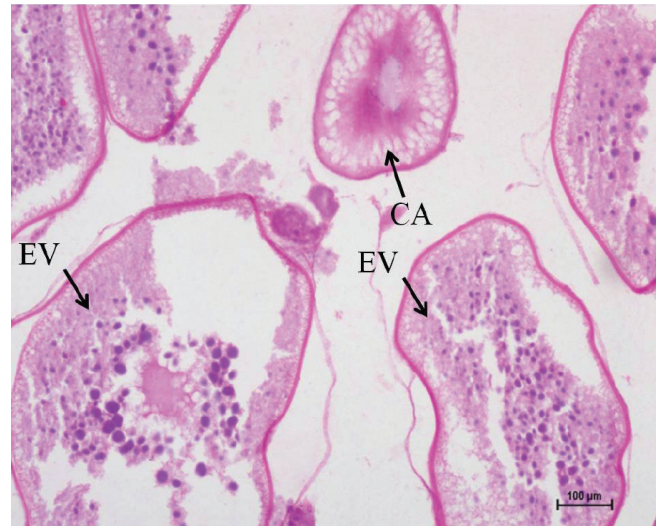**Fig. 2:** Section of fish ovary showing (A) Early perinucleolar stage (EPN) and late perinucleolar stage (LPN) in T<sub>4</sub> group with distinct dark (DZ) and light zone (LZ) in the cytoplasm; (B) Balbiani bodies (Bb) in early and late perinucleolar stage. [H&E, 40×]

## Secondary growth stage

### Cortical alveolar stage

The most characteristic feature of this stage was the formation of large number of unstained vacuoles in the periphery of ooplasm (Fig. 3). The vacuolization may be due to the fact that lipid contents dissolved in paraffin

during processing of tissue samples for histological procedures. There was increase in size of oocyte and nucleus with abundance of darkly stained nucleoli. It was also observed that the number of cortico alveoli increased with the oocyte size, this gave a spongy appearance to the oocyte. Zona pellucida was seen, for the first time at the stage, between the follicular layer and basement membrane. At higher magnification, it was noted that follicular layer was formed by cuboidal cells which was surrounded by thin theca layer.

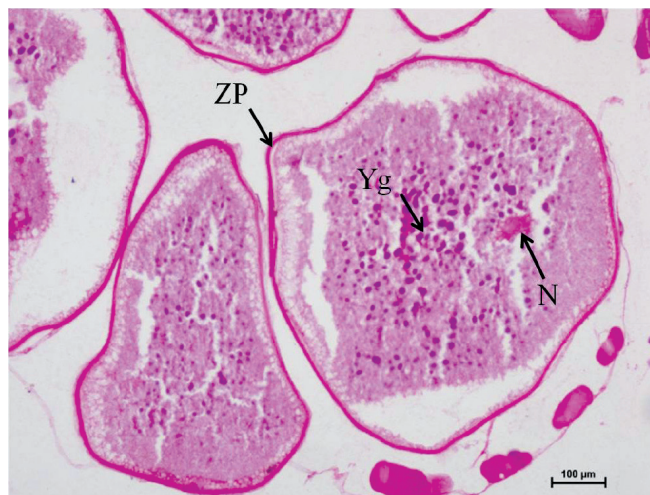

**Fig. 3:** Section of fish ovary in secondary growth phase showing the oocytes in cortical alveolar (CA) and early vitellogenic (EV). [PAS, 100×]

Similar findings have been reported in the ovaries of *Sand whiting* fish (Jayasankar and Alagarwami, 1994), *Dusky grouper* (Mandich *et al.*, 2002), *Yellowfin seabream* (Abou – Seedo *et al.*, 2003), *Twaite shad* (Pina *et al.*, 2003), the *Sword fish* (Corriero *et al.*, 2004), *Zebra fish* (Deniz Koc *et al.*, 2008) and *Nile tilapia* (El-Saba *et al.*, 2013). This stage was commonly found during pre spawning period in T<sub>2</sub> and T<sub>4</sub> and during post spawning period in T<sub>4</sub> and T<sub>6</sub>.

### Early vitellogenic stage

At this stage the oocyte were characterized by the presence of numerous small yolk granules in the middle of cytoplasm (Fig. 4). Lipid vesicles increased in number and size. The vitellus density of oocyte extended towards the centre from the cortico alveolar region. The zona pellucida appeared to be thicker at the previous stage.



**Fig. 4:** Section of fish ovary showing oocytes in early vitellogenic stage with PAS positive yolk Granules (Yg), eccentric nucleus (N) and distinctly PAS positive zona pellucida (ZP). [H&E, 100×]

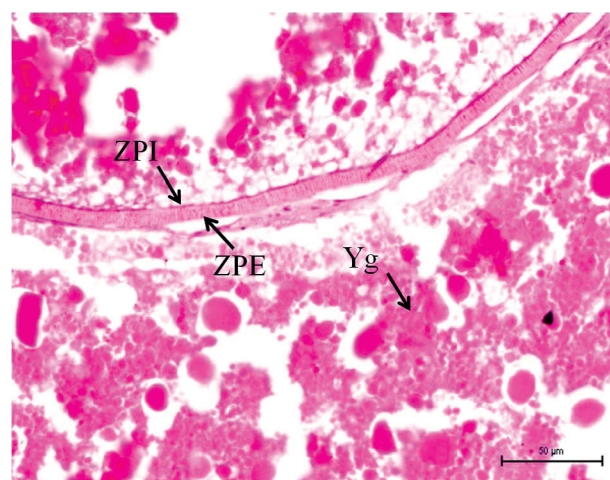
Similar findings were also reported earlier in the ovaries of *Sand whiting* fish (Jayasankar and Alagarwami, 1994), *Dusky grouper* (Mandich *et al.*, 2002), *Yellowfin seabream* (Abou-Seedo *et al.*, 2003), *Twaite shad* (Pina *et al.*, 2003), the *Sword fish* (Corriero *et al.*, 2004), Zebra fish (Deniz Koc *et al.*, 2008) and Nile tilapia (El-Saba *et al.*, 2013). The number and size of lipid vesicles increased during pre spawning period in T<sub>4</sub> and T<sub>6</sub> possibly due to increased feeding frequency (twice a day).

#### Late vitellogenic stage

At this stage there was further accumulation of yolk granules in the oocyte that filled the entire ooplasm. The lipid vacuoles were further enlarged by coalescence and located in the periphery of oocyte. The yolk granules also increased in number and size especially in the inner portion. The number and size of these granules increased from centre towards periphery of the oocyte. The appearance of yolk vesicles in the oocyte is an indication of maturation process.

In present study, the yolk granules were of two types. One group was larger in size and was in pale pink in colour and started with the cytoplasm, where as other type of granules were deep blue in colour and were located near the nucleus. The germinal layer was lined by simple cuboidal type of epithelium, which was multilayered at places. The zona pellucida became thicker and was divided into

an outer zona pellucida interna and inner zona pellucida externa. The striations were also seen in zona pellucida (Fig. 5). Similar findings were reported in the ovaries of *Sand whiting* fish (Jayasankar and Alagarwami, 1994), *Dusky grouper* (Mandich *et al.*, 2002), *Yellowfin seabream* (Abou-Seedo *et al.*, 2003), *Twaite shad* (Pina *et al.*, 2003), the *Sword fish* (Corriero *et al.*, 2004), Zebra fish (Deniz Koc *et al.*, 2008) and Nile tilapia (El-Saba *et al.*, 2013). The number of yolk granules were more and compactly arranged in T<sub>4</sub> and T<sub>8</sub> during pre spawning period. This may be possible due to impact of increased feeding rates (4% B W) and frequency (twice a day) which was found to have positive effect on growth and development of oocytes.



**Fig. 5:** Section of fish ovary showing late vitellogenic stage with yolk granules (Yg), Differentiation of Zona pellucida externa (ZPE) and Zona pellucida interna (ZPI) with striations in zona layer in T<sub>6</sub> group. [H&E, 40×]

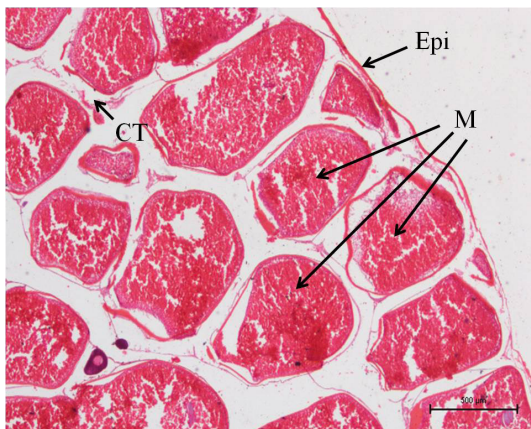
#### Mature follicles (post vitellogenic stage)

This stage was characterized by migration of nucleus towards one side, breakdown of germinal vesicle, ooplasm hydration and complete detachment of the follicular cells (Fig. 7). At this stage, the follicular layers were stretched and became flattened with decreased thickness, whereas the zona pellucida was more compact. Similar findings were reported in the ovaries of *Sand whiting* fish (Jayasankar and Alagarwami, 1994), *Dusky grouper* (Mandich *et al.*, 2002), *Yellowfin seabream* (Abou-Seedo *et al.*, 2003), *Twaite shad* (Pina *et al.*, 2003), the *Sword fish* (Corriero *et al.*, 2004), Zebra fish (Deniz Koc *et al.*, 2008) and Nile tilapia (El-Saba *et al.*, 2013). This stage was more prominent in T<sub>4</sub> and T<sub>8</sub> during pre spawning

period. Feeding rate (4%) and feeding frequency improves survival and growth rate, net weight gain resulting in improvement of oocyte development absolute fecundity relative fecundity and ova diameter

### Post ovulatory stage

These were formed by the collapse of follicles after ovulation and were characterized by a large and irregular follicular lumen occupied by the oocyte. There was hypertrophy of granulosa cells which had a prominent nucleus. The number of blood vessels in the theca layer was increased. The follicular cells proliferated and hypertrophied. At the end, the oocytes were collapsed and replaced by stromal tissue. This stage was more common and abundant in the spent ovaries. Similar findings were reported in the ovaries of *Twaite shad* (Pina *et al.*, 2003), the *Sword fish* (Corriero *et al.*, 2004), Zebrafish (Deniz Koc *et al.*, 2008) and Nile tilapia (El-Saba *et al.*, 2013). Contrary to the present observations, post ovulatory stage could not be observed in the ovaries of *Labeo rohita* by Lone and Hussain (2009). This stage was commonly observed during early stages of post spawning period.

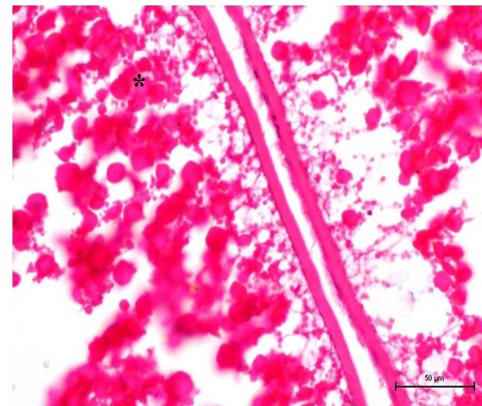


**Fig. 6:** Section of ovary showing mature oocytes (M)/ Post Vitellogenic stage surrounded by epithelium (Epi) with connective tissue stroma (CT) in between. [H&E, 40×]

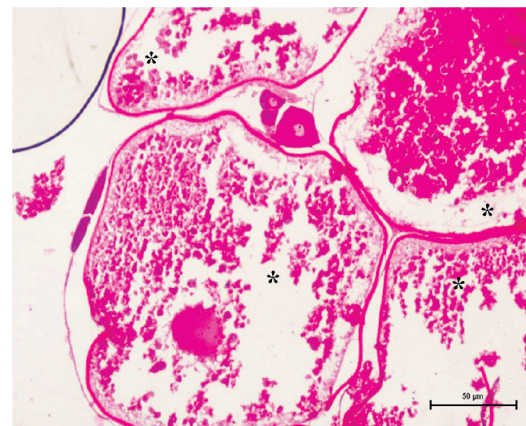
### Atretic Oocytes (Atresia)

Like vertebrates, atresia is an involutive process occurring in fish ovaries also. In present study, two types of atresia were observed as early and late stages. In early atresia the nucleus became more irregular and basophilic. There was disintegration of zona pellucida and yolk

granules (Fig. 7A). Early atresia were observed at all the stages of development of oocytes. At perinucleolar stage (Fig. 7B), first the degenerative changes occurred in the nucleus, then at periphery, but it was reverse in the early and late vitellogenic stages. In late atresia, the follicular epithelium became thicker and separated from oocyte. There was degeneration of yolk and lipid granules which was phagocytized by the hypertrophied granulosa cells invading the degenerated oocyte (Fig. 7B). At perinucleolar stage, the degenerative changes occurred in the nucleus and cytoplasm which were stained lighter due to vacuolation. In late atresia, more degenerative changes were reported and the oocytes showed complete or partial loss of yolk globules. The complete loss of the yolk granules in some of the vitellogenic stage may be due to absorption of yolk in spent ovaries.



(A)



(B)

**Fig. 7:** Section of fish ovary showing (A) Early atresia starting from the peripheral region in late vitellogenic oocytes in T6 ovaries (\*asterick), (B) Late atresia in post vitellogenic oocytes in post spawning ovaries of T3 group (\*asterick). [H&E, 40×]

Similar findings were reported in the ovaries of *Dusky grouper* (Mandich *et al.*, 2002), *Yellowfin seabream* (Abou-Seedo *et al.*, 2003), the *Sword fish* (Corriero *et al.*, 2004) and Nile tilapia (El-Saba *et al.*, 2013). In the present study, the atretic oocytes were more at all stages of reproduction in fish ovaries, but it was frequently seen in the spent ovaries in T<sub>1</sub> and T<sub>2</sub> (diets without mineral mixture ) According to Guraya (1994), atresia was most frequent during post spawning period in fish. Atresia was mostly seen in the oocyte from secondary growth phase onwards than in the primary growth phase.

### CONCLUSION

From the present investigation, it may be inferred that the development of oocytes in *Labeo rohita* is asynchronous due to the simultaneous presence of all the developmental stages of oocytes in the ovary. It is also concluded that in *L. rohita* fed on feed with and without vitamin- mineral-mixture and having higher feeding rate (4%) and feeding frequency (twice a day), the ovaries contained compactly arranged vitellogenic and mature oocytes, while the spent had mostly in primary growth phase and atretic oocytes.

### REFERENCES

- Abou-Seedo, F., Dadzie, S. and Al-Kanaan, K.A. 2003. Histology of ovarian development and maturation stages in the yellowfin seabream, *Acanthopagrus latus* (Teleostei: Sparidae) reared in cages. *Kuwait J. Sci. Eng.*, **30**(1): 121-37.
- Arruda, L.M. 1988. Maturation cycle in the female gonad of the Snipefish *Macroramphus gracillius* of the western coast of Portugal. *Invest. Pesq.*, **52**(3): 355-374.
- Bagenal, T.B. and Tesch, F.W. 1978. Age and growth. In: Methods for assessment of fish production in freshwater. Bagenal T.B., 3<sup>rd</sup> Ed., Blackwell Scientific Publication, Oxford, pp. 101–136.
- Bara, G. 1960. Histological and cytological changes in the ovaries of mackaral *Scomber scombrus* during the annual cycle. *Istamb. Univ. Fen Fak. Mecm.*, Ser. B., **25**: 49-91.
- Coello, S. and Grim, A.S. 1990. Development of Balbiani's vitamins body in the oocytes of Atlantic mackaral *Scomber scombrus* . *J. Fish Biol.*, **36**: 265-267.
- Corriero, A., Acone, F., Desantis, S., Zubani, D., Deflorio, M., Ventriglia, G., Bridges, C.R., Labate, M., Palmieri, G., McAllister, B.G., Kime, D.E. and De Metrio, G. 2004. Histological and immunohistochemical investigation on ovarian development and plasma estradiol levels in the swordfish (*Xiphias gladius* L). *Eur. J. Histochem.*, **48**(4): 413-422.
- Aytekin, Y. and Yüce, R. 2008. Ovary Maturation Stages and Histological Investigation of Ovary of the Zebrafish (*Danio rerio*). *Braz. Arch. Biol. Technol.*, **51**(3): 513-522.
- El-Saba, A., AbdRabou, M.I., El-Sakhawy, M.A., El-Shammaa, M.A. and Hussein, S.M. 2013. Seasonal changes in the histology of the ovaries of Nile tilapia (*Oreochromis niloticus*). *J. Vet. Anat.*, **6**(2): 1-21.
- Forberg, K.G. 1982. A histological study of development of oocytes in capelin, *Mallotus villosus*. *J. Fish Biol.*, **20**: 143-154.
- Guraya, S.S. 1986. The cell and molecular biology of fish oogenesis. *Monogr. Dev. Biol.*, **18**: 1-223.
- Guraya, S.S. 1994. Gonadal development and production of gametes in fish. *Proc. Indian Nat. Sci. Acad.*, **60**: 15-32.
- Jayasankar, P. and Alagarwami, K. 1994. Histological and histochemical observations in the oocytes in the Sand Whiting *Sillago sihama* (Forsskall). *Proc. Indian Nat. Sci. Acad.*, **60**(2): 173-182.
- Lone, K.P. and Hussain, A. 2009. Seasonal and age related variations in the ovaries of *Labeo rohita*: A detailed gross and histological study of gametogenesis, maturation and fecundity. *Pak. J. Zool.*, **41**(3): 217-234.
- Luna, L. G. 1968. Manual of histological staining methods of the Armed Forces Institute of Pathology. 3<sup>rd</sup> Ed., Mc-Graw Hill Book Company, New York.
- Mandich, A., Massari, A., Bottero, S. and Marino, G. 2002. Histological and histochemical study of female germ cell development in the dusky grouper *Epinephelus marginatus*. *Eur. J. Histochem.*, **46**: 87-100.
- Pina, T., Eduardo, E., Andrade, J.P. 2003. Gross and histological observations of ovarian development in twaite shad, *Alosa fallax fallax*, from the rivers Mira and Guardiana (Portugal). *Sci. Mar.*, **67**(3): 313-322.
- Yamamoto, K. 1956. Studies on the formation of fish eggs. Annual cycle in the development of ovarian eggs in the flounder *Liopsetta obscura*. *J. Fac. Sci. Hokkaido University*, **12**: 362-373.

