

Herlyn-Werner-Wunderlich syndrome presented with amenorrhea: A rare urogenital anomaly in females

Mustafa Ayhan Ekici¹, Pelin Oyardi¹, Funda Dagistanli¹, Omur Albayrak¹, Caglar Cetin²

¹Department of Gynecology and Obstetrics, Faculty of Medicine, Bolu Abant Izzet Baysal University, Bolu, Turkey

²Gerede State Hospital, Bolu, Turkey

ABSTRACT

A 13-year-old prepubertal girl had with primary amenorrhea and severe lower abdominal pain. Pelvic ultrasound showed double uterine cavity and a fluid collection in left uterine cavity with diffuse low level internal echoes, which appeared contiguous with the endocervix. Hymen could not be evaluated because the patient could not be taken to the gynecological table the patient was initially diagnosed as imperforate hymen, gynecologic examination was performed with sedation, and hymen has a normal patency. Magnetic resonance imaging (MRI) revealed two uterus and two cervix, normal right endometrial cavity and 17 mm fluid in the left endometrial cavity and compatible with hematometra. Hematocolpos was observed in the left half of the vagina. There was no left kidney and the right kidney was normal. Based on these findings, the patient was diagnosed as Herlyn-Werner-Wunderlich syndrome and vaginal septum resection was performed as treatment. Evaluation of the genital tract by means of MRI scanning or ultrasonography should be recommended in all girls with known renal abnormalities before the onset of menstruation.

Key Words: Herlyn-Werner-Wunderlich syndrome, amenorrhea, renal agenesis, hematometra, uterus didelphis.

Copyright © 2019 [pediatricurologycasereports.com](http://www.pediatricurologycasereports.com)

Correspondence: Dr. Mustafa Ayhan Ekici
Gynecology and Obstetrics, Faculty of Medicine, Bolu
Abant Izzet Baysal University, Bolu, Turkey

E mail: mayhanekici@hotmail.com

ORCID ID: <https://orcid.org/0000-0002-0745-0907>

Received 2019-09-30, Accepted 2019-10-14

Publication Date 2019-11-01

Introduction

Ipsilateral renal agenesis associated with hematocolpus-hematometra due to blind hemivagina and uterine didelphis is known as Herlyn-Werner-Wunderlich syndrome

(HWWS) or, more recently, obstructed hemivagina and ipsilateral renal anomaly (OHVIRA). HWWS is a rare type of Wolffian and Müllerian duct anomaly that can show vertical and lateral fusion failures of Müllerian ducts for approximately 9 weeks of gestation [1]. The exact etiology of HWWS is still unknown and its incidence is approximately 0.1% to 3.8% [2]. Herlyn-Werner syndrome (renal agenesis and an ipsilateral blind hemivagina) was first described in 1971 by Herlyn and Werner [3]. In 1976, Wunderlich

described the relationship between the blind vagina with hematocervix-bicornuate uterus and right renal agenesis [4]. HWWS could be classified according to the complete or incomplete obstruction of the hemivagina [5]. The renal agenesis is usually detected on the right side with a rate of about 60%.

Clinically, it usually presents in postpubertal adolescent or adult women where hematometrocolpos produces a more pronounced mass effect and pain on the side of the obstructed hemivagina [6]. We aimed to report this case because of it was in a prepubertal girl who had no previous menstruation, and hematoma in the uterine cavity related to blind hemivagina, but no bleeding from the other uterine cavity.

Case report

A 13-year-old prepubertal girl presented to our institution with severe lower abdominal pain. She had no previous menstruation and had intermittent pelvic pain in her anamnesis. Secondary sex characteristics of the patient were normal. The vulva and labia in external genital examination was normal. The hymen could not be evaluated because the patient could not be taken to the gynecological table. Physical exam was remarkable only a palpable left pelvic mass. Pelvic ultrasound showed double uterine cavity and a 25 mm fluid collection in left uterine cavity with diffuse low level internal echoes, which appeared contiguous with the endocervix (Fig. 1). No fluid was observed in the right uterine cavity. The ovaries were bilaterally normal. The patient was initially diagnosed as imperforate hymen, gynecologic examination was performed with sedation, and hymen has a normal patency.

When the endoscope was inserted into the vagina through the hymenal space, it was

found that there was only one cervix and there was no cervico-vaginal hematoma. The intervention was terminated for further review. One week later, magnetic resonance imaging (MRI) revealed two uterus and two cervixes, normal right endometrial cavity signal and thickness, and 17 mm fluid in the left endometrial cavity and consistent with hematometra (Fig. 2).

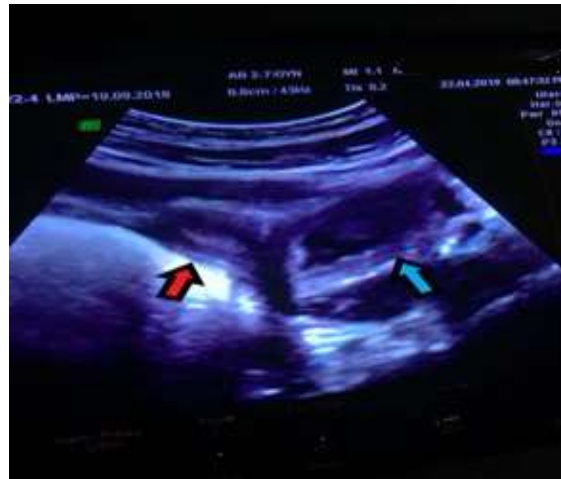

Fig. 1. Pelvic ultrasonography image showing double uterine cavity and 25 mm fluid collection with diffuse low-level internal echo in the left uterine cavity.

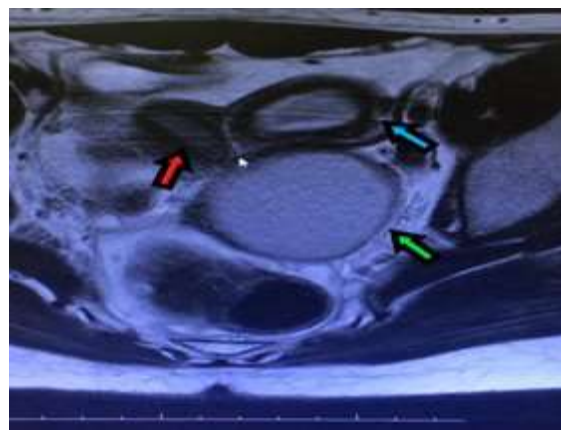


Fig. 2. Magnetic resonance image showing two uterus and two cervix, normal right endometrial cavity signal and thickness and 17 mm fluid in the left endometrial cavity and compatible with hematometra.

In the left half of the vagina, 50 x 55 mm of fluid accumulation was observed starting from 3.5 cm proximal to the vaginal entrance and compatible with hematocolpos (Fig. 3). In addition, the left kidney was absent and the right kidney was normal (Fig. 4).

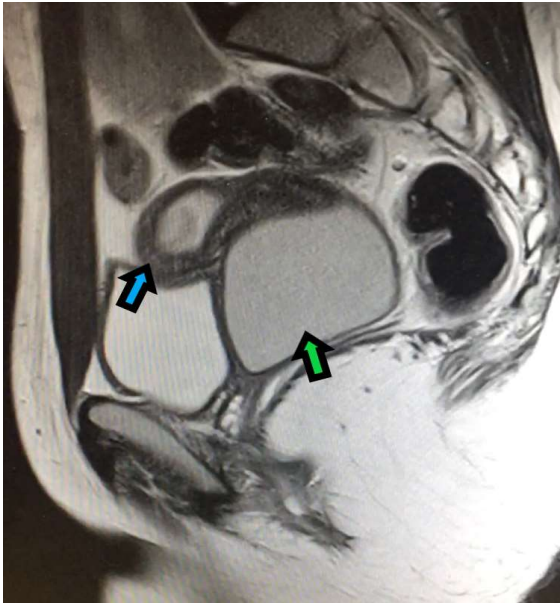


Fig. 3. MR image showing 50 x 55 mm fluid accumulation in the left half of the vagina which was compatible with hematocolpos starting from 3.5 cm proximal to the vaginal introitus.

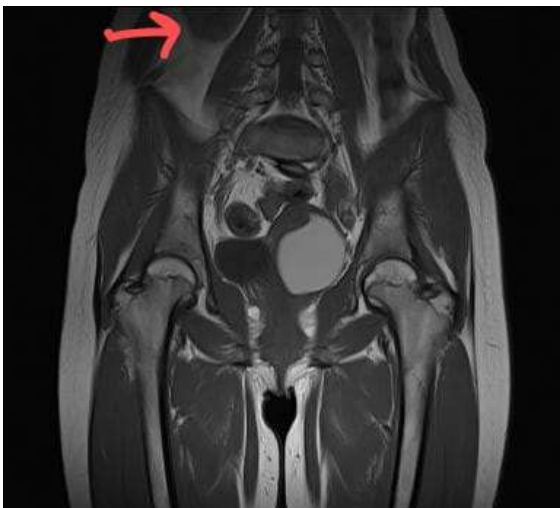

Fig. 4. MR image showing a right renal lower pole in T1 coronal section, but no left kidney.

Based on these findings, the patient was diagnosed as HWW syndrome. Vaginal septum resection was performed as treatment. The oblique vaginal septum in the left half of the vagina, which was located by guiding by pelvic ultrasonography, was cut completely by endoscopic the LigaSure. The left uterine cervix was seen when the hematoma was drained in the left blind hemivagina. She was discharged of hospital on the first postoperative day. One month later, she had normal menstruation.

Discussion

Müllerian duct anomalies which result from non-development or non-fusion of the müllerian ducts or failed resorption of the uterine septum are occurred during the sixth to ninth weeks of fetal life causing a wide-ranging series of reproductive ducts malformations.

The genital and urinary systems originate from a common ridge of mesoderm arising along the dorsal body wall and withstand on normal development of the mesonephric system. Therefore, abnormal differentiation of the mesonephric and paramesonephric ducts may also be related with anomalies of the kidneys [7]. Renal agenesis is occurred concurrent with ipsilateral obstructive Müllerian anomaly about 60% of patients [8]. These anomalies have a right-sided dominance [9, 10]. Usually, HWW syndrome presents with acute or chronic pelvic pain shortly following menarche. These patients menstruate normally and may have no specific symptoms, except dysmenorrhea [11]. In our patient, there was amenorrhea as difference from other cases.

Previous reports regarding uterus didelphys and blind hemivagina associated with ipsilateral renal agenesis have involved eight cases of HWWS and their appropriate

interventions in 2004, twelve cases of pediatric HWWS patients in 2006, one case of HWWS and ectopic ureter presenting with vulvodynia and recurrent fever in 2010, and 36 cases of HWWS, with long-term follow-ups, in 1997 [8,12-14]. 70 patients with confirmed diagnoses of HWWS who were admitted to the Peking Union Medical College Hospital between January 1995 and December 2010 were retrospectively reviewed by Tong et al [6].

If treatment is delayed, complications may develop, such as infections, pelvic adhesions and may be endometriosis [13-15]. Clinical suspicion and awareness of the syndrome are therefore necessary to making a timely diagnosis and preventing these complications. The delay in diagnosis was due to several factors. If the patient menstruates regularly from the non-obstructed horn, the diagnosis of outflow obstruction is more difficult.

Ultrasound is the most widely used diagnostic tool [16]. But, MRI is considered to be more sensitive for imaging soft-tissue anatomy and delineating subtle findings seen in congenital anomalies [17]. Therefore, it should be obtained before any surgical intervention.

In this case, because the symptoms of amenorrhea and severe abdominal pain were prominent, hematometra and hematocolpos detected by ultrasonography were firstly considered as imperforated hymen. Although there was menstruation bleeding from uterine cavity associated with blind vagina, the absence of menstruation bleeding from uterus opening to normal vagina was a very rare condition. The patient's history of the renal agenesis was a finding that helped us to reach the diagnosis. But, MRI scan led us to a definitive diagnosis. Resection of the vaginal

septum is the main treatment for HWW syndrome.

In conclusion, evaluation of the genital tract by means of MRI scanning or ultrasonography should be recommended in all girls with known renal abnormalities before the onset of menstruation.

Compliance with ethical statements

Conflicts of Interest: None.

Financial disclosure: None.

Consent: All photos were taken with parental consent.

ORCID ID of Authors

Mustafa Ayhan Ekici- 0000-0002-0745-0907

Pelin Oyardi- 0000-0001-6405-0259

Funda Dagistanli- 0000-0002-9915-8937

Omur Albayrak- 0000-0003-2323-3037

Caglar Cetin- 0000-0002-9263-9914

References

- [1]Burgis J. Obstructive Müllerian anomalies: Case report, diagnosis, and management. *Am J Obstet Gynecol.* 2001;185(2):338–44.
- [2]Tridenti G, Armanetti M, Flisi M, Benassi L. Uterus didelphys with an obstructed hemivagina and ipsilateral renal agenesis in teenagers: Report of three cases. *Am J Obstet Gynecol.* 1988;159(4):882–83.
- [3]Herlyn U, Werner H. Simultaneous occurrence of an open Gartner-duct cyst, a homolateral aplasia of the kidney and a double uterus as a typical syndrome of abnormalities. *Geburtshilfe Frauenheilkd.* 1971;31(4):340–47.
- [4]Wunderlich M. Unusual form of genital malformation with aplasia of the right kidney. *Zentralbl Gynakol.* 1976;98(9):559–62.

- [5]Zhu L, Chen N, Tong JL, Wang W, Zhang L, Lang JH. New classification of Herlyn-Werner-Wunderlich syndrome. *Chin Med J (Engl)*. 2015;128(2):222–25.
- [6]Tong J, Zhu L, Lang J. Clinical characteristics of 70 patients with Herlyn-Werner-Wunderlich syndrome. *Int J Gynaecol Obstet*. 2013;121(2):173–75.
- [7]Purslow CE. A case of unilateral haematocolpos, haematometra and haematosalpinx. *J Obstet Gynaecol Br Emp*. 1922; 29(4): 643.
- [8]Ozturk H, Dagistan E, Ozlu T. Role of OHVIRA syndrome in renal agenesis: a case report. *Pediatr Urol Case Rep*. 2014;1(2):5- 11.
- [9]Vercellini P, Daguati R, Somigliana E, Viganò P, Lanzani A, Fedele L. Asymmetric lateral distribution of obstructed hemivagina and renal agenesis in women with uterus didelphys: institutional case series and a systematic literature review. *Fertil Steril*. 2007;87(4):719-24.
- [10]Smith NA, Laufer MR. Obstructed hemivagina and ipsilateral renal anomaly (OHVIRA) syndrome: management and follow-up. *Fertil Steril*. 2007;87(4):918-22.
- [11] Jeong J-H, Kin Y-J, Chang C-H, Choi H. A case of Herlyn–Werner–Wunderlich syndrome with recurrent hematopyometra. *J Womens’ Med*. 2009;2(2): 77-80.
- [12]Gholoum S, Puligandla PS, Hui T, Su W, Quiros E, Laberge JM. Management and outcome of patients with combined vaginal septum, bifid uterus, and ipsilateral renal agenesis (Herlyn-Werner-Wunderlich syndrome). *J Pediatr Surg*. 2006; 41(59):987–92.
- [13]Tong J, Zhu L, Chen N, Lang J. Endometriosis in association with Herlyn-Werner-Wunderlich syndrome. *Fertil Steril*. 2014;102(3):790–94.
- [14]Candiani GB, Fedele L, Candiani M. Double uterus, blind hemivagina, and ipsilateral renal agenesis: 36 cases and long-term follow-up. *Obstet Gynecol*. 1997;90(1):26–32.
- [15]Widyakusuma LS, Lisnawati Y, Pudyastuti S, Haloho A AH rare case of pelvic pain caused by Herlyn-Werner-Wunderlich Syndrome in an adult: A case report. *Int J Surg Case Rep*. 2018; 49:106-109.
- [16]Hollander MH, Verdonk PV, Trap K. Unilateral renal agenesis and associated Müllerian anomalies: a case report and recommendations for pre-adolescent screening. *J Pediatr Adolesc Gynecol*. 2008;21(3):151-53.
- [17]Troiano RN. Magnetic resonance imaging of mullerian duct anomalies of the uterus. *Top Magn Reson Imaging*. 2003;14(4):269-79.

Access this article online

<http://pediatricurologycasereports.com>

Quick Response Code

