




## PEDIATRIC UROLOGY CASE REPORTS

ISSN 2148-2969

<http://www.pediatricurologycasereports.com>**Case report: Renal artery spasm can mimic grade 5 renal injury following pediatric blunt trauma****Tiffany Perkins<sup>1</sup>, Dennis Peppas<sup>2</sup>, Eran Rosenberg<sup>2</sup>**<sup>1</sup>University of Louisville, School of Medicine, Department of Urology, Louisville, KY, USA<sup>2</sup>Norton Children's Urology Specialists, Louisville, KY, USA**ABSTRACT**

Children are more likely to be exposed to blunt trauma-induced kidney damage due to the lack of perirenal adipose tissue, weakness in the abdominal muscles, and less ossified thoracic cage. Grade 5 renal injury may be an indication for urgent surgical intervention. Here, we describe a case of pediatric blunt trauma with initial computerized tomography (CT) scan demonstrating complete renal devascularization suggestive of grade 5 renal injury. However, subsequent imaging demonstrated normal vascularization of the kidney. Renal artery spasm was likely the cause for the initial CT findings, which mimicked a grade 5 renal injury.

**Key Words:** Renal artery spasm, blunt renal trauma, pediatrics.*Copyright © 2019 pediatricurologycasereports.com*

*Correspondence: Dr. Eran Rosenberg,  
4123 Dutchmans Lane, Suite 102, Louisville, KY 40207,  
USA*

*E mail: [eran.rosenberg@nortonhealthcare.org](mailto:eran.rosenberg@nortonhealthcare.org)*

*ORCID ID: <https://orcid.org/0000-0002-1816-237X>*

*Received 2019-02-12, Accepted 2019-02-20*

*Publication Date 2019-05-01*

**Introduction**

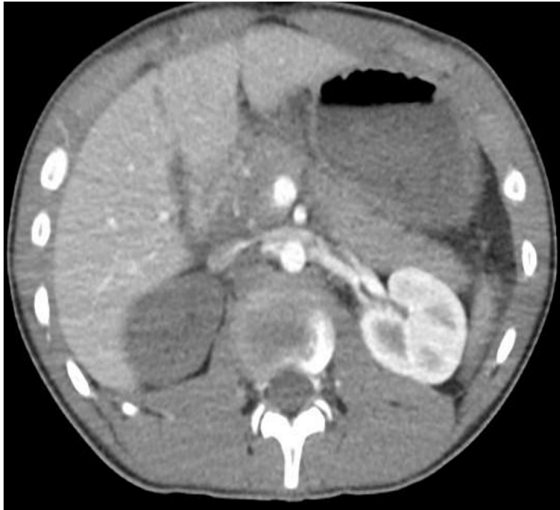Renal injury is graded on a scale of 1 through 5 in order of increasing severity to help guide management [1]. CT is the gold standard imaging modality used to diagnose renal injury [2]. We present a case of a pediatric trauma with a contrast enhanced CT demonstrating no enhancement of one of his kidneys, suggestive of renal devascularization. It was managed non-operatively, with subsequent imaging showing normal enhancement of the kidney.

**Case report**

A 12-year old male was involved in an all-terrain vehicle (ATV) accident in which the vehicle rolled over. He was initially seen at a local ER where a CT of the abdomen and the pelvis revealed a grade 3-4 liver laceration, small apical pneumothorax, and complete devascularization of the right kidney. He was then transferred to our institution, by which time, approximately 8 hours had passed since the initial trauma.

Upon our evaluation, he was noted to be awake and alert with intact airways and mild abdominal pain. He was tachycardic with heart rate ranging 100-115, normal respiratory rate, and blood pressure 121/70. FAST exam revealed free fluid in the pelvis. His hemoglobin was 9.9, down from 13 at the outlying hospital, so he was transfused 1U

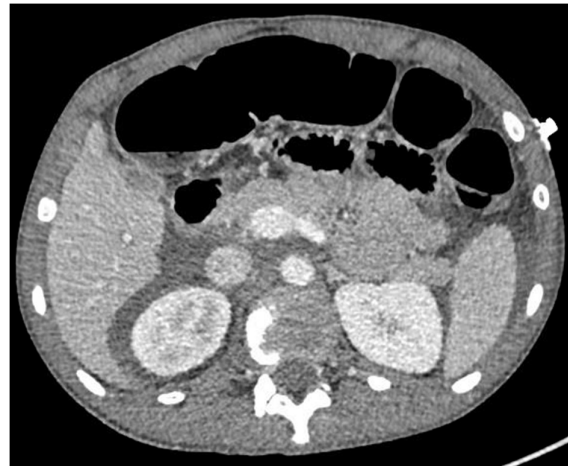packed red blood cells. His heart rate stabilized with blood transfusion and IV fluid hydration. His creatinine was 0.9. Urinalysis revealed moderate blood with 17RBC/hpf. Review of the CT obtained at the outlying hospital revealed complete lack of enhancement in the right kidney, suggestive of devascularization of the right kidney (Fig. 1).



**Fig. 1.** Lack of enhancement of right kidney at initial presentation.

Since he was hemodynamically stable, and due to the length of time from the injury to arrival at our hospital, a non-operative management approach was chosen. During his admission, his vital signs and hemoglobin remained stable. Two days later, a repeat contrast enhanced CT of the abdomen and pelvis was done. To our surprise, the right kidney appeared to have normal enhancement throughout the majority of the kidney, except for a small segment in the inferior pole (Fig. 2). He improved clinically. A repeat UA showed trace blood and renal ultrasound showed mildly increased echogenicity of the right kidney, without any evidence of hydronephrosis or perinephric fluid. He was then discharged home. He was doing well during the 3-month follow up visit. His renal

ultrasound was normal, with no evidence of scarring. He had 50 RBC's in his UA.



**Fig. 2.** Normal enhancement of right kidney two days after injury.

### Discussion

The AAST Organ Injury Scaling Committee provides a commonly used classification for renal injury, which is useful for determining management and predicting clinical outcomes [1]. CT is the gold standard imaging for renal trauma [2].

Hemodynamic instability due to a renal source, and expanding/pulsatile hematoma are considered absolute indications for exploration. Coexisting intra-abdominal injuries and a grade 3 or higher renal injury, like in this case, are considered a relative indication for exploration. It has been shown that many of these patients can be managed safely, with expectant approach, even with grade 5 renal injuries, and follow up computerized tomography revealing functioning renal parenchyma with resolution of retroperitoneal hematoma [3].

Trauma or contusion may lead to renal artery spasm, resulting in temporary occlusion of blood flow to the kidney. Renal artery spasm can present with a nonopacified kidney on CT scan, giving the appearance of a

devascularized kidney [4]. However, it is possible for renal artery spasm to appear indistinguishable from thrombosis or even avulsion of the main renal artery. Additionally, contrast media activates various factors that induce renal vasoconstriction [5]. These factors may potentially contribute to the phenomenon we observed with this patient. Although unusual, it is possible that the trauma contributed to renal artery spasm giving the appearance of a devascularized kidney.

### **Conclusion**

High-grade renal injuries might require emergent exploration. However, in a patient that is clinically stable, non-operative management may be appropriate. Our case brings up an interesting phenomenon that supports non-operative management in a stable patient. On initial presentation, his right kidney lacked any enhancement, suggestive of absence of blood flow to the kidney. Although he was initially tachycardic and required a blood transfusion, he quickly stabilized. On subsequent imaging, the right kidney appeared well vascularized with the exception of a small lower pole segment. Exploration and its associated morbidity were avoided, with a good outcome in this case. In conclusion, renal devascularization can potentially appear indistinguishable from renal artery spasm or brief vasoconstriction on imaging. Clinically stable patients can often be safely managed without surgical intervention with appropriate follow up imaging.

### **Compliance with ethical statements**

*Conflicts of Interest:* None.

*Financial disclosure:* None.

*Consent:* All photos were taken with parental consent.

### **References**

- [1] Moore EE, Shackford SR, Pachter HL, McAninch JW, Browner BD, Champion HR, et al. Organ injury scaling: spleen, liver, and kidney. *J Trauma.* 1989;29(12):1664-66.
- [2] Federle MP, Brown TR, McAninch JW. Penetrating renal trauma: CT evaluation. *J Comp Assist Tomogr.* 1987;11(6):1026-30.
- [3] Altman AL, Haas C, Dinchman KH, Spirnak JP. Selective nonoperative management of blunt grade 5 renal injury. *J Urol.* 2000;164(1):27-30.
- [4] Ucar A, Yahyayev A, Agayev A, Yanar F, Bakan S, Bulakci M, et al. Severe spasm of the renal artery after blunt abdominal trauma simulating end-organ infarction. *Case Rep Med.* 2010; Article ID 207152: 3 pages.
- [5] Kurihara O, Seino Y, Shibata Y, Matsushita M, Komiyama H, Kato K, et al. Blunted renal vasoconstriction in patients with subclinical contrast-induced renal injury. *Clin Exp Pharmacol Physiol.* 2016;43(11):1148-50.

Access this article online

<http://pediatricurologycasereports.com>

Quick Response Code

