


**PEDIATRIC UROLOGY CASE REPORTS**

ISSN 2148-2969

<http://www.pediatricurologycasereports.com>**Splenogonadal fusion: An important differential diagnosis for testicular masses****Julio Slongo¹, Diana Cardona-Grau², Hubert Santiago Swana², Mark Alan Rich²**¹Department of Urology, University of South Florida; Tampa, FL, USA²Department of Urology, Arnold Palmer Hospital for Children; Orlando, FL, USA**ABSTRACT**

Splenogonadal fusion is a rare cause of scrotal swelling. We present a case of a 9-year-old boy with a left testicular mass and phocomelia who was found to have splenogonadal fusion upon scrotal exploration. We discuss the etiology, pathophysiology and management of splenogonadal fusion.

Key Words: Accessory spleen, testicular mass, splenogonadal fusion.

Copyright © 2019 pediatricurologycasereports.com

*Correspondence: Dr. Julio Slongo,
Department of Urology, University of South Florida;
Tampa, FL, USA*

E mail: julioslongo@health.usf.edu

ORCID ID: <https://orcid.org/0000-0001-9895-6972>

Received 2019-02-06,

Accepted 2019-03-04

Publication Date 2019-05-01

Introduction

Splenogonadal fusion (SGF) is a rare congenital abnormality caused by the abnormal fusion of splenic and gonadal tissues early in development and subsequent joint migration toward the scrotum. This rare diagnosis is seldom considered during the work-up for testicular masses. The non-specific scrotal ultrasound findings in these cases may contribute to a more aggressive management due to the concern for malignancy [1,2]. We present a case of a 9-year-old boy presenting with a painless left testicular mass whose intraoperative findings revealed SGF.

Case report

A 9-year old boy presented to clinic with presumed left testicular enlargement which was painless and had been present for at least 2 years. The child was adopted, with an unknown family history. He had a past medical history significant for congenital upper and lower extremity phocomelia. There was no associated history of local trauma or infections. On physical exam the left testicle was firm and nodular, measuring approximately 4 x 2 cm (Fig. 1). The right testicle was in orthotopic position, without masses and noticed to be soft, measuring 1x1 cm.

Scrotal ultrasonography revealed a normal prepubertal right testicle, measuring 1.1 x 1 cm. A homogeneous left testicle without focal masses was described. The testicle was 4.1 x 1.8 cm in size and a mild contour deformity could be seen at the upper pole. Prominent vascularity was noted during Doppler study (Fig. 2).

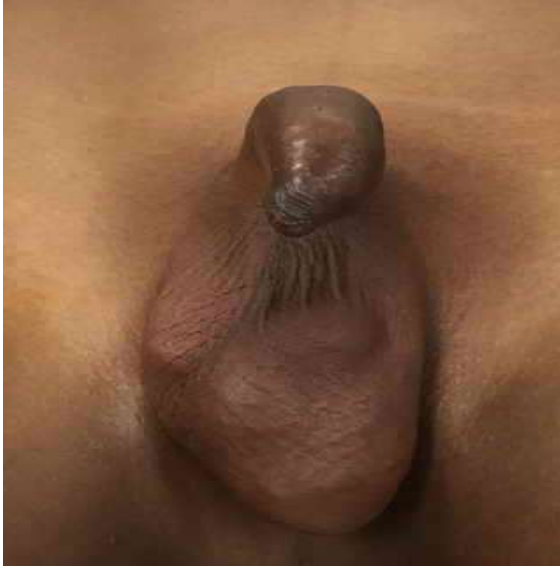

Fig. 1. A firm and nodular appearance of the left testis on physical examination.

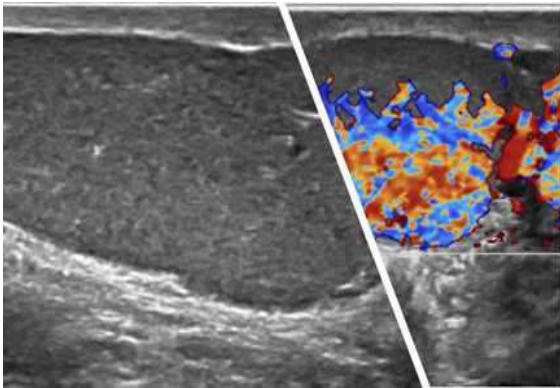


Fig. 2. Doppler study show prominent vascularity.

Due to the discrepancy between physical exam and ultrasonographic findings, decision was made to perform a left inguinal exploration. The gonad was delivered, revealing a large dark-red homogeneous mass. The vas deferens and epididymis were identified but normal testicular tissue was not found (Fig. 3). Due to the high suspicion for SGF at this time, attempts were made to separate the splenic tissue from true testicle, however, no clear plane was identified. Therefore, a radical orchiectomy/splenectomy was performed. Of

note, the patient had a previous abdominal US revealing a normal spleen. The patient tolerated the procedure well and was discharged home on the same day.

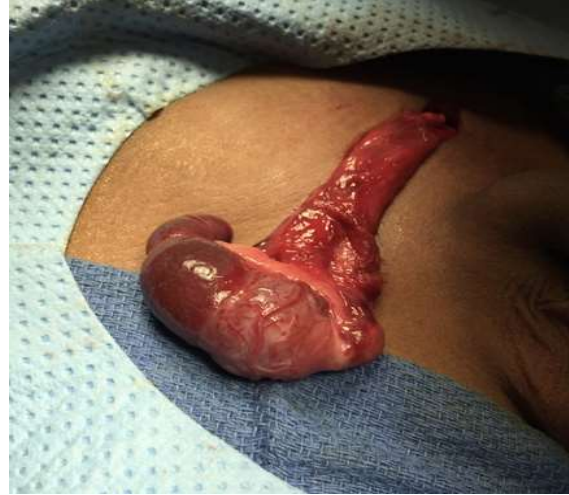

Fig. 3. Intraoperatively view of the splenogonadal fusion.

Histopathologic exam of the specimen revealed immature testicular tissue and large amount of splenic tissue, separated by a thin fibrous capsule, consistent with the diagnosis of SGF (Fig. 4).

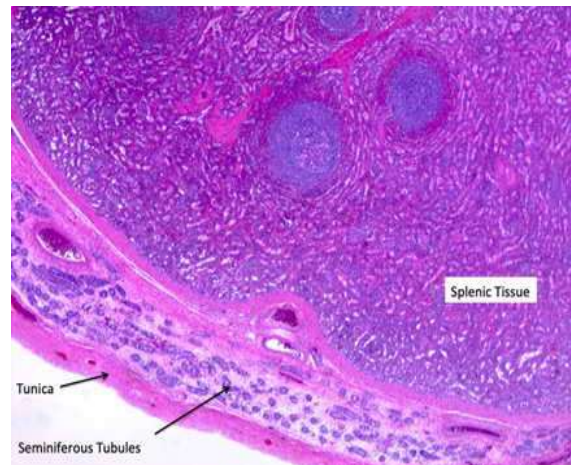


Fig. 4. Histopathologic evaluation shows the immature testicular tissue and large amount of splenic tissue separated by a thin fibrous capsule.

Discussion

Splenogonadal fusion was initially described by Boestrom in 1883, and more cases were characterized by Pommer shortly thereafter. Since that initial report, approximately 200 cases have been reported in the literature [3]. For obvious reasons, SGF occurs more often on the left side (98%). Occurrence is more frequent in males, with a male-to-female ratio of 16:1 [4]. As seen in our patient, there is an association of SGF with other congenital malformations, specifically limb defects and micrognathia [5, 6]. Even though the clinical scenario often mimics testicular tumors upon presentation, to date there are only four cases described with associated testicular tumors, all of them associated with cryptorchidism [7]. SGF can be explained embryologically by the timing and location of splenic and testicular development. Between the 5th and 8th weeks of gestation, the splenic tissue arises from a group of mesenchymal cells. The organ originates from the intraembryonic splanchnic mesoderm and develops as a single bulge or multiple bulges of embryonic connective tissue (mesenchyme). These subsequently fuse together inside the dorsal mesogastrium which becomes the greater omentum later in development [2]. The splenic anlage is located near the left gonadal ridge in the 6th week of gestation [8]. At the same time, the gonads start their development from a group of intermediate mesodermal cells. Gonadal descent occurs between 8 and 10 weeks of gestation and if part of the splenic tissue fuses with the gonadal tissue, they may descend with it. The fusion can interfere with normal migration, causing a cryptorchid testis in about one third of cases or it may not interfere at all, as seen in our patient.

Two different presentations of SGF have been described by Putschar [9]: continuous and

discontinuous forms. In continuous SGF, which is slightly more common (55% of occurrences), the normal spleen remains attached to the gonad by a fibrous band of splenic tissue that transverses the peritoneal cavity. This presentation is more frequently associated with other congenital malformations and can have various presenting symptoms including bowel obstruction caused by this fibrous band [10]. On the other hand, the discontinuous form, as in our patient, involves a complete separation of the gonad from the normally placed abdominal spleen. Discontinuous form of SGF is less commonly associated with other congenital malformations [8].

Especially in the discontinuous form, preoperative diagnosis can be difficult, mostly because of the low level of suspicion. As demonstrated, scrotal ultrasonography is insensitive for the diagnosis, with splenic tissue often resembling an enlarged testicle [11]. Some reports have described that a nodular pattern can be demonstrated in ectopic splenic tissue [12]. Due to the rarity of SGF, this finding is usually not considered during radiologic evaluation. Technetium-99m Sulfur Colloid Scan has been proposed for preoperative diagnosis [13]: this nuclear test is commonly used for diagnosis of ectopic spleens and may be applied for scrotal masses, when the suspicion for SGF is high enough. More commonly, SGF is discovered intraoperatively. When it is possible to separate the ectopic spleen from the true gonad, a frozen pathology analysis may be performed to avoid performing an orchiectomy [14,15].

Conclusion

Awareness and better knowledge of splenogonadal fusion as a differential diagnosis in children with testicular masses is

important in order to avoid unnecessary orchiectomies. A homogeneous testicular US with prominent vascularization should increase suspicion for this condition. A nuclear Scan can be considered, as well as a frozen biopsy at time of surgery. We hope to increase awareness of this diagnosis in order to avoid unnecessary orchiectomies, in cases where viable gonadal tissue exists.

Compliance with ethical statements

Conflicts of Interest: None.

Financial disclosure: None.

Consent: All photos were taken with parental consent.

References

- [1]Melikov R, Altunkol A, Quliyev F, Mammadov E, Abat D. Continuous-type splenogonadal fusion: A rare cause of scrotal swelling *Pediatr Urol Case Rep.* 2015; 2(2):22-25.
- [2]Khairat AB, Ismail AM. Splenogonadal fusion: case presentation and literature review. *J Pediatr Surg.* 2005;40(8):1357-60.
- [3]Jequier S, Hanquinet S, Lironi A. Splenogonadal fusion. *Pediatr Radiol.* 1998;28(7):526.
- [4]Ando S, Shimazui T, Hattori K, Yamamoto T, Kuriyagawa K, Akaza H. Splenogonadal fusion: case report and review of published works. *Int J Urol.* 2006;13(12):1539-41.
- [5]Given HF, Guiney EJ. Splenic-gonadal fusion. *J Pediatr Surg.* 1978;13(3):341.
- [6]Lopes RI, de Medeiros MT, Arap MA, Cocuzza M, Srougi M, Hallak J. Splenogonadal fusion and testicular cancer: case report and review of the literature. *Einstein (Sao Paulo).* 2012;10(1):92-95.
- [7]Varga I, Babala J, Kachlik D. Anatomic variations of the spleen: current state of terminology, classification, and embryological background. *Surg Radiol Anat.* 2018;40(1):21-29.
- [8]Nimkin K, Kleinman PK, Chappell JS. Abdominal ultrasonography of splenogonadal fusion. *J Ultrasound Med.* 2000;19(5):345-47.
- [9]Putschar WG, Manion WC. Splenicgonadal fusion. *Am J Pathol.* 1956;32(1):15-33.
- [10]Hines JR, Eggum PR. Splenic-gonadal fusion causing bowel obstruction. *Arch Surg.* 1961;83:887-89.
- [11]Ferron SA, Arce JD. Discontinuous splenogonadal fusion: new sonographic findings. *Pediatr Radiol.* 2013;43(12):1652-55.
- [12]Doria AS, Daneman A, Moineddin R, Smith CR, Mohanta A, Clarke J, et al. High-frequency sonographic patterns of the spleen in children. *Radiology.* 2006;240(3):821-27.
- [13]Steinmetz AP, Rappaport A, Nikolov G, Priel IE, Chamovitz DL, Dolev E. Splenogonadal fusion diagnosed by spleen scintigraphy. *J Nucl Med.* 1997;38(7):1153-55.
- [14]Harris AM. Splenogonadal Fusion: A Rare Benign Testicular Mass in a 55-Year-Old Male. *Urol Case Rep.* 2016;9:41-42.
- [15]Zhou L, Muthucumar M, Stunden R, Lenghaus D. Splenogonadal fusion: a rare scrotal mass in a 9-year-old boy. *ANZ J Surg.* 2018;88(1-2):E81-E2.

Access this article online

<http://pediatricurologycasereports.com>

Quick Response Code

