



Acute pancreatitis with cytomegalovirus infection in a kidney transplant recipient: A case report

Zeinab Mohseni Afshar¹, Arefeh Babazadeh², Soheil Ebrahimpour², Sima Golmohammadi³✉

¹Department of Infectious Diseases, Faculty of Medicine, Kermanshah University of Medical Sciences, Kermanshah, Iran

²Infectious Diseases and Tropical Medicine Research Center, Health Research Institute, Babol University of Medical Sciences, Babol, I.R. Iran

³Department of Internal Medicine, Kermanshah University of Medical Sciences, Kermanshah, Iran

ARTICLE INFO

Article history:

Received 5 December 2018

Revision 14 December 2018

Accepted 20 December 2018

Available online 24 January 2019

Keywords:

Cytomegalovirus

Acute pancreatitis

Kidney transplant recipient

ABSTRACT

Cytomegalovirus (CMV) can cause significant inflammation. Besides, it is an important cause of pancreatitis in organ transplantations. We report a case of CMV pancreatitis in a 48-year-old male kidney transplant recipient who was admitted with elevated amylase (3 337 U/L) and lipase (1 160 U/L) enzymes, and abdominal pain. CMV infection was tested by reverse transcription polymerase chain reaction and the result was positive. CMV viremia was successfully cleared with ganciclovir. Then the absence of some of more noticeable clinical symptoms of pancreatitis may not be a decisive reason not to rule out the disease in transplanted cases.

1. Introduction

As an extremely active condition of inflammation, acute pancreatitis is a general digestive system disease. Its morbidity depends on several periods of progress. The main clinical feature is sudden pain in the left side of upper abdomen, which will extend to flanks, and vomiting and nausea are also reported in many cases[1]. Infectious diseases, surgery, excessive alcohol intake, and drug addiction have been described among etiologies of pancreatitis[2]. Although acute pancreatitis is an unusual complication in transplanted kidney cases, incidence of this digestive disease has been reported about 5%, and

mortality rate up to 50% after transplantation[3]. Also, among the infectious agents, cytomegalovirus (CMV) is a ubiquitous beta-herpes virus that can infect almost all people, particularly those who received organ transplantation. Some studies showed that CMV is also a major cause of pancreatitis in kidney transplant recipients[4]. We report CMV pancreatitis in a male kidney transplant recipient.

This is an open access journal, and articles are distributed under the terms of the Creative Commons Attribution-NonCommercial-ShareAlike 4.0 License, which allows others to remix, tweak, and build upon the work non-commercially, as long as appropriate credit is given and the new creations are licensed under the identical terms.

For reprints contact: reprints@medknow.com

©2019 Journal of Acute Disease Produced by Wolters Kluwer- Medknow

How to cite this article: Mohseni Afshar Z, Babazadeh A, Ebrahimpour S, Golmohammadi S. Acute pancreatitis with cytomegalovirus infection in a kidney transplant recipient: A case report. J Acute Dis 2019; 8(1): 43-44.

First author: Zeinab Mohseni Afshar, Department of Infectious Diseases, Faculty of Medicine, Kermanshah University of Medical Sciences, Kermanshah, Iran.

✉Corresponding author: Sima Golmohammadi, Department of Internal Medicine, Kermanshah University of Medical Sciences, Kermanshah, Iran.

E-mail: golmohammadisima05@gmail.com; s.golmohammadi@kums.ac.ir

2. Case report

A 48-year-old man with a history of kidney transplantation in the last two years was admitted to the hospital for generalized weakness. Also, he reported having nocturnal polyuria, polydipsia and mild diarrhea. He was admitted to the hospital because of nausea, vomiting and epigastric pain, with diagnosis of pancreatitis, 1 week ago.

His past medical history was remarkable for hypertension and diabetes mellitus. His drug history was marked with metformin, amlodipin, cyclosporin, prednisolone, and mycophenolate mofetil. Also, the immunosuppressive regiment for this case was cellcept 2 g/d and sandimmun 1 g/d. On examination, his vital signs were stable. His physical exam revealed 2⁺ edema, abdominal distension without tenderness or rebound and oral ulcers. His lab test findings were as follows: white blood cell count, 17 000 cells/mm³ with 85% polymorphonuclear leukocyte; Hemoglobin, 10.7 g/dL; Platelet, 313 000 g/dL; Creatinine, 102 µmol/L; Liver function tests, normal; Erythrocyte sedimentation rate, 27 mm/h, urinary albumin, normal; Urine culture, negative. Moreover, amylase and lipase enzyme levels were reported 3 370 U/L and 1 160 U/L respectively.

Abdominal ultrasonography found that the spleen and transplanted kidney were normal, although the liver size was bigger than normal one. According to ultrasonography results, magnetic resonance cholangiopancreatography was done, and the findings reported that intrahepatic bile ducts were mildly dilated (more prominent in left lobe). The common bile duct appeared normal. Pancreas had heterogenous signal and were enlarged (Figure 1). Also, in order to assess the presence of CMV, reverse transcription polymerase chain reaction (RT-PCR) was as well requested. It detected 3 884 copies/mL. CMV pancreatitis was confirmed, and ganciclovir 450 mg was administered to him twice a day for 3 weeks. Subsequently, with improved enzymes, he was discharged with oral medication, and this treatment continued until RT-PCR was negative.

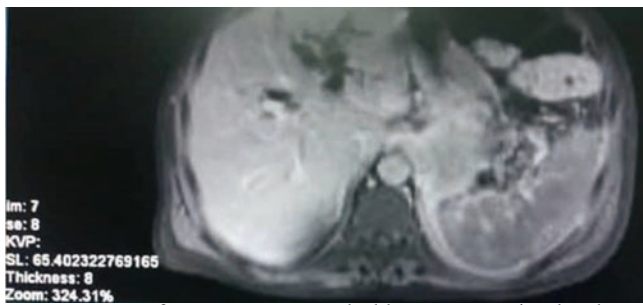


Figure 1. MRI of pancreas. Pancreas had heterogenous signal and were enlarged.

3. Discussion

Acute pancreatitis is uncommon in kidney transplant recipients, and it is associated with a poor prognosis. Although the above conclusion is not completely definitive, it seems that the most common cause of acute pancreatitis in these patients is receiving immunosuppressive drugs. On the other hand, CMV infection is a frequent cause, which can induce complication during immunosuppressive treatment[5]. Our patients received a triple immunosuppressive regiment composed of cyclosporine, prednisolone, mycophenolate mofetil, cellcept, and sandimmun, so he had a lot of risk of CMV infection.

Acute pancreatitis in renal transplant patients tends to have an insidious onset, unlike what was reported in our patient.

Although the culture has been considered the gold standard test for viral diagnosis of CMV infection[6], some other tests such as RT-PCR have high sensitivity and specificity[7]. Also, the time it takes to get the test results is much shorter than virus culture. RT-PCR was used to diagnose CMV in our patient.

Ganciclovir has the preferred agent for treatment of severe symptomatic CMV disease recipients[8,9]. The therapeutic response and improvement obtained following ganciclovir administration in our patient emphasize and confirms CMV as the probable etiological cause of pancreatitis.

To be concluded, the patient with CMV pancreatitis and elevated lipase and amylase levels, high CMV serum titers, were reported. So it is better to investigate amylase, lipase tests, and CMV serum level for kidney transplant recipients. Also, the absence of some of the more obvious clinical symptoms of pancreatitis may not be a decisive reason not to rule out the disease in transplanted patients.

Conflict of interest statement

The authors report no conflict of interest.

Acknowledgments

The authors thank Department of Infectious Diseases of Kernashah University of Medical Sciences.

References

- [1] Vaughn VM, Shuster D, Rogers MAM, Mann J, Conte ML, Saint S, et al. Early versus delayed feeding in patients with acute pancreatitis: A systematic review. *Ann Intern Med* 2017; **166**(12): 883-892.
- [2] Forsmark CE, Vege SS, Wilcox CM. Acute pancreatitis. *New Eng J M* 2016; **375**(20): 1972-1981.
- [3] Tabakovic M, Salkic NN, Bosnjic J, Alibegovic E. Acute pancreatitis after kidney transplantation. *Case Rep Transplant* 2012; **2012**: 768193.
- [4] Babazadeh A, Javanian M, Oliaei F, Akbari R, Akbarzadepasha A, Bijani A, et al. Incidence and risk factors for cytomegalovirus in kidney transplant patients in Babol, northern Iran. *Caspian J Intern Med* 2017; **8**(1): 23-29.
- [5] Luscalov S, Loga L, Dican L, Junie LM. Cytomegalovirus infection in immunosuppressed patients after kidney transplantation. *Clujul Med* 2016; **89**(3): 343-346.
- [6] Ross SA, Novak Z, Pati S, Boppana SB. Overview of the diagnosis of cytomegalovirus infection. *Infect Disord Drug Targets* 2011; **11**(5): 466-474.
- [7] de Vries JJC, van der Eijk AA, Wolthers KC, Rusman LG, Pas SD, Molenkamp R, et al. Real-time PCR versus viral culture on urine as a gold standard in the diagnosis of congenital cytomegalovirus infection. *J Clin Virol* 2012; **53**(2): 167-170.
- [8] Tan BH. Cytomegalovirus treatment. *Curr Treat Options Infect Dis* 2014; **6**(3): 256-270.
- [9] Azevedo LS, Pierrotti LC, Abdala E, Costa SF, Strabelli TMV, Campos SV, et al. Cytomegalovirus infection in transplant recipients. *Clinics (Sao Paulo, Brazil)* 2015; **70**(7): 515-523.