



Safety assessment of *Chlorophytum alismifolium* tuber extract (Liliaceae): Acute and sub-acute toxicity studies in Wistar rats

Abdulkhakar Abubakar¹, Abdullahi Balarabe Nazifi², Fatima Ismail Hassan^{1,3}, Kehinde Andem Duke¹, Theophilus Danjuma Edoh¹

¹Department of Pharmacology and Therapeutics, Ahmadu Bello University, Zaria, Nigeria

²Department of Pharmacology and Therapeutics, Bayero University, Kano, Nigeria

³Toxicology and Diseases Group, Pharmaceutical Sciences Research Center, Tehran University of Medical Sciences, Tehran, Iran

ARTICLE INFO

Article history:

Received 28 October 2018

Revision 4 December 2018

Accepted 28 December 2018

Available online 24 January 2019

Keywords:

Chlorophytum alismifolium

Toxicity studies

Biochemical parameters

Histology

ABSTRACT

Objective: To explore the toxicological profile of methanol extract of *Chlorophytum alismifolium* (MECA) tubers in Wistar rats. **Methods:** MECA was subjected to acute and sub-acute studies which were conducted according to Organization for Economic Co-operation and Development (OECD 425 and 407 guidelines respectively). In the acute toxicity experiment, a limit test (5 000 mg/kg) was administered to five rats and monitored for 2 weeks. The sub-acute studies were conducted on 4 groups of rats. The first group served as control, while the 2nd, 3rd and 4th groups received MECA (150, 300 and 600 mg/kg respectively). The treatments were given orally and daily for 4 weeks. At the end of the experiment (29th day), the animals were euthanized to obtain blood samples and organs for haematological, biochemical and histological evaluations. **Results:** Acute toxicity study showed that the oral median lethal dose was >5 000 mg/kg. In the sub-acute studies, the results showed no significant ($P>0.05$) changes in the haematological, hepatic and renal indices compared to control animals. In the fourth week, a significant ($P<0.01$) increase in body weight of the rats was observed at 150 mg/kg and 600 mg/kg compared to week one. However, there were no major changes in the organ/body weights of the rats. Histological examination of the kidney showed slight glomerular adhesion and tubular distortion. Moderate hepatic necrosis was observed at 150 mg/kg and 300 mg/kg. **Conclusions:** The results of this research revealed that the MECA tubers is virtually non-toxic after acute administration and it has low sub-acute toxicity potential in rats.

1. Introduction

The utilization of plants and their resources for combating various diseases has been known since antiquity and they are still in use worldwide[1]. Plants constitute important source of drugs[2] and according to the statistics of World Health Organization, many inhabitants of developing countries rely on natural products from plants as medications for various ailments[3]. Herbal preparations are complementary medicines for the remedy of many diseases due to

their presumed appropriateness, safety, efficacy and affordability[4].

In the past, herbal medicine has drawn remarkable interests for many studies[5], and as a justification, more investigations are conducted on medicinal plants and their constituents in order to explore their toxicity potentials, because they produce a wide range of drugs of therapeutic benefit[6,7]. Therefore, it should be a fundamental requirement to establish the harmful consequences of

This is an open access journal, and articles are distributed under the terms of the Creative Commons Attribution-NonCommercial-ShareAlike 4.0 License, which allows others to remix, tweak, and build upon the work non-commercially, as long as appropriate credit is given and the new creations are licensed under the identical terms.

For reprints contact: reprints@medknow.com

©2019 Journal of Acute Disease Produced by Wolters Kluwer- Medknow

How to cite this article: Abubakar A, Nazifi AB, Hassan FI, Duke KA, Edoh TD. Safety assessment of *Chlorophytum alismifolium* tuber extract (Liliaceae): Acute and sub-acute toxicity studies in Wistar rats. J Acute Dis 2019; 8(1): 21-27.

[✉]First and corresponding author: Abdulkhakar Abubakar, Department of Pharmacology and Therapeutics, Ahmadu Bello University, Zaria, Nigeria.
E-mail: abdulhakimevuti@gmail.com
Tel: 234-080-36412047

some of the phyto-constituents[8] and this could be achieved through toxicological studies in experimental animals[9]. Information of toxicity studies on medicinal plants or their constituents should be obtained in order to guarantee assurances in their safety to humans[10]. Thus, it is imperative to evaluate the potential toxic effects or safety profile of any medicinal plant intended to be used in animals or humans.

The genus *Chlorophytum* (Liliaceae) covers about 198 species of important medicinal plants broadly distributed in the tropical regions of the world, notably in India and Africa[11]. *Chlorophytum alismifolium* (*C. alismifolium*) (Baker), is a short stem herb that is found around stony sites in forest streams containing white flowers and tuberous root stocks[12]. The common name is Alimsa-ground lilly while the local names include *Rogon Makwarwa*, *Ekuce*, and *Cigorodi* in “Hausa”, “Agatu” and “Ffulde” languages respectively. It is extensively utilized in herbal medicine against nociception and diabetes mellitus. The antinociceptive, anti-inflammatory and anti-hyperglycaemic activities of the tubers have been reported[13,14]. Despite the widespread folk uses and pharmacological effects of *C. alismifolium*, little is known about its safety. Assessment of the toxicity profile of phyto-constituents is a vital requirement in order to assure their safety[15]. Furthermore, the increasing awareness in herbal medicine necessitates toxicity studies on products derived from medicinal plants[16]. Thus, this study intended to investigate the effects of *C. alismifolium* following 28 d repeated daily administration in rats.

2. Materials and methods

2.1. Animals

Wistar rats of either sex (100-140)g were sourced from experimental animal facility of the Faculty of Pharmaceutical Sciences, Ahmadu Bello University (A.B.U.), Zaria, Nigeria. They were managed in well-ventilated cages at room temperature under normal day and night cycle, kept on pelletized animal feed (Vital feed®, Jos) with access to water *ad libitum*. The animals were treated in accordance with the NIH Guide for the Care and Use of Laboratory Animals (NIH Publication No. 85-23, revised, 1996) and approved by institutional Research and Ethical Committee (Protocol Number: DAC/IW-OT/212-15).

2.2. Plant material

Fresh tubers of *C. alismifolium* were obtained in June, 2017 from Toro, Bauchi State, Nigeria. It was identified and authenticated in the Herbarium of the Department of Botany, A.B.U., Zaria, by Namadi Sanusi. A voucher number of 6 785 was issued by comparing with a previously deposited voucher specimen.

2.3. Plant extraction

The fresh tubers obtained were size-reduced and dried before pulverization into powder with the aid of a mortar and pestle. Two kilograms (2 kg) of the powdered plant was extracted using soxhlet apparatus with 5 L of methanol and water (in the proportion of 9:1 respectively) for 3 d. The extract obtained was subsequently concentrated over a water bath set at a temperature of 50 °C. The dried extract was weighed and labeled as methanol extract of *C. alismifolium* (MECA). It was kept in a desiccator at room temperature [(25±1.5) °C] and protected from light until further use.

2.4. Phytochemical screening

MECA was subjected to qualitative phytochemical tests as described by Evans[17] to screen for the presence or absence of secondary metabolites.

2.5. Preparation of extract and treatment

Different stock solutions of MECA were prepared using distilled water followed by serial dilution to obtain the final experimental concentrations. The solutions were freshly prepared daily and orally administered with the aid of oral gavages.

2.6. Acute toxicity studies

The median lethal dose (LD₅₀) of MECA was determined in accordance with the Organization for Economic Co-operation and Development (OECD, 425) guidelines[18] using five rats which were fasted overnight before dosing with MECA at 5 000 mg/kg orally. One rat was initially dosed and food was further withheld for 4 h. It was observed for the first 24 h and then for 14 d for signs of toxicity (changes in mucous membranes, skin, fur and eyes, circulatory, respiratory, somato-motor activity and behaviour pattern) and mortality. The remaining four rats were also dosed and observed for 2 weeks. Thereafter, the LD₅₀ was estimated.

2.7. Sub-acute toxicity studies

The study was conducted according to OECD 407 guidelines[19]. Briefly, twenty four rats were fasted overnight and then divided into four groups of six rats each. The first group of rats served as control and received distilled water 1 mL/kg. The 2nd, 3rd and 4th group were administered graded doses of MECA (150 mg/kg, 300 mg/kg and 600 mg/kg body weight respectively) daily for 28 d. The mortality and general behaviour of the rats were observed daily and their weights were recorded weekly. The rats were then euthanized on the 29th day of the experiment following mild chloroform anaesthesia. Their organs and blood samples were collected for further investigations.

2.8. Haematological indices evaluation

Blood samples for haematological evaluation were collected into ethylene diamine tetra-acetic acid containing sample bottles to prevent coagulation. Thereafter, the levels of white blood cells, lymphocytes, granulocytes, red blood cells, haemoglobin, mean corpuscular haemoglobin concentration, packed cell volume and platelets were estimated using haematology machine (Cell-Dyn, Abbott, USA).

2.9. Evaluation of biochemical parameters and electrolytes

Plain bottles were used to collect blood samples, allowed to clot and then centrifuged at 3 500 rpm for 10 min. The serums obtained were investigated to estimate the effect of MECA on biochemical indices using photoelectric colorimeter (AC-115 Optima, Japan). The parameters estimated were alanine amino transferase (ALT) and aspartate amino transferase (AST)[20], alkaline phosphatase (ALP)[21], total bilirubin[22], total protein, albumin and globulin[23], urea[24] and creatinine[25]. The effect of the extract on electrolytes (potassium, sodium, bicarbonate and chloride) was also determined with the aid of Hitachi 902 analyzer (Roche, Germany).

2.10. Evaluation of organ-body weight ratio

The kidneys, livers, pancreases and hearts of the rats were removed on the 29th day following blood collection and were cropped to remove other tissues. The organs were then placed on a saline soaked gauze and then weighed (with paired organs weighed together). The relative organ-body weight ratio was then evaluated using the relationship:

$$\text{Percentage organ-body weight ratio} = \frac{\text{Organ weight (g)}}{\text{Final body weight (g)}} \times 100\%$$

2.11. Histology

The kidneys and livers were stabled for 10 d using formaldehyde (10%). They were then dehydrated, cleared and infiltrated with paraffin wax. Thereafter, they were embedded before sectioning. With the aid of a microtome, 5 μ m sections of the organs were made, placed on a slide and stained with haematoxylin and eosin. The stained sections were finally viewed under a microscope for morphological changes[26].

2.12. Statistical analyses

Data generated from the experiments were entered into SPSS software (Version 20). Descriptive statistics was carried out to obtain the mean \pm SEM. Data on relative organ body weight,

haematological, hepatic and renal indices were analyzed by one way analysis of variance (ANOVA) while those on body weight were analyzed using repeated measure ANOVA and Bonferroni test for comparison over time. Statistical significant differences were considered at 95% confidence interval ($P < 0.05$).

3. Results

3.1. Extractive value and phytochemical constituents

The MECA obtained was gummy in nature with a honey-like aroma. The extraction of 2 000 g of the powdered plant material produced 104.2 g of the extract corresponding to the yield of 5.21 %(w/w). Screening for phytochemical constituents showed the presence of flavonoids, alkaloids, triterpenes, saponins, glycosides and cardiac glycosides.

3.2. Effect of acute administration of MECA on general behaviour and mortality

The oral administration of MECA produced no visible signs of toxicity and mortality throughout the study period. The LD₅₀ was thus found to be above 5 000 mg/kg.

3.3. Effect of 28-days daily administration of MECA on general behaviour and mortality

Oral administration of MECA (150 mg/kg, 300 mg/kg and 600 mg/kg) did not induce any mortality. There were also no observable changes in behaviour throughout the study period when compared to the control group.

3.4. Effect of 28-days daily administration of MECA on body weights

The administration of MECA did not produce significant ($P > 0.05$) changes in the body weights of the rats when compared to control group. However, a significant ($P < 0.01$) increase in the body weights was observed at 150 mg/kg in the fourth week compared to the first week. Similarly, a significant increase ($P < 0.05$ and $P < 0.01$) was observed at 600 mg/kg in weeks three and four respectively (Figure 1; Table 1).

Table 1

Effect of 28 d administration of MECA on body weights of rats.

Treatment	Mean body weights (g)			
	Week 1	Week 2	Week 3	Week 4
D/W(1 mL/kg)	137.67 \pm 08.83	145.67 \pm 14.60	151.00 \pm 12.96	152.50 \pm 12.70
CAE(150 mg/kg)	132.25 \pm 06.09	139.50 \pm 10.84	150.00 \pm 07.70	164.50 \pm 09.97*
CAE(300 mg/kg)	113.50 \pm 06.40	122.25 \pm 6.98	127.75 \pm 06.04	127.50 \pm 06.06
CAE(600 mg/kg)	116.00 \pm 10.57	125.00 \pm 8.76	134.50 \pm 11.45*	144.00 \pm 12.07**

Values are presented as mean \pm SEM; * : $P < 0.05$, ** : $P < 0.01$ compared to week 1-Repeated measure ANOVA followed by Bonferroni post hoc test, $n=6$, D/W: Distilled water; CAE: *C. alismifolium* extract.

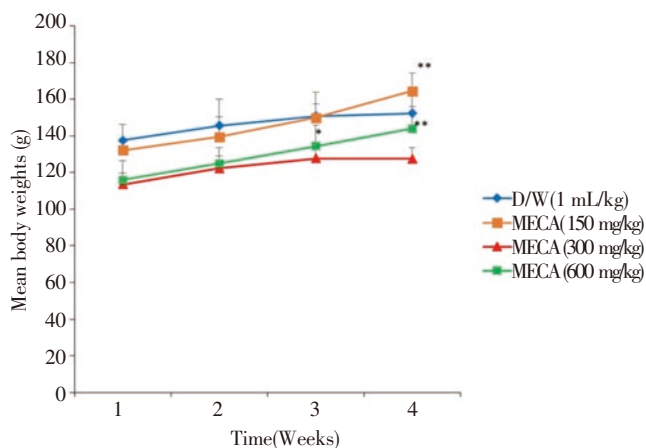


Figure 1. Effect of 28 d daily administration of methanol extract of *C. alismifolium* on body weights of rats. Values are presented as mean \pm SEM; *: $P < 0.05$; **: $P < 0.01$ compared to week 1-Repeated measure ANOVA followed by Bonferroni post hoc test, $n=6$; D/W: Distilled water.

3.5. Effect of 28-days daily administration of MECA on relative organ-body weights

The administration of MECA did not produce a significant ($P > 0.05$) increase or decrease in the relative organ/body weights as compared to control group (Table 2).

Table 2

Effect of 28 d oral administration of MECA on relative organ body weights of rats.

Treatment	Relative organ to body weight ratio (%)			
	Kidney	Liver	Heart	Pancreas
D/W (1 mL/kg)	1.13 \pm 0.17	5.19 \pm 0.40	0.65 \pm 0.06	0.74 \pm 0.09
CAE (150 mg/kg)	0.87 \pm 0.05	3.97 \pm 0.19	0.50 \pm 0.04	0.53 \pm 0.01
CAE (300 mg/kg)	1.09 \pm 0.04	3.73 \pm 0.24	0.52 \pm 0.00	0.59 \pm 0.01
CAE (600 mg/kg)	0.90 \pm 0.04	4.44 \pm 0.37	0.59 \pm 0.04	0.47 \pm 0.06

Values are presented as mean \pm SEM, no significant differences compared to distilled water (D/W) control group-One way ANOVA, $n=3$; CAE: *C. alismifolium* extract.

Table 3

Effect of 28 d administration of MECA on haematological parameters in rats.

Treatment	WBC($\times 10^9$ /L)	LYMP(%)	GRAN(%)	HGB(g/dL)	RBC($\times 10^{12}$ /L)	PCV(%)	MCHC(g/dL)	PLT($\times 10^9$ /L)
D/W (1 mL/kg)	13.82 \pm 1.98	56.28 \pm 4.46	35.85 \pm 4.65	13.80 \pm 0.32	7.46 \pm 0.32	45.38 \pm 0.90	30.37 \pm 0.37	284.83 \pm 18.03
CAE (150 mg/kg)	10.08 \pm 1.55	42.05 \pm 5.91	44.43 \pm 5.75	14.67 \pm 0.29	7.84 \pm 0.05	45.60 \pm 0.92	32.08 \pm 0.12	282.17 \pm 19.10
CAE (300 mg/kg)	10.73 \pm 2.79	43.25 \pm 3.97	37.50 \pm 2.50	13.88 \pm 0.64	7.26 \pm 0.69	43.05 \pm 2.68	32.23 \pm 0.73	283.75 \pm 25.63
CAE (600 mg/kg)	15.14 \pm 0.60	48.80 \pm 4.37	37.06 \pm 5.37	13.60 \pm 0.57	7.21 \pm 0.39	44.46 \pm 1.71	30.54 \pm 0.54	281.40 \pm 40.43

Values are presented as mean \pm SEM, and no significant difference compared to distilled water (D/W) control-One way ANOVA, $n=6$; CAE: *C. alismifolium* extract; WBC: White blood cell; LYMP: Lymphocytes; GRAN: Granulocytes; HGB: Haemoglobin; RBC: Red blood cells; PCV: Packed cell volume; MCHC: Mean corpuscular haemoglobin concentration; PLT: Platelets.

Table 4

Effect of 28 d administration of MECA on hepatic indices in rats.

Treatment (mg/kg)	AST(I.U/L)	ALT(I.U/L)	ALP(I.U/L)	TB(mg/dL)	TP(mg/dL)	ALB(mg/dL)	GLB(mg/dL)
D/W (1 mL/kg)	30.00 \pm 1.39	14.17 \pm 1.40	30.08 \pm 0.93	17.00 \pm 0.03	6.31 \pm 0.18	2.71 \pm 0.04	3.60 \pm 0.16
CAE (150 mg/kg)	25.00 \pm 1.52	15.20 \pm 1.24	47.13 \pm 11.31	19.25 \pm 4.20	5.57 \pm 0.25	2.74 \pm 0.07	2.83 \pm 0.22
CAE (300 mg/kg)	27.00 \pm 1.87	13.25 \pm 0.85	28.99 \pm 4.45	18.62 \pm 0.01	6.01 \pm 0.18	2.62 \pm 0.21	3.39 \pm 0.18
CAE (600 mg/kg)	35.66 \pm 3.68	18.00 \pm 1.32	28.82 \pm 2.54	19.17 \pm 3.07	6.40 \pm 0.24	2.71 \pm 0.11	3.68 \pm 0.32

Values are presented as mean \pm SEM. There was no significant differences compared to distilled water (D/W) control group-One way ANOVA, $n=6$; TB: Total bilirubin; TP: Total protein; ALB: Albumin; GLB: Globulin; CAE: *C. alismifolium* extract; I.U.: International unit.

3.6. Effect of 28-days daily administration of MECA on haematological parameters

Administration of MECA produced no significant ($P > 0.05$) changes in the tested haematological parameters as compared to control group (Table 3).

3.7. Effect of 28-days daily administration of MECA on hepatic indices

Administration of *C. alismifolium* extract did not produce significant ($P > 0.05$) changes in the liver enzymes, total bilirubin and proteins as compared to control group (Table 4).

3.8. Effect of 28-days daily administration of MECA on renal indices

Administration of *C. alismifolium* extract did not produce significant ($P > 0.05$) changes in the levels of urea, creatinine and serum electrolytes as compared to control group (Table 5).

3.9. Effects of 28-days daily administration of MECA on histology of the kidneys and livers

Histological examination of the kidneys revealed slight adhesion in the glomerulus and distortion of the tubules at 150 mg/kg of the extract. Slight glomerular distortion and lymphocyte hyperplasia were observed at 300 mg/kg and 600 mg/kg respectively (Figure 2). Moderate hepatic necrosis was observed with the doses of 150 mg/kg and 300 mg/kg respectively, however, there were no histopathological changes in the hepatocytes at 600 mg/kg (Figure 3).

Table 5

Effect of 28 d oral administration of MECA on renal indices and electrolytes in rats.

Treatment	Urea(mmol/L)	Creatinine(μ mol/L)	Sodium(mmol/L)	Potassium(mmol/L)	Chloride(mmol/L)	Bicarbonate(mmol/L)
D/W (1 mL/kg)	37.33 \pm 3.07	1.07 \pm 0.11	155.47 \pm 15.79	13.21 \pm 0.80	26.00 \pm 1.59	81.50 \pm 2.88
CAE (150 mg/kg)	42.87 \pm 4.14	1.42 \pm 0.16	155.00 \pm 15.40	10.13 \pm 0.59	29.80 \pm 2.63	88.20 \pm 4.88
CAE (300 mg/kg)	34.81 \pm 1.77	0.95 \pm 0.06	158.84 \pm 23.61	12.24 \pm 1.30	24.50 \pm 1.94	81.50 \pm 5.84
CAE (600 mg/kg)	29.75 \pm 1.64	0.88 \pm 0.09	120.00 \pm 6.11	12.48 \pm 0.62	26.00 \pm 1.83	87.17 \pm 1.85

Values are presented as mean \pm SEM; no significant differences compared to distilled water (D/W) control group—One way ANOVA, n=6; CAE: *C. alismifolium* extract.

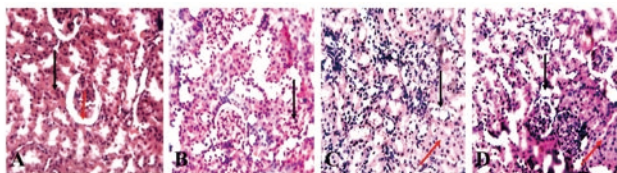


Figure 2. Photomicrograph of the kidney sections of rats administered distilled water and MECA for 28 d. A: Distilled water treated group showing normal tubules (black arrow) and glomerulus (red arrow). B: MECA 150 mg/kg treated group showing moderate tubular adhesion. C: MECA 300 mg/kg treated group showing slight glomerular distortion (black arrow) and moderate tubular adhesion (red arrow). D: MECA 600 mg/kg treated group showing slight lymphocyte hyperplasia (black arrow) and slight tubular distortion (red arrow). (H and E, magnification \times 250).

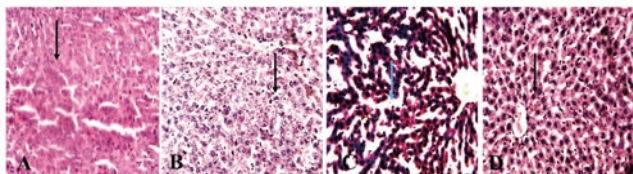


Figure 3. Photomicrograph of the liver sections of rats administered distilled water and MECA for 28 d. A: Distilled water treated group showing normal hepatocytes. B: MECA 150 mg/kg treated group showing moderate vacuolations and necrosis. C: MECA 300 mg/kg treated group showing moderate hepatic necrosis (blue arrow). D: MECA 600 mg/kg treated group showing normal hepatocytes. (H and E, magnification \times 250).

4. Discussion

The use of herbal medicines as a source of drugs has gained wide acceptability globally, especially in low and middle-income countries[27]. Medicinal plants are known for containing varying pharmacologically active constituents[28]. Although these plants may elicit numerous pharmacological activities, much is unknown about their potential to cause toxicity. Acute toxicity studies on *C. alismifolium* extract showed that it is practically non-toxic in rats following oral administration. This finding is corroborative with previous studies on the plant extract[13,14]. The tubers of *C. alismifolium* have also been reported to possess bioactive compounds which could be beneficial in hyperglycaemic, painful and inflammatory conditions[13,14]. Some of these bioactive constituents like phenolic compounds are phytochemical antioxidants with potentials for inhibiting reactive oxygen species implicated in the pathogenesis of many diseases and toxicities[29]. Despite these therapeutic benefits, there are no reports on its toxicological profile following repeated administration. This study therefore presents useful information on the sub-acute toxicity

profile of *C. alismifolium* tuber extract.

Variation in body weights is an indication of toxic effects of chemicals[30,31]. In this research, administration of *C. alismifolium* extract did not reduce the body weights of the animals suggesting that it did not exert any deteriorative effect on their growth. Furthermore, the significant increase in the body weights over time showed that MECA did not impair feed utilization of the rats. Similarly, the extract did not alter the organ weights of the rats and could therefore be considered non-toxic because reductions in the weights are sensitive markers of toxicity[32].

The haematopoietic system is a susceptible target for toxic compounds, especially in the bone marrow where the production of red blood cells occurs[33]. Haematological indices are commonly used markers of toxicity as a result of the interaction between a toxin and its potential metabolites on cellular components[34]. In this research, administration of graded doses of MECA did not cause significant changes on the haematological indices when compared with control group, thus, suggesting that it may be non-toxic to the blood system.

The liver and kidneys are crucial organs that perform significant role in detoxification[35]. The main organ for xenobiotics metabolism is the liver where compounds or hepatotoxic metabolites may be formed[36]. An increase in the levels of liver enzymes (AST, ALT and ALP) is conventionally an indication of liver injury[37]. Administration of graded doses of tuber extract of *C. alismifolium* did not produce major effects on the serum levels of liver enzymes, bilirubin and proteins in the experimental animals when compared with control. This indicates that the functions of the liver is not affected by the extract after 28 d treatment. Creatinine and urea are regarded as important markers of renal malfunction[38] and are used in diagnosing kidneys' function or monitor clinical outcome of a therapy[39]. In this research, the lack of substantial changes in these parameters and serum electrolytes is a suggestion that *C. alismifolium* tuber extract has no harmful effect on the kidneys.

No marked changes were observed in the histo-morphology of organs following 28 d oral administration of *C. alismifolium*. However, slight to moderate histopathological alterations were observed in the liver and kidneys of rats in the extract treated groups. Considering the liver, levels of ALT and AST which are the major indicators of liver injury were not significantly altered. Therefore, these changes may not be significant toxicologically, since they were not supported by some of the findings from biochemical analysis.

The results obtained showed that *C. alismifolium* tuber extract is practically non-toxic after acute administration and produced low toxicity after 28 d repeated administration. The MECA did not elicit systemic toxicity, however, slight to moderate histomorphological changes were observed in the kidneys and liver. Therefore, there is need to conduct chronic toxicity studies in order to ascertain its long term effects.

Conflict of interest statement

The authors report no conflict of interest statement.

References

- [1] Abe R, Ohtani K. An ethnobotanical study of medicinal plants and traditional therapies on Batan Island, the Philippines. *J Ethnopharmacol* 2013; **145**(2): 554-565.
- [2] Ekor M. The growing use of herbal medicines: issues relating to adverse reactions and challenges in monitoring safety. *Front Pharmacol* 2014; **4**: 177.
- [3] World Health Organization. The world traditional medicines situation, in traditional medicines: Global situation, issues and challenges. *Geneva* 2011; **3**: 1-14.
- [4] Arya A, Mahmood AA, Batoul SH, Mustafa AM. Screening for hypoglycemic activity on the leaf extracts of nine medicinal plants: *In-vivo* evaluation. *E-J Chem* 2012; **9**(3): 1196-1205.
- [5] Mazid M, Khan TA, Mohammad F. Medicinal plants of rural India: A review of use by Indian folks. *Indo Glob J Pharm Sci* 2012; **2**(3): 286-304.
- [6] Subramanian K, Sankaramourthy D, Gunasekaran M. Toxicity studies related to medicinal plants. In: Mandal SC, Mandal V, Konishi T, (eds). *Natural products and drug discovery: An integrated approach*. UK: Elsevier; 2018, p. 491-505.
- [7] Patil UH, Gaikwad DK. Phytochemical profile and antibacterial activity of stem bark of *Anogeissus latifolia*. *Pharmacog J* 2010; **2**(17): 70-73.
- [8] Teke GN, Kuete V. Acute and subacute toxicities of African medicinal plants. In: Kuete V (ed). *Toxicological survey of African medicinal plants*. USA: Elsevier; 2014, p.63-98.
- [9] Ekeanyanwu RC, Njoku OU. Acute and subacute oral toxicity study on the flavonoid rich fraction of *Monodora tenuifolia* seed in albino rats. *Asian Pac J Trop Biomed* 2014; **4**(3): 194-202.
- [10] Ukwuani AN, Abubakar MG, Hassan SW, Agaie BM. Toxicological studies of hydromethanolic leaves extract of *Grewia crenata*. *Int J Pharm Sci Drug Res* 2012; **4**(4): 245-249.
- [11] Devendra S, Bhagirath P, Joshi YM, Vilasra O. Pharmacological aspect of *Chlorophytum borivilianum* (*Safed musli*). A review. *Int J Res Pharm Chem* 2012; **2**: 2231-2781.
- [12] Abubakar A, Danjuma NM, Chindo BA, Nazifi AB. Ameliorative effects of methanol tuber extract of *Chlorophytum alismifolium* Baker on hyperglycaemia-induced haematological and hepatorenal alterations in rats. *Nig J Pharm Sci* 2017; **16**(2): 30-39.
- [13] Abubakar A, Danjuma NM, Odoma S, Nazifi AB. Antinociceptive and anti-inflammatory activities of the methanol extract of *Chlorophytum alismifolium* tubers. *J Pharm Biores* 2016; **13**: 155-162.
- [14] Abubakar A, Danjuma NM, Chindo BA, Nazifi AB. Anti-hyperglycaemic activity of tuber extract of *Chlorophytum alismifolium* Baker in streptozotocin-induced hyperglycaemic rats. *Bull Fac Pharm Cairo Univ* 2018; **56**(1): 60-67.
- [15] Li Y, Li G, Song M, Li X, Zhan X, Lu J, et al. Acute toxicity study of *Aspidopterys obcordata* aqueous extract in Sprague-Dawley rats. *J Tradit Chin Med* 2016; **36**(3): 377-381.
- [16] Pelkonen O, Xu Q, Fan T. Why is research on herbal medicinal products important and how can we improve its quality?. *J Tradit Complement Med* 2014; **4**(1): 1-7.
- [17] Evans WC. In: Daphne Evans (ed). *Trease and evans pharmacognosy*. 16th ed. London: Elsevier; 2009.
- [18] Saleem U, Amin S, Ahmad B, Azeem H, Anwar F, Mary S. Acute oral toxicity evaluation of aqueous ethanolic extract of *Saccharum munja* Roxb. roots in albino mice as per OECD 425 TG. *Toxicol Rep* 2017; **4**: 580-585.
- [19] Traesel GK, de Souza JC, de Barros AL, Souza MA, Schmitz WO, Muzzi RM, et al. Acute and subacute (28 days) oral toxicity assessment of the oil extracted from *Acrocomia aculeata* pulp in rats. *Food Chem Toxicol* 2014; **74**: 320-325.
- [20] Reitman S, Frankel S. A colorimetric method for the determination of serum glutamic oxaloacetic and glutamic pyruvic transaminase. *Am J Clin Pathol* 1957; **28**(1): 56-63.
- [21] Belfield A, Goldberg D. Colorimetric determination of alkaline phosphatase activity. *Enzyme* 1971; **12**: 561-566.
- [22] Walters MI, Gerard HW. An ultramicro method for the determination of conjugated and total bilirubin in serum or plasma. *Microchem J* 1970; **15**(2): 231-243.
- [23] Doumas BT, Watson WA, Biggs HG. Albumin standards and the measurement of serum albumin with bromocresol green. *Clin Chim Acta* 1971; **31**(1): 87-96.
- [24] Weatherburn MW. Phenol-hypochlorite reaction for determination of ammonia. *Anal Chem* 1976; **39**: 971-974.
- [25] Bartels H, Bohmer M, Heierli C. Serum creatinine determination without protein precipitation. *Clin Chim Acta* 1972; **37**: 193-197.
- [26] Rolls G. *Microtomy and paraffin section preparation*. Germany: Leica Biosystem, Wetzlar; 2011.
- [27] Vaghasiya YK, Shukla VJ, Chanda S. Acute oral toxicity study of *Pluchea arguta* Boiss extract in mice. *J Pharmacol Toxicol* 2011; **6**: 113-123.
- [28] Saha P, Mazumber UK, Halder PK, Islam A, Kumar SRB. Evaluation of acute and subchronic toxicity of *Legenaria siceraria* aerial part. *Int J Pharm Sci Res* 2011; **2**: 1507-1512.
- [29] Aboonabi A, Rahmat A, Othman F. Effects of pomegranate on histopathology of liver and kidney on generated oxidative stress diabetic induced rats. *J Cytol Histol* 2014; **6**: 1-5.
- [30] Nandy S, Datta R. Acute and subacute toxicity studies of methanolic leaves extract of *Pterospermum acerifolium* L wild in rodents. *Int J Pharm Life Sci* 2012; **3**: 1519-1529.
- [31] Hayelom K, Mekbeb A, Eyasu M, Wondwossen E, Kelbesa U.

- Methanolic effect of *Clerodendrum myricoides* root extract on blood, liver and kidney tissues of mice. *Afr Health Sci* 2012; **12**: 489-497.
- [32] Waller DG, Sampson AP. Medical pharmacology and therapeutics. 5th ed. China: Elsevier; 2018.
- [33] Kifayatullah M, Mustafa MS, Sengupta P, Sarker MMR, Das A, Das SK. Evaluation of the acute and sub-acute toxicity of the ethanolic extract of *Pericampylus glaucus* (Lam.) Merr. in BALB/c mice. *J Acute Dis* 2015; **4**(4): 309-315.
- [34] Arika WM, Nyamai DW, Musila MN, Ngugi MP, Njagi EN. Hematological markers of *In vivo* toxicity. *J Hematol Thrombo Dis* 2016; **4**(2): 1-7.
- [35] Harizal SN, Mansor SM, Hasnan J, Tharakan JK, Abdullah J. Acute toxicity study of the standardized methanolic extract of *Mitragyna speciosa* Korth in rodent. *J Ethnopharmacol* 2010; **131**: 404-409.
- [36] Rhiouani H, El-Hilaly J, Israili ZH, Lyoussi B. Acute and sub-chronic toxicity of an aqueous extract of the leaves of *Herniaria glabra* in rodents. *J Ethnopharmacol* 2008; **118**: 378-386.
- [37] Chavda R, Valadia KR, Gokani R. Hepatoprotective and antioxidant activity of root bark of *Calotropis procera* R. Br (Asclepiaceae). *Int J Pharmacol* 2010; **6**: 937-943.
- [38] Sood MM, Saeed M, Lim V, Cordova F, Komenda P, Malik A. The urea-to-creatinine ratio is predictive of worsening kidney function in ambulatory heart failure patients. *J Cardiac Failure* 2015; **21**(5): 412-418.
- [39] Gowda S, Desai PB, Kulkarni SS, Hull VV, Math AA, Vernekar SN. Markers of renal function tests. *N Am J Med Sci* 2010; **2**: 170-173.