



Acute dengue hypokalemic paralysis complicated by hypomagnesemia

Durgesh Pushkar, Bidyut Roy[✉], Hirdesh Chawla, Tauhid Ahmad

Department of Medicine, King George Medical University, U. P. Lucknow, India

ARTICLE INFO

Article history:

Received 24 January 2018

Revision 9 July 2018

Accepted 16 November 2018

Available online 21 December 2018

Keywords:

Dengue

Hypokalemia

Hypomagnesemia

Quadripareisis

Acute

ABSTRACT

Endemic to over 100 countries dengue virus infection has now become the most rapidly spreading mosquito-borne disease in the world. Dengue symptoms range from minor flu-like symptoms to major complications like bleeding, shock, and rarely death due to organ failure. Atypical manifestations of neurological, cardiovascular, gastrointestinal origin are collectively grouped into the expanded dengue syndrome. Acute motor quadripareisis have been reported in several cases of dengue infection. We report a rare and non-fatal case of motor quadripareisis due to hypokalemia complicated by associated hypomagnesemia in a dengue positive patient.

1. Introduction

Dengue virus infection has emerged as a major global health concern in the recent years. With over 3 billion people at risk, dengue virus results in significant morbidity and mortality every year in all regions of world especially in the tropics and sub tropics. It is caused by 4 serotypes of the same virus belonging to family flaviviridae. Apart from the common complications namely dengue hemorrhagic fever and dengue shock syndrome, patients may present with myriad of manifestation which may be neurological, cardiovascular, gastrointestinal and others, collectively grouped as expanded dengue syndrome. Acute

motor quadripareisis has been reported in about 3%-13% cases of dengue[1,2]. The main differentials include hypokalemic paralysis, Guillain–Barre syndrome, transverse myelitis, and acute disseminated encephalomyelitis. Hypokalemic quadripareisis with hypomagnesemia in dengue is a rare association with only one case reported in the literature[3].

2. Case report

This is an open access journal, and articles are distributed under the terms of the Creative Commons Attribution-NonCommercial-ShareAlike 4.0 License, which allows others to remix, tweak, and build upon the work non-commercially, as long as appropriate credit is given and the new creations are licensed under the identical terms.

For reprints contact: reprints@medknow.com

©2018 Journal of Acute Disease Produced by Wolters Kluwer- Medknow

How to cite this article: Pushkar D, Roy B, Chawla H, Ahmad T. Acute dengue hypokalemic paralysis complicated by hypomagnesemia. J Acute Dis 2018; 7(6): 262-264.

[✉]Corresponding author: Dr. Bidyut Roy, MD, Senior Resident, Department of Medicine, King George Medical University, U. P. Lucknow, India.
E-mail: bidyutroy451@gmail.com
Tel: 09956774362

A 22 year old male presented to emergency department with weakness in all four limbs that had progressed acutely in last 48 hours. There was a history of moderate to high grade fever associated with chills and myalgia 3 d ago. There was no history of diarrhoea, facial weakness, shortness of breath, swallowing difficulty, or bladder bowel disturbance. There was no history of any other illnesses like thyroid disorder, diabetes and hypertension, no significant drug and family history. On examination, he was conscious, oriented, afebrile, and had stable vitals. Neurological examination revealed areflexic, acute flaccid, pure motor symmetrical, quadriparesis with power of 1/5 in all four limbs (proximal >distal) on the Medical Research Council scale. His single breath count was 18 per minute. There was no sensory involvement and plantar response was flexor bilaterally. On arterial blood gas analysis the pH was 7.40, normal bicarbonate, normal anion gap but potassium was 1.62 meq/L. Random sugar was 148 mg/dL. Electrocardiogram was done which revealed a heart rate of 75 beats per minute and flattening of T waves (Figure 1). A provisional diagnosis of hypokalemic paralysis was made. Intravenous potassium correction was started promptly to prevent further complication. Hypokalemic periodic paralysis was ruled out by negative history of similar episode in past and negative family history. Also there was no history suggestive of any acute stress, consumption of high carbohydrate diet which would have triggered an episode of periodic paralysis. On laboratory investigation haematocrit was 48%, hemoglobin was 12.1 g/dL, white blood cell count was 4 100/cumm, platelets were 0.80 lacs/cc, creatine phosphokinase was 430 IU/L. Testing for HIV, hepatitis B surface antigen, and hepatitis C antibodies was negative. Thyrotoxicosis periodic paralysis was ruled out by thyroid function tests which came out to be normal with normal anti-TPO antibody titres. Renal tubular acidosis and Gitelman syndrome were ruled out by a normal arterial pH and normal urinary potassium. Guillain-Barre syndrome and myelitis were excluded by clinical examination and nerve conduction studies which were normal. Thus work up of hypokalemia did not reveal any specific known causes. Taking fever into consideration dengue NS1 antigen testing was done which was positive while dengue IgM and IgG were negative. He was thus considered as a case of dengue induced hypokalemic paralysis. However, despite an adequate intravenous potassium correction, his weakness was not improved and a repeat potassium level came out to be 2.03 mmol/L after 4-6 h. In view of persistent hypokalemia, serum magnesium values were sent which came out to be 0.46 mmol/L. The patient thus had significant hypomagnesemia which was even evident on the electrocardiogram as prolonged QT interval. The patient was supplemented with intravenous magnesium sulphate and during the next 12 h the patient's symptoms started improved with full recovery of motor weakness and serum potassium and magnesium returning to normal values on the 2nd day. The patient was kept admitted for 5 d during which dengue IgM was repeated, and turned positive on 5th day. On discharge his haematocrit was normal and platelet counts were 1.6 lacs, he was advised for follow up.

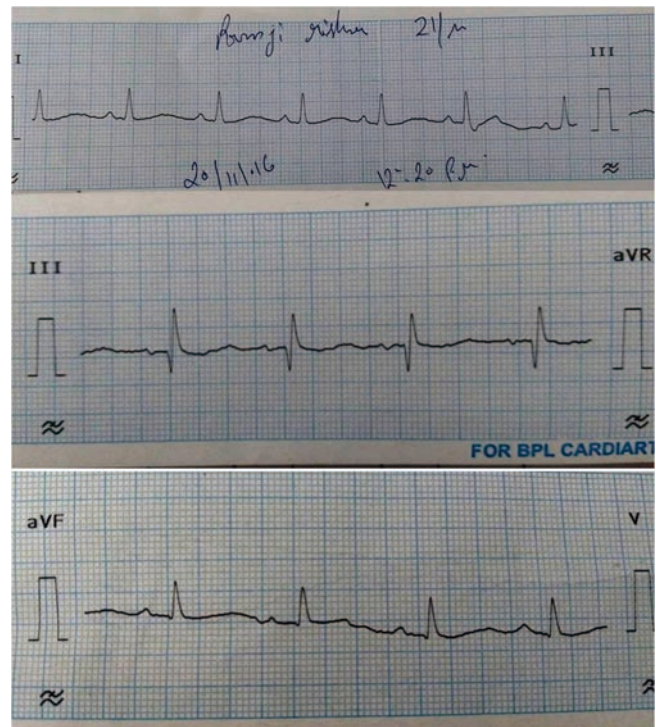


Figure 1. Electrocardiogram revealing a heart rate of 75 beats per minute and flattening of T waves.

The patient was discharged on 6th day with full power in all four limbs and normal haematocrit and normal platelet count. No symptoms were reported on follow up visit.

3. Discussion

Hypokalemia is a known electrolyte abnormality in patients of dengue fever, its prevalence has been found to vary from 14% to 28%[4,5]. Dengue hypokalemic paralysis cases have been reported during dengue epidemics. In a study done in 88 dengue patients, 12 patients had acute quadriparesis and out of them 10 were cases of dengue hypokalemic paralysis[1]. In a retrospective study done in 58 patients of hypokalemic paralysis, there were 18 cases of dengue hypokalemic paralysis[5]. Dengue was the second most common cause of hypokalemic paralysis in a retrospective study of 29 hypokalemic paralysis patient[2]. In another study dengue was the cause of hypokalemic paralysis in only 1 out of 24 patients of secondary hypokalemia[6]. Our case findings which were consistent with the other reported cases showed occurrence of symptoms in the initial stages of illness and a complete recovery after treatment[3,7-10]. This signifies that hypokalemia is an acute but treatable complication. It is still not established whether hypokalemic paralysis has a causal or an incidental relation with dengue. However, several mechanisms have been postulated that include transient renal tubular defects, intracellular shift of potassium in response to release of cytokines, insulin and catecholamine in infection induced stress and inflammation[3,7-10]. An exact etiopathological mechanism still

needs to be investigated. One rare finding that existed in our patient was presence of hypomagnesemia. Hypomagnesemia has been reported in association with dengue hypokalemic paralysis in only one case[3]. Hypomagnesemia is known to occur in critical illnesses and its presence may result in complications such as hypokalemia, hypocalcemia, tetany, seizures and cardiac arrhythmias[11,12]. Coexistent magnesium deficiency complicates hypokalemia and renders it refractory to potassium supplementation. A decrease in intracellular magnesium, resulting from magnesium deficiency releases the magnesium-mediated inhibition of renal outer medullary K⁺ channels and increases potassium secretion in the distal tubules thus aggravating hypokalemia[13,14]. The exact mechanism of hypomagnesemia in dengue could not be delineated but can be attributed to poor renal reabsorption, a mechanism similar to as found in Gitelman syndrome.

This case report highlights the importance of significant electrolyte abnormalities that may exist as complications of dengue fever. Further research is required to firmly establish the exact aetiological mechanism of hypokalemia and hypomagnesemia in dengue. With this case report we emphasise ruling out hypomagnesemia along with hypokalemia and treating it promptly in patients with dengue related acute motor weakness and in any patient with refractory hypokalemia.

Conflict of interest statement

The authors report no conflict of interest.

References

- [1] Hira HS, Kaur A, Shukla A. Acute neuromuscular weakness associated with dengue infection. *J Neurosci Rural Pract* 2012; **3**(1): 36-39.
 [2] Garg RK, Malhotra HS, Verma R, Sharma P, Singh MK. Etiological

- spectrum of hypokalemic paralysis: A retrospective analysis of 29 patients. *Ann Indian Acad Neurol* 2013; **16**(3): 365-370.
 [3] Jain RS, Gupta PK, Agrawal R, Kumar S, Khandelwal K. An unusual case of dengue infection presenting with hypokalemic paralysis with hypomagnesemia. *J Clin Virol* 2015; **69**: 197-199.
 [4] Tomar LR, Raizada A, Yadav A, Agarwal S. Dengue fever presenting as hypokalemic muscle weakness. *Trop J Med Res* 2016; **19**: 76-78.
 [5] Jain RS, Handa R, Prakash S, Nagpal K, Gupta P. Acute hypokalemic quadriparesis: An atypical neurological manifestation of dengue virus. *J Neurovirol* 2014; **20**(1): 103-104.
 [6] Maurya P, Kulshreshtha D, Singh A, Thacker A. Rapidly resolving weakness related to hypokalemia in patients infected with dengue virus. *J Clin Neuromusc Dis* 2016; **18**(2): 72-78.
 [7] Gupta N, Garg A, Chhabra P. Dengue infection presenting as acute hypokalemic quadriparesis. *J Postgrad Med* 2014; **60**: 327-328.
 [8] Widodo D, Setiawan B, Chen K, Nainggolan L, Santoso WD. The prevalence of hypokalemia in hospitalized patients with infectious diseases problem at CiptoMangunkusumo Hospital, Jakarta. *Acta Med Indones* 2006; **38**: 202-205.
 [9] Verma R, Patil TB, Lalla R. Hypokalemic paralysis associated with dengue fever: Study from a tertiary centre in North India. *Neurol Asia* 2016; **21**(1): 23-32.
 [10] Kayal AK, Goswami M, Das M, Jain R. Clinical and biochemical spectrum of hypokalemic paralysis in North: East India. *Ann Indian Acad Neurol* 2013; **16**(2): 211-217.
 [11] Zafar MSH, Wani JI, Karim R, Mir MM, Koul PA. Significance of serum magnesium levels in critically ill-patients. *Int J Appl Basic Med Res* 2014; **4**(1): 34-37.
 [12] Velissaris D, Karamouzou V, Pierrakos C, Aretha D, Karanikolas M. Hypomagnesemia in critically ill sepsis patients. *J Clin Med Res* 2015; **7**(12): 911-918.
 [13] Huang CKuo E. Mechanism of hypokalemia in magnesium deficiency. *J Am Soc Nephrol* 2007; **18**(10): 2649-2652.
 [14] Yang L, Frindt G, Palmer LG. Magnesium modulates ROMK channel-mediated potassium secretion. *J Am Soc Nephrol* 2010; **21**(12): 2109-2116.