



doi: 10.4103/2221-1691.254603

©2019 by the Asian Pacific Journal of Tropical Biomedicine.

## Phytochemical studies and anti-ulcerative colitis effect of *Moringa oleifera* seeds and Egyptian propolis methanol extracts in a rat model

Attia H. Atta<sup>1</sup>✉, Samar M. Mounair<sup>1</sup>, Soad M. Nasr<sup>2</sup>, Doaa Sedky<sup>2</sup>, Amany M. Mohamed<sup>2</sup>, Shima A. Atta<sup>3</sup>, Hassan Mohamed Desouky<sup>4</sup>

<sup>1</sup>Department of Pharmacology, Faculty of Veterinary Medicine, Cairo University, Giza, 12211, Egypt

<sup>2</sup>Department of Parasitology & Animal Diseases, National Research Centre, 33 Bohouth St., Dokki, Giza, 12622, Egypt

<sup>3</sup>Immunology Department, Theodor Bilharz Research Institute, Giza, 12411, Egypt

<sup>4</sup>Department of Animal Reproduction and Artificial Insemination, National Research Centre, 33 Bohouth St., Dokki, 12622, Giza, Egypt

### ARTICLE INFO

#### Article history:

Received 26 December 2018

Revision 30 January 2019

Accepted 12 March 2019

Available online 22 March 2019

#### Keywords:

*Moringa oleifera* seeds

Propolis

Ulcerative colitis

Phytochemical

### ABSTRACT

**Objective:** To analyze the phytochemical constituents, and to explore potential protective effect of the methanol extract of *Moringa oleifera* (*M. oleifera*) seeds and Egyptian propolis, each alone or concurrently administered on acetic acid-induced ulcerative colitis in rats.

**Methods:** Eight groups of 5 rats each were used: normal control group with distilled water, model group, two groups with *M. oleifera* seeds (100 and 200 mg/kg), two groups with propolis (50 and 100 mg/kg), one group with concurrent administration of both, and one group with prednisolone (reference drug). Macro- and microscopic picture, ulcer index and lesion scores, oxidative markers, inflammatory mediators, *in vitro* activity of the inflammatory enzymes and 1, 1-diphenyl-2-picrylhydrazyl free radicals scavenging activity were evaluated. The phytochemical constituents of both extracts were explored by GC-MS analysis. **Results:** Both treatments modulated the macro- and microscopic picture, decreased the ulcerative index, lesion score, oxidative markers and inflammatory mediators, and inhibited the COX-1 and COX-2 enzymes. Propolis appeared to be powerful free radicals scavenger. A powerful synergistic effect of both treatments in modulating the course of the disease was reported. GC-MS analysis of methanol extract of *M. oleifera* seeds and propolis revealed the presence of 50 and 34 compounds, respectively. **Conclusions:** *M. oleifera* seeds and propolis methanol extracts have modulated the course of acetic acid-induced ulcerative colitis. Moreover, both treatments induce a good synergistic effect against the disease. Isolation of the active constituents is recommended.

## 1. Introduction

Ulcerative colitis (UC) is a common chronic inflammatory disease of the large intestine with unknown etiology[1]. It is characterized by erosions of the colon and rectal mucosa with the development of tiny open sores or ulcers, with no segments of normal tissue[2].

Increases in certain inflammatory mediators and appearance of signs of oxidative stress are among the pathological findings associated

This is an open access journal, and articles are distributed under the terms of the Creative Commons Attribution-Non Commercial-Share Alike 4.0 License, which allows others to remix, tweak, and build upon the work non-commercially, as long as appropriate credit is given and the new creations are licensed under the identical terms.

**For reprints contact:** reprints@medknow.com

©2019 Asian Pacific Journal of Tropical Biomedicine Produced by Wolters Kluwer-Medknow

**How to cite this article:** Atta AH, Mounair SM, Nasr SM, Sedky D, Mohamed AM, Atta SA, et al. Phytochemical studies and anti-ulcerative colitis effect of *Moringa oleifera* seeds and Egyptian propolis methanol extracts in a rat model. Asian Pac J Trop Biomed 2019; 9(3): 98-108.

✉First and corresponding author: Attia H. Atta, Department of Pharmacology, Faculty of Veterinary Medicine, Cairo University, Giza P.O. box 12211, Egypt.

Tel: 002-01159813935

E-mail: attaatia52@yahoo.com

with UC[3]. The aim of treatment of UC is to maintain remission, reduce complications and improve quality of life. Important therapeutic achievement was obtained >15 years ago by the introduction of biological therapies such as the anti-tumor necrosis factor alpha (anti-TNF- $\alpha$ ) and monoclonal antibodies[4]. However, the high cost of biological drugs and their patent expiration limit their use[5]. In addition, the use of immunosuppressive treatment especially steroids is risky particularly in patients with viral hepatitis and/or bacterial infections[6]. Therefore, there is a growing need for effective and safe therapeutic agents for the treatment of UC. Alternative therapy for many diseases depends on natural products. *Moringa oleifera* Lam. (*M. oleifera*) grown in India, Pakistan, Bangladesh and Afghanistan[7] and introduced to Mediterranean region, is one of the promising plants because it contains several compounds that have antioxidant (ascorbic acid, carotenoids, flavonoids, and phenols), anti-inflammatory (isothiocyanate and phenolic derivatives)[8] and immunomodulatory[9] effects. *M. oleifera* has been used traditionally for the treatment of many diseases[10]. The root-bark extract[11] and leaves[12] of *M. oleifera* have been shown to induce the antiulcerogenic effect. Data on the effect of methanol extract of *M. oleifera* seeds on UC is lacking. On the other hand, propolis (beeswax) is a mixture containing different compounds such as flavonoids, phenolic, amino acids and trace elements[13]. Propolis has a number of pharmacological effects such as antimicrobial, anti-inflammatory, antiparasitic, antitumor, and antioxidant[14]. Brazilian red propolis extract exerts protective effects on 2,4,6-trinitrobenzenesulfonic acid- and acetic acid-induced colitis in mice and rats[15]. Data on tissue-regenerating actions of propolis are incomplete and often contradictory[16]. This variation or contradiction in its biological activity could be explained on the bases of variation between cultivars from different geographical locations as it has been reported for propolis[17], for *M. oleifera*[18], and for other medicinal plants[19,20]. This study aimed to analyze the phytochemical constituents, investigate the protective effect of methanol extract of *M. oleifera* seeds and Egyptian propolis on acetic acid-induced colitis in rats and to explore the potential synergistic effect of both extracts in minimizing the symptoms of colitis.

## 2. Materials and methods

This experiment was carried out according to the guidelines of the Institutional Animal Care and Use Committee, National Research Centre, Approval Protocol No.: 18/103.

### 2.1. Plant material

Seeds of *M. oleifera* were donated from the Egyptian Scientific Society of Moringa, National Research Centre, Dokki, Giza, Egypt. Seeds

were air dried and moderately pulverized. The powdered plant seeds (200 g) were extracted by percolation for 24 h in methanol 95% several times. The solvent was then evaporated under reduced pressure using a rotary evaporator at a low temperature not more than 50 °C. The yield was 35.7 g. The obtained extract was then kept at -4 °C until used. At the start of the experiments, the extract was freshly suspended in distilled water with few drops of Tween-80. Propolis was obtained from apiaries located in the Delta region, Egypt. Propolis was extracted with methanol several times and methanol was then evaporated at low temperature. The condensed propolis methanol extract was freshly suspended in 1% carboxymethyl cellulose.

### 2.2. Animals and grouping

Forty Sprague Dawley male and female rats (190-200 g) of six weeks age were used. Animals were allocated randomly into 8 equal groups (G I -G VIII). Rats of G I, as normal control, received an equal volume of distilled water. Rats of G II, as ulcerative colitis control, received an equal volume of distilled water before acetic acid-induction of ulcerative colitis. Rats of G III and G IV were pretreated orally with *M. oleifera* seeds methanol extract (MOSME) at a dose of 100 and 200 mg/kg, respectively. Rats of G V and G VI were pretreated with propolis methanol extract orally at a dose of 50 and 100 mg/kg, respectively. Rats of G VII received propolis (50 mg/kg) and MOSME (100 mg/kg) orally. On the 8th day, rats of G II to G VII were administered 2 mL of acetic acid 4% solution intrarectally. Administration of *M. oleifera* and propolis continued till the 11th day. Rats of G VIII were treated with prednisolone (reference drug, 2 mg/kg, *p.o.*, for 3 d) and acetic acid (2 mL of 4% solution, once, intrarectally) on the same day. Rats were kept in good hygienic conditions at room temperature of (25±3) °C with a 12 h dark/light cycle. They were fed standard laboratory feed and watered *ad libitum*.

### 2.3. Sampling

Blood samples were withdrawn by retro-orbital puncture on the 11th day under light anesthesia. Serum was obtained by centrifugation of clotted blood. Animals were euthanized by an overdose of inhalation anesthesia. Colon of each rat, about 2 cm proximal to the anus and 8 cm in length, was taken out of the body and incised longitudinally, washed with normal saline and then placed on a transparent sheet and a photo was taken using an adjusted camera. Colons were then examined macro- and microscopically. Specimens of colon were fixed in 10% formol saline solution for histopathological studies. Samples from the colon were stored immediately at -80 °C till biochemical analysis.

## 2.4. Evaluation of colon macroscopic damage

Lesions of the colon were evaluated macroscopically according to the grading scale of Morris *et al.*[21]. The scores were 0=no macroscopic changes, 1= mucosal erythema only, 2= mild mucosal edema, slight bleeding, or slight erosion, 3= moderate edema, bleeding ulcers, or erosions, and 4= severe ulceration, erosions, edema, and tissue necrosis.

## 2.5. Determination of ulcer index (UI)

The sum of the total length of long ulcers and petechial lesions in each group of rats was divided by its number to calculate the UI (mm)[22].

## 2.6. Biochemical assays

### 2.6.1. Determination of colonic TNF- $\alpha$ level

Frozen (-80 °C) colon tissue samples were immediately weighed, minced on an ice-cold plate and maintained in a tube with 10 mmol/L sodium phosphate buffer (pH 7.4) (1:5 w/v). The tubes were shaken in a shaking water bath (37 °C) for 20 min and centrifuged at 9000  $\times$  g for 10 min at 4 °C; the supernatant was frozen at -80 °C until assay. TNF- $\alpha$  was quantified in the homogenate samples of colons by enzyme-linked immunosorbent assay (ELISA) and the results were expressed as pg/g of wet tissue.

### 2.6.2. Determination of colonic malondialdehyde (MDA) contents

Colonic MDA level was determined in tissue homogenates by the reaction with thiobarbituric acid as described by Ohkawa *et al.*[23] using commercial kits from Biodiagnostic Co., Egypt. The values were expressed as nmol MDA/g protein.

### 2.6.3. Determination of colonic myeloperoxidase (MPO) contents

The activity of MPO is defined as the quantity of enzyme degrading 1  $\mu$ mol of peroxide per min at 25 °C and is expressed in U/g of wet scrapings. The colonic MPO activity was determined according to Krawisz *et al.*[24].

### 2.6.4. Determination of colonic nitrite/nitrate level

Nitric oxide (NO) level in the colon samples was determined by the acidic Griess reaction after reduction of nitrate to nitrite by vanadium trichloride as described by Miranda *et al.*[25]. A pink azo-product is produced as a result of the reaction between nitrite, sulfonamide, and N-(1-naphthyl) ethylenediamine. The intensity of the color was then measured at a maximum absorbance of 543 nm. A standard curve of sodium nitrate was established and the concentrations were

expressed as  $\mu$ g/mg of wet tissue.

## 2.6.5. In vitro effect on the inflammatory enzymes (COX-1 and COX-2)

The ability of *M. oleifera* and propolis to inhibit COX-1 and COX-2 was evaluated using an ovine COX-1/COX-2 inhibitor screening assay kit (catalog no. 760111, Cayman Chemicals, MI, USA) that utilizes the peroxidase component of COX. The peroxidase activity is assayed colorimetrically by monitoring the appearance of oxidized N,N,N',N'-tetramethyl-1,4-phenylenediamine according to Kulmacz and Lands[26]. In addition, the selectivity index (SI values) for the tested compounds was calculated as  $IC_{50}$  (COX-1)/ $IC_{50}$  (COX-2). Celecoxib was used as a reference COX-2 inhibitor.

## 2.7. Determination of in vitro antioxidant effect

The antioxidant activities of MOSME and propolis methanol extract were tested *in vitro* by free radical scavenging assay method described by Sreelatha and Padma[27] using 1, 1-diphenyl-2-picrylhydrazyl (DPPH).

## 2.8. Histopathological evaluation

Colon samples were washed off formal saline with tap water and dehydrated with serial dilutions of ethanol. Specimens were cleared in xylene and embedded in paraffin at 56 °C in a hot air oven for 24 h. Paraffin tissue blocks were sectioned at 5 microns thickness by slide microtome. The obtained tissue sections were mounted on glass slides, deparaffinized and stained by hematoxylin & eosin (H&E) and examined under light microscope[28]. Inflammatory changes, necrotic foci, and damage to tissue structures or to the nucleus in the stained sections were recorded.

## 2.9. GC-MS analysis

Gas chromatograph (GC, Agilent Technologies 7890A) interfaced with a mass-selective detector (Agilent 7000 Triple Quad) was used. Agilent HP-5ms capillary column (30 m $\times$ 0.25 mm ID and 0.25  $\mu$ m film thicknesses) was used. The flow rate was 1 mL/min. The injector and detector temperatures were 200 °C and 250 °C, respectively. The acquisition mass range was 50-600. The chemical structure of the compounds was identified and recorded after comparing their mass spectra and retention time (RT) with those of NIST and WILEY library.

## 2.10. Statistical analysis

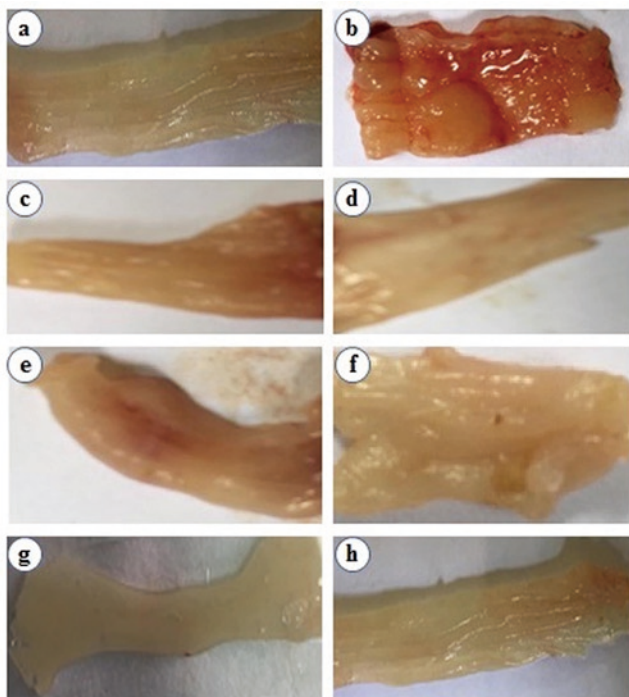
Data were presented as mean $\pm$ SD. Differences between means were tested for significance by ANOVA test using SPSS version

16 computer program. Probability level of  $P < 0.05$  was taken as indication of significance.

### 3. Results

#### 3.1. Effect on the macroscopic picture

Acetic acid produced severe colonic damage characterized by inflammation, swelling, edema, hemorrhages, and necrosis. Dose-dependent mild to moderate inflammatory changes appeared in the colon of rats treated with either MOSME or propolis methanol extract. Concurrent administration of both MOSME and propolis methanol extract completely protected colonic mucosa against acetic acid-induced changes (Figure 1a-1h).



**Figure 1.** Macroscopic pictures of colon.

(a) normal rat, (b) rats with experimental ulcerative colitis (UC), (c and d) rat with UC treated with MOSME (100 and 200 mg/kg, respectively), (e and f) rat with UC treated with propolis (50 and 100 mg/kg, respectively), (g) rat with UC concurrently treated with MOSME, 100 mg/kg and propolis, 50 mg/kg, and (h) rat treated with prednisolone 2 mg/kg.

#### 3.2. Effect on the UI

Administration of acetic acid dramatically increased the UI ( $438.17 \pm 59.26$ ) as compared to that of normal rats ( $3.53 \pm 0.60$ ). Administration of MOSME induced a dose-dependent significant ( $P < 0.05$ ) decrease in the UI. The lesion scores were also dramatically increased by acetic acid and decreased by pretreatment with MOSME or propolis. Concurrent administration of both MOSME and propolis methanol extract significantly decreased the UI ( $P < 0.05$ ) and lesion scores to values nearly similar to the normal

control or to prednisolone. The percent inhibition of colonic damage in rats concurrently pretreated with MOSME and propolis was nearly similar to that pretreated with prednisolone (Table 1).

#### 3.3. Effect on the inflammatory mediators and oxidative markers

Rectal administration of acetic acid significantly increased the inflammatory mediators (TNF- $\alpha$  and NO) and the oxidative markers (MPO and MDA) levels in colonic tissue of treated rats as compared to normal one. Administration of MOSME or propolis methanol extract induced a dose-dependently significant ( $P < 0.05$ ) decrease in both the inflammatory mediators and the oxidative markers. Concurrent administration of both MOSME and propolis methanol extract significantly decreased the levels of the inflammatory mediators and the oxidative markers which were comparable to normal control and prednisolone (Table 2).

**Table 1**

Effect of methanol extract of *M. oleifera* seeds and Egyptian propolis on UI and lesion scores in rats with UC (Mean  $\pm$  SD,  $n=5$ ).

Groups	Ulcer index	Lesion scores	Inhibition (%)
Normal	$3.53 \pm 0.60^a$	$0.04 \pm 0.01^a$	-
Ulcerative colitis control	$438.17 \pm 59.26^d$	$3.72 \pm 0.54^d$	-
<i>M. oleifera</i> (100 mg/kg)	$75.00 \pm 4.69^b$	$0.75 \pm 0.05^b$	79.80
<i>M. oleifera</i> (200 mg/kg)	$63.00 \pm 10.37^b$	$0.53 \pm 0.26^b$	85.80
Propolis (50 mg/kg)	$150.00 \pm 20.00^c$	$0.40 \pm 0.31^c$	89.20
Propolis (100 mg/kg)	$88.00 \pm 16.43^b$	$0.82 \pm 0.20^b$	78.00
<i>M. oleifera</i> + Propolis [(100 + 50) mg/kg]	$5.86 \pm 1.78^a$	$0.07 \pm 0.01^a$	98.10
Prednisolone (2 mg/kg)	$5.32 \pm 1.81^a$	$0.05 \pm 0.01^a$	98.70

Means of different letters in the same column are significantly different at  $P < 0.05$ .

**Table 2**

Effect of methanol extract of *M. oleifera* seeds and Egyptian propolis on the oxidative markers and the inflammatory mediators in rats with UC (Mean  $\pm$  SD,  $n=5$ ).

Groups	MDA (nmol/g protein)	MPO (U/g tissue)	TNF- $\alpha$ (pg/g tissue)	NO ( $\mu$ g/mg tissue)
Normal	$5.26 \pm 0.69^a$	$1.37 \pm 0.13^a$	$8.47 \pm 0.70^b$	$5.59 \pm 0.67^a$
Ulcerative colitis control	$36.53 \pm 15.38^d$	$24.73 \pm 2.25^c$	$72.63 \pm 5.98^f$	$55.08 \pm 7.87^c$
<i>M. oleifera</i> (100 mg/kg)	$21.06 \pm 1.00^c$	$10.06 \pm 0.22^d$	$24.87 \pm 0.95^e$	$23.26 \pm 0.79^d$
<i>M. oleifera</i> (200 mg/kg)	$17.79 \pm 1.18^{bc}$	$6.74 \pm 1.18^c$	$19.81 \pm 2.12^d$	$20.52 \pm 1.35^{cd}$
Propolis (50 mg/kg)	$14.16 \pm 1.62^{bc}$	$4.62 \pm 0.64^b$	$14.62 \pm 1.62^c$	$17.22 \pm 1.56^c$
Propolis (100 mg/kg)	$10.42 \pm 0.84^{ab}$	$3.38 \pm 0.13^b$	$10.98 \pm 0.93^b$	$11.60 \pm 1.67^b$
<i>M. oleifera</i> + Propolis [(100 + 50) mg/kg]	$7.41 \pm 1.07^a$	$3.68 \pm 0.87^b$	$3.07 \pm 0.50^a$	$4.36 \pm 0.75^a$
Prednisolone (2 mg/kg)	$6.12 \pm 0.18^a$	$1.89 \pm 0.07^a$	$4.93 \pm 0.47^a$	$6.59 \pm 0.40^a$

Means of different letters in the same column are significantly different at  $P < 0.05$ .

MDA= Malondialdehyde; MPO=Myeloperoxidase; TNF- $\alpha$ =Tumor necrosis factor- $\alpha$ ; NO=Nitric oxide.

### 3.4. *In vitro* effect on COX-1 and COX-2

The present results showed that both MOSME and propolis methanol extract are potential inhibitors to the inflammatory enzymes; COX-1 and COX-2. The high selectivity for COX-1 inhibition was recorded for the MOSME followed by propolis and then celecoxib (reference COX-2 inhibitor). In contrast, the high selectivity for COX-2 inhibition was recorded for the celecoxib (SI: 302) followed by propolis and then MOSME (Table 3).

**Table 3**

*In vitro* COX-1, COX-2 anti-inflammatory activities of *M. oleifera* seeds and Egyptian propolis methanol extracts.

	COX-1 <sup>a</sup>	COX-2 <sup>a</sup>	Selectivity index COX-1/COX-2
	IC <sub>50</sub> (μmol)	IC <sub>50</sub> (μmol)	
<i>M. oleifera</i>	10.51	0.08	131.40
Propolis	11.32	0.07	161.70
Celecoxib	15.10	0.05	302.00

<sup>a</sup>Mean of three readings; COX= Cyclooxygenase.

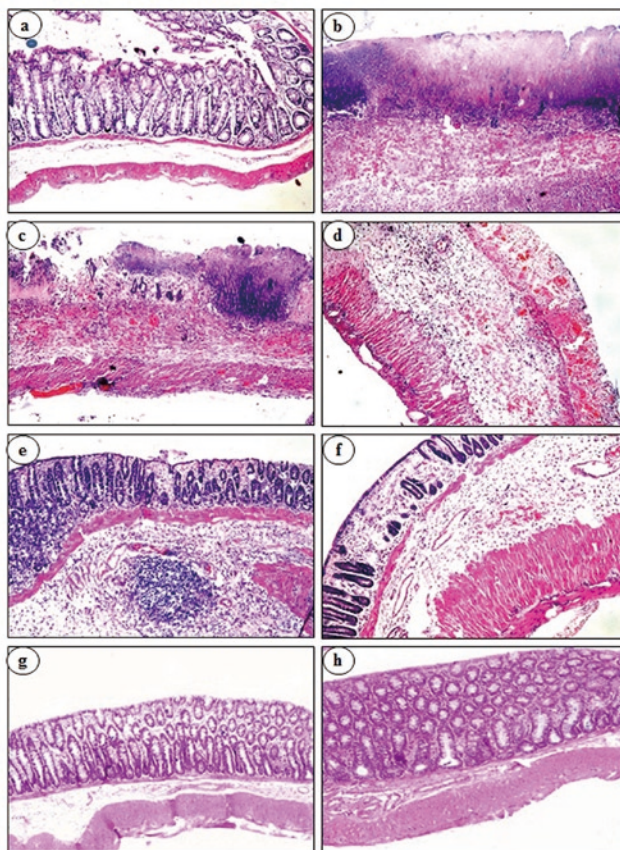
### 3.5. *In vitro* antioxidant effect

Scavenging activity of MOSME against DPPH was weak with only 6.2% scavenging level at 100 μg/mL of the extract. However, propolis methanol extract had high activity against DPPH with an IC<sub>50</sub> value of 10.34 μg/mL and 92.5% scavenging rate of free radicals at the same concentration.

### 3.6. Effect on the histopathological picture

Microscopic examination of colons sections of normal rats showed a normal histological structure of the mucosa, glandular structure with activation of goblet cells, submucosa and muscularis and serosa (Figure 2a). Colon of rats with experimental UC showed focal ulceration, hemorrhages and necrosis with inflammatory cells infiltration in the mucosa, submucosa, muscularis and serosa of the colon wall (Figure 2b). Colon of rats with UC treated with MOSME at a dose of 100 mg/kg showed less focal ulceration and necrosis with hemorrhage and inflammatory cells infiltration in the mucosa, submucosa and muscularis (Figure 2c). Colon of rats with UC treated with MOSME at a dose of 200 mg/kg showed moderate focal ulceration and necrosis associated with inflammatory cells infiltration and mild hemorrhages in the submucosa, muscularis and serosa (Figure 2d). Colon of rats with UC treated with propolis methanol extract at a dose of 50 mg/kg showed focal ulceration and necrosis in the mucosa and inflammatory cells infiltration and hemorrhages in the submucosa (Figure 2e). Colon of rats with UC treated with propolis methanol extract at a dose of 100 mg/kg showed mild focal ulceration and necrosis in the mucosa associated with inflammatory cells infiltration (Figure 2f). Colon of rats with UC and treated with both MOSME (100 mg/kg) and propolis extract 50 mg/kg (Figure 2g) as well as those treated with prednisolone

in a dose of 2 mg/kg (Figure 2h) showed intact mucosa with inflammatory cells infiltration in the underlying submucosa.



**Figure 2.** Histopathological pictures of colon sections.

(a) normal rat, (b) rats with experimental ulcerative colitis (UC), (c and d) rat with UC treated with MOSME (100 and 200 mg/kg, respectively), (e and f) rat with UC treated with propolis (50 and 100 mg/kg, respectively), (g) rat with UC treated with MOSME (100 mg/kg) and propolis (50 mg/kg) and (h) rat treated with prednisolone (2 mg/kg) (H&E, ×100).

### 3.7. GC-MS analysis of the methanol extract

GC-MS analysis revealed the presence of 50 and 34 compounds in MOSME and propolis extract respectively (Tables 4 & 5 and Figure 3). There were 34 and 17 compounds of more than 1% in MOSME and propolis extract, respectively. The major components are 2,5-Di-tert-butyl-1,4-benzoquinone (15.43%) and 4',6-dimethoxyisoflavone-7-O-β-D-glucopyranoside (9.25%) in MOSME and fraxidin (30.15%), methyl α-D-rhamnopyranoside (17.28%) and 6-ethyl-3-formylchromone (5.24%) in propolis extract.

**Table 4**

GC-MS analysis of MOSME.

No.	RT	Molecular formula (MO)	%
1	3.437	Terpineol	0.56
2	5.828	<i>cis</i> -Carveol	1.26
3	6.879	5,7,3',4',5'- Pentamethoxyflavone	1.65
4	3.437	Terpineol	0.56
5	8.000	3,7,3',4',5'-Pentahydroxyflavone	3.34
6	8.578	3',4'-Dihydroxy- $\beta$ -naphthoflavone	0.98
7	8.843	9- <i>cis</i> -Retinoic acid	0.61
8	9.193	Santonox	1.84
9	9.312	Isovitexin	2.39
10	9.532	Caryophyllene	1.78
11	9.747	Alloaromadendrene	1.40
12	9.817	<i>trans</i> -Sesquisabinene hydrate	1.78
13	9.976	Ledene	1.15
14	10.037	$\gamma$ -Selinene	2.94
15	10.196	Curcumol	2.06
16	10.297	( $\pm$ )-Cadinene	2.70
17	10.420	3,4,5-Trimethoxycinnamic acid	2.04
18	10.485	2,6-Di-tert-butyl-4-hydroxymethylphenol	3.21
19	10.534	Elemol	1.56
20	10.652	Lanceol, <i>cis</i>	2.37
21	10.908	2,5-Di-tert-butyl-1,4-benzoquinone	15.43
22	11.173	3,5,3',5'-Tetra-tert-butylidiphenoquinone	1.40
23	11.344	$\beta$ -Santalol	0.69
24	11.548	2'-Hydroxy-2,3,4',6'-tetramethoxychalcone	1.41
25	11.634	5,7-Dimethoxy-4-methylcoumarin	1.83
26	11.829	Sesquicineole	0.67
27	11.923	Quercetin-3,7,3',4'-tetramethyl ether	0.89
28	12.078	Nobiletin	1.39
29	12.265	Cubebol	0.86
30	12.387	Farnesol	0.45
31	12.481	Zearalenone	1.61
32	12.624	Geranyl isovalerate	0.76
33	12.872	Astilbin	1.16
34	12.921	5,7,3',4'-Tetramethoxyflavone	0.88
35	13.006	Phytol	2.84
36	13.169	Citronellyl tiglate	1.98
37	13.300	Levomenthol	1.93
38	13.434	4,2'-Dihydroxy-4',6'-dimethoxychalcone	0.98
39	13.516	5,7,3',4',5'-Pentahydroxyflavone	1.63
40	13.658	6-Ethoxy-4-methylcoumarin	1.80
41	13.838	4',6-Dimethoxyisoflavone-7-O- $\beta$ -D-glucopyranoside	9.25
42	13.960	7,4'-Dimethoxy-3-hydroxyflavone	3.48
43	14.469	Rhamnetin	0.52
44	14.608	5-Hydroxyisovanillic acid	0.98
45	14.787	6,4'-Dimethoxy-7-hydroxyisoflavone	0.72
46	14.938	(S)-(-)-Citronellic acid	2.21
47	14.982	Isolongifolol	2.02
48	15.096	3,6,2',3'-Tetrahydroxyflavone	1.62
49	15.223	5,3'-Dihydroxy-6,7,4'-trimethoxyflavone	1.34
50	16.262	3-(3,4-Dimethoxyphenyl)-4-methylcoumarin	0.88

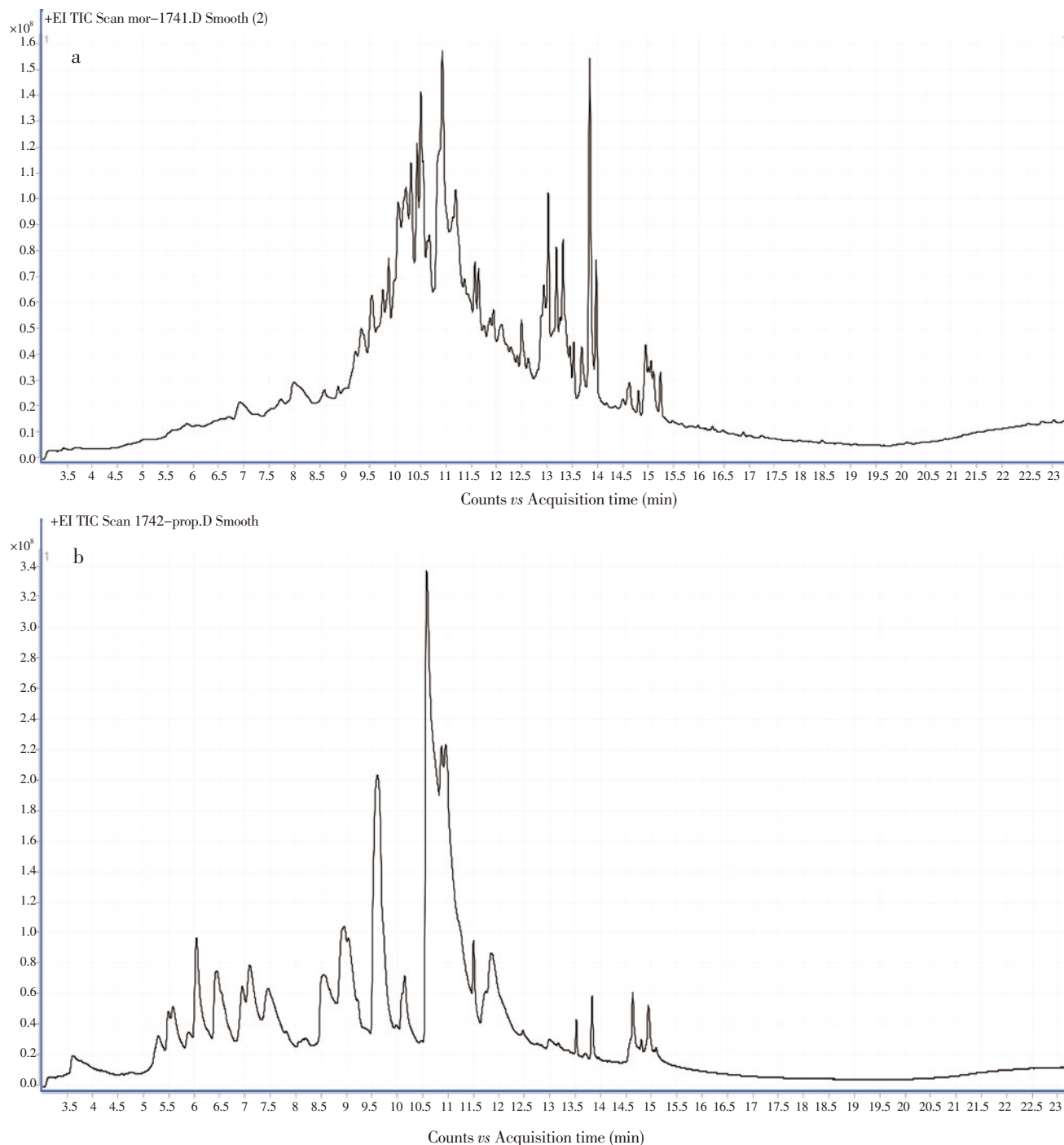
**Table 5**

GC-MS analysis of Egyptian propolis methanol extract.

No	RT	Molecular formula	%
1	3.608	8-Methyloctahydrocoumarin	1.35
2	5.307	Phenol, 4-propoxy-	1.21
3	5.482	Luteolin	1.10
4	5.861	4'-Benzyloxy-5,7-dimethoxyflavone	0.35
5	6.032	<i>p</i> -Menth-1-en-3-one	4.09
6	6.411	6-Ethyl-3-formylchromone	5.24
7	6.924	Glucose	2.34
8	7.083	5,7,3',4',5'-Pentahydroxyflavone	3.14
9	7.438	7-Hydroxy-6-methoxyisoflavone	4.25
10	8.126	Quercetin-3,7,3',4'-tetramethyl ether	0.92
11	8.550	2,5-Dihydroxyphenol	3.33
12	8.929	5,7,3',4',5'-Pentahydroxyflavone	3.68
13	9.018	3-Hydroxy-6,2',4'-trimethoxyflavone	2.45
14	9.202	3,4,5-Trimethoxycinnamic acid	0.71
15	9.597	Methyl $\alpha$ -D-rhamnopyranoside	17.28
16	10.094	4'-Hydroxyflavanone	0.66
17	10.130	2'-Hydroxy-2,4,5-trimethoxychalcone	1.91
18	10.546	Fraxidin	30.15
19	10.855	4-Amino-9-methoxypsoralen	1.52
20	10.925	Ethyl 7-hydroxycoumarin-4-carboxylate	3.92
21	11.491	6,7-Dimethoxy-3-isochromanone	0.89
22	11.687	Rosmarinic acid	0.97
23	11.825	Galactitol	2.22
24	12.485	7,3',4',5'-Tetramethoxyflavanone	0.47
25	12.966	3,5,3',5'-Tetra-tert-butylidiphenoquinone	0.92
26	13.503	Gardenin	0.36
27	13.687	2,6-Di-tert-butyl-4-methoxyphenol	0.49
28	13.821	4',6-Dimethoxyisoflavone-7-O- $\beta$ -D-glucopyranoside	0.87
29	14.575	3,7,2',4',5'-Pentamethoxyflavone	0.53
30	14.612	Dihydrokaempferol	0.40
31	14.783	3,2',4',5'-Tetramethoxyflavone	0.65
32	14.925	Rhapontigenin	0.48
33	15.072	3,3',7,8-Tetramethoxyflavone	0.83
34	13.952	7,8,3',4'-Tetrahydroxyflavone	0.33

#### 4. Discussion

In this work, an acetic acid model of experimental colitis in rats was used as it has been reported that acetic acid produces rapid and reproducible colitis suitable for screening of drugs for anti-colitis effects[29]. In this study, acetic acid induced severe colonic damage and the macroscopic lesions characterized by inflammation, swelling, edema, hemorrhages, and necrosis. It also increased colonic major inflammatory mediators in similar patterns to inflammatory bowel disease (IBD). TNF-  $\alpha$  is one of the cytokines that are involved in systemic inflammation and make up the acute phase reaction. It is produced by activated lymphocytes, macrophages, neutrophils, mast cells, eosinophils, and neurons[30] and can be released as a result of an inflammatory stimulus (*e.g.* lipopolysaccharide)[31]. MDA is a product of degradation by reactive oxygen species of polyunsaturated lipids[32]. It is a reactive aldehyde that causes toxic effects in the cells[33]. Its level is used as an indicator of the degree of oxidative stress in an organism[34]. MPO



**Figure 3.** GC-MS peaks of (a) MOSME and (b) Egyptian propolis methanol extract.

is an important enzyme released by activated polymorphonuclear neutrophils during phagocytic lysis of engulfed foreign particles. It activates the synthesis of hypochlorous acid from hydrogen peroxide and chloride anion[35,36]. Hypochlorous acid radicals are cytotoxic to bacteria and other pathogens[37]. However, it may also cause oxidative damage in host tissue. Its increased level is considered as a biomarker of inflammation[38]. NO is a free radical associated with fatty liver disease and is involved in hepatic lipid metabolism under starvation[39]. Pro-inflammatory mediators, such as cytokines and NO are released by inflammatory cells massively infiltrating the inflamed intestine of patients with IBD[40]. In this study, acetic

acid produced a dramatic increase in TNF-  $\alpha$ , NO, MDA, and MPO which are evident in IBD disease[8]. The decreased pro-inflammatory mediators and improvement of macro- and microscopic picture reported in this study could confirm the strong antioxidant and anti-inflammatory effect of both *M. oleifera* and propolis[8,14]. The acetic acid-induced tissue damage was suggested to be ameliorated by antioxidants that inhibit the enzymes and/or chelating trace elements involved in the free-radical production. The decrease in the MDA and NO level in the MOSME and propolis extract indicates the role of the extracts as antioxidants. It has been previously reported that the protective effect against acetic acid-induced damage includes

scavenging reactive species, protecting antioxidant defenses, and activating antioxidant enzymes[41]. The protective effects of MOSME are also probably due to its anti-inflammatory. Other mechanisms for the antioxidant effect of *M. oleifera* have been reported such as superoxide anion and NO radical scavenging activity that prevents oxidative damage of major biomolecules[26,42]. In this study, propolis has been proved to induce a strong *in vitro* DPPH free radical scavenging activity, providing its antioxidant activity. The antioxidant activity is usually attributed to the total phenolics and flavonoids[43]. *M. oleifera* seeds extract was shown to have significant antioxidant effect which was attributed to its phenolic content[44]. Other bioactive constituents from *M. oleifera* such as glucosinolates, isothiocyanates, and thiocarbamates were suggested to be responsible for antioxidant effect[45]. Isothiocyanates have been proved to have anti-inflammatory as well as immunomodulatory activities[8] to which the anti-ulcerative effect was attributed[9,46]. Moreover, the antioxidant properties of *M. oleifera* were suggested to be mediated through direct trapping of the free radicals and also through metal chelation which was attributed to the presence of phenolic acids and flavonoids[47]. It has been reported that flavonoids possess potent antioxidant effect[48]. In this study, the GC-MS analysis of the methanol extract of *M. oleifera* seeds revealed the presence of at least 10 flavonoid flavones namely, 5,7,3',4',5'-pentamethoxyflavone (1), 3,7,3',4',5'-pentahydroxyflavone (2), 3',4'-dihydroxy- $\beta$ -naphthoflavone (3), 5,7,3',4'-tetramethoxyflavone (4), 5,7,3',4',5'-pentahydroxyflavone (5), 4',6-dimethoxyisoflavone-7-*O*- $\beta$ -*D*-glucopyranoside (6), 7,4'-dimethoxy-3-hydroxyflavone (7), 6,4'-dimethoxy-7-hydroxyisoflavone (8), 3,6,2',3'-tetrahydroxyflavone (9), 5,3'-dihydroxy-6,7,4'-trimethoxyflavone (10). The flavonoid flavones may be contributed to the antioxidant effect of MOSME. Moreover, the phytochemical analysis in the present study revealed that MOSME contains the essential oil alloaromadendrene which has been previously reported to have an antioxidant effect[49]. More recently, phytochemical analysis of MOSME revealed the presence of isovitexin which has been reported to be responsible for inhibition of TNF- $\alpha$  level, MPO activity and MDA content as it occurs in animals with liver intoxication[50]. In this study, the antioxidant effect is also confirmed *in vitro* by the high scavenging activity against DPPH free radicals. This antioxidant effect is nearly similar to that previously reported for *Moringa peregrina*[51,52] and *M. oleifera*[53] extracts. On the other hand, phytochemical analysis of propolis revealed the presence of at least 9 flavonoid flavones namely; 3,3',7,8-tetramethoxyflavone (1), 5,7,3',4',5'-pentahydroxyflavone (2), 4',6-dimethoxyisoflavone-7-*O*- $\beta$ -*D*-glucopyranoside (3), 7-hydroxy-6-methoxyisoflavone (4), 7,8,3',4'-tetrahydroxyflavone (5), 3-hydroxy-6,2',4'-trimethoxyflavone (6), 4'-benzyloxy-5,7-dimethoxyflavone (7), 4'-hydroxyflavanone (8) and 3,2',4',5'-tetramethoxyflavone (9). These flavones may also be contributed to the antioxidant effect of propolis. It should be pointed out

that MOSME and propolis methanol extract have common compounds with an identical structural formula such as 5,7,3',4',5'-pentahydroxyflavone and 4',6-dimethoxyisoflavone-7-*O*- $\beta$ -*D*-glucopyranoside which could explain the synergistic antioxidant effect between them. Moreover, the methanol extract of both *M. oleifera* and propolis in this work showed a potent inhibitory effect on the inflammatory enzymes (COX-1 and COX-2). However, a high selectivity index was recorded for the celecoxib followed by propolis and then MOSME proving a selective inhibition of COX-2, which plays a key role in prostaglandin biosynthesis and hence protects colonic mucosa against acetic acid-induced damage. Moreover, *M. oleifera* flower hydroethanolic extract was reported to suppress the secretion of NO, prostaglandin E<sub>2</sub>, TNF- $\alpha$ , inducible NO synthase, and COX-2[54]. *M. oleifera* has also been reported to have a suppressive effect on COX-1[55].

On the other hand, the extract of *M. oleifera* and propolis suppresses leukotriene biosynthesis (TNF- $\alpha$ ); a mechanism which is similar to glucocorticoids anti-inflammatory effect in relieving human IBD[56]. Additional mechanisms such as improvement of cellular and humoral immunity by *M. oleifera*[57] and by propolis[58] can also be involved in the protective effect against acetic acid-induced colitis. Furthermore, *M. oleifera* contains  $\beta$ -caryophyllene which has been shown to have anti-inflammatory and anti-edematogenic action[59]. Moreover, propolis contains abundant polyphenolic compounds[60] which were claimed to exhibit significant anti-inflammatory effects, probably by blocking the activation of inflammatory mediator NF- $\kappa$ B[61,62]. In this study, propolis has been also proved to inhibit the inflammatory mediators; TNF- $\alpha$  and NO. The synergistic effect between MOSME and propolis was marked in inhibition of these mediators. The synergistic effect of MOSME and propolis was also marked in an improvement of the histopathological picture of livers of treated rats as compared to those treated by each one alone. The outcome of the combined treatment with *M. oleifera* seeds and propolis extracts was better than the use of each one alone or even the use of prednisolone regarding the inflammatory mediators (TNF- $\alpha$ , NO), and the oxidative markers (MDA, MPO) as well as the macro and microscopic picture confirming a synergistic effect of both *M. oleifera* and propolis.

Our findings suggest a useful therapeutic activity for the methanol extract of *M. oleifera* seeds and of propolis as an anti-ulcerative remedy. A synergistic effect between MOSME and propolis was pronounced suggesting their possible use as an alternative therapy for the colonic inflammatory condition.

### Conflict of interest statement

The authors declare that there is no conflict of interest.



## References

- [1] Romana BS, Albarrak AA, Yousef MH, Tahan V. Infliximab use in ulcerative colitis flare with clostridium difficile infection: A report of two cases and literature review. *North Clin Istanb* 2018; **5**(3): 256-260. Doi: 10.14744/nci.2017.79446
- [2] Fukuda T, Naganuma M, Kanai T. Current new challenges in the management of ulcerative colitis. *Intest Res* 2019; **17**(1): 36-44. Doi: 10.5217/ir.2018.00126.
- [3] Kumar VL, Pandey A, Verma S, Das P. Protection afforded by methanol extract of *Calotropis procera* latex in experimental model of colitis is mediated through inhibition of oxidative stress and pro-inflammatory signaling. *Biomed Pharmacother* 2019; **109**: 1602-1609. Doi: 10.1016/j.biopha.2018.
- [4] Deleporte A, Viennot S, Dupont B, Giletta C, Allaire M, Prévost F, et al. Efficacy of anti-TNF-alpha monoclonal antibodies in inflammatory bowel disease treatment. *Int J Interferon Cytokine Mediat Res* 2013; **2013**(5): 11-31. Doi: 10.2147/IJICMR.S21705.
- [5] Bilsborough J, Targan SR, Snapper SB. Therapeutic targets in inflammatory bowel disease: Current and future. *Am J Gastroenterol Suppl* 2016; **3**: 27-37. Doi: 10.1038/ajgsup.2016.18.
- [6] Stucker F, Ackermann D. Immunosuppressive drugs-how they work, their side effects and interactions. *Ther Umsch* 2011; **68**(12): 679-686. Doi: 10.1024/0040-5930/a000230.
- [7] Padayachee B, Baijnath H. An overview of the medicinal importance of Moringaceae. *J Med Plants Res* 2012; **6**(48): 5831-5839. Doi: 10.5897/JMPR12.1187.
- [8] Mahajan SG, Mali RG, Mehta AA. Effect of *Moringa oleifera* Lam. seed extract on toluene diisocyanate-induced immune-mediated inflammatory responses in rats. *J Immunotoxicol* 2007; **4**(2): 85-96. Doi:10.1080/15476910701337472.
- [9] Coriolano MC, de Santana Brito J, de Siqueira Patriota LL, de Araujo Soares AK, Lorena VMB, Paiva PMG, et al. Immunomodulatory effects of the water-soluble lectin from *Moringa oleifera* seeds (WSMoL) on human peripheral blood mononuclear cells (PBMC). *Protein Pept Lett* 2018; **25**(3): 295-301. Doi: 10.2174/0929866525666180130141736.
- [10] Stohs SJ, Hartman MJ. Review of the safety and efficacy of *Moringa oleifera*. *Phytother Res* 2015; **29**(6): 796-804. Doi: 10.1002/ptr.5325.
- [11] Choudhary MK, Bodakhe SH, Gupta SK. Assessment of the antiulcer potential of *Moringa oleifera* root-bark extract in rats. *J Acupunct Meridian Stud* 2013; **6**(4): 214-220. Doi: 10.1016/j.jams.2013.07.003.
- [12] Ijioma SN, Nwaogazi EN, Nwankwo AA, Oshilonya H, Ekeleme CM, Oshilonya LU. Histological exhibition of the gastroprotective effect of *Moringa oleifera* leaf extract. *Comp Clin Pathol* 2018; **27**(2): 327-332. Doi: 10.1007/s00580-017-2594-0.
- [13] Machado BA, Silva RP, Barreto Gde A, Costa SS, Silva DF, Brandão HN, et al. Chemical composition and biological activity of extracts obtained by supercritical extraction and ethanolic extraction of brown, green and red propolis derived from different geographic regions in Brazil. *PLoS One* 2016; **11**(1): e0145954. Doi: 10.1371/journal.pone.0145954.
- [14] de Freitas MCD, de Miranda MB, de Oliveira DT, Vieira-Filho SA, Caligiorne RB, de Figueiredo SM. Biological activities of red propolis: A review. *Recent Pat Endocr Metab Immune Drug Discov* 2017; **11**(1): 3-12. Doi: 10.2174/1872214812666180223120316.
- [15] Barbosa Bezerra GB, de Menezes de Souza L, Dos Santos AS, de Almeida GK, Souza MT, Santos SL, et al. Hydroalcoholic extract of Brazilian red propolis exerts protective effects on acetic acid-induced ulcerative colitis in a rodent model. *Biomed Pharmacother* 2017; **85**: 687-696. Doi:10.1016/j.biopha.2016.11.080.
- [16] Paulino N, Dantas AP, Bankova V, Longhi DT, Scremin A, de Castro SL, et al. Bulgarian propolis induces analgesic and anti-inflammatory effects in mice and inhibits *in vitro* contraction of airway smooth muscle. *J Pharmacol Sci* 2003; **93**(3): 307-313.
- [17] Zancanela DC, Funari CS, Herculano RD, Mello VM, Rodrigues CM, Borges FA, et al. Natural rubber latex membranes incorporated with three different types of propolis: Physical-chemistry and antimicrobial behaviours. *Mater Sci Eng C Mater Biol Appl* 2019; **97**: 576-582. Doi: 10.1016/j.msec.2018.12.042.
- [18] Iqbal S, Bhangar MI. Effect of season and production location on antioxidant activity of *Moringa oleifera* leaves grown in Pakistan. *J Food Compost Anal* 2006; **19**(6-7): 544-551. Doi: 10.1016/j.jfca.2005.05.001.
- [19] Kasai H, Kubota Y. Analyses of volatile components of lavender (*Lavandula angustifolia* HIDCOTE and *Lavandula sintermidia* GROSSO) as influenced by cultivar type, part, and growth season. *Yakugaku Zasshi* 2018; **138**(12): 1569-1577. Doi: 10.1248/yakushi.18-00159.
- [20] Škrovánková S, Mišurcová L, Machů L. Antioxidant activity and protecting health effects of common medicinal plants. *Adv Food Nutr Res* 2012; **67**: 75-139. Doi: 10.1016/B978-0-12-394598-3.00003-4.
- [21] Morris GP, Beck PL, Herridge MS, Depew WT, Szweczek MR, Wallace JL. Hapten-induced model of chronic inflammation and ulceration in the rat colon. *Gastroenterology* 1989; **96**(3): 795-803.
- [22] Ku SK, Seo BI, Park JH, Park GY, Seo YB, Kim JS, et al. Effect of Lonicerae Flos extracts on reflux esophagitis with antioxidant activity. *World J Gastroenterol* 2009; **15**(38): 4799-4805.
- [23] Ohkawa H, Ohishi N, Yagi K. Assay for lipid peroxides in animal tissues by thiobarbituric acid reaction. *Anal Biochem* 1979; **95**(2): 351-258.
- [24] Krawisz JE, Sharon P, Stenson WF. Quantitative assay for acute intestinal inflammation based on myeloperoxidase activity: Assessment of inflammation in rat and hamster models. *Gastroenterology* 1984; **87**(6): 1344-1350.
- [25] Miranda KM, Espey MG, Wink DA. A rapid, simple spectrophotometric method for simultaneous detection of nitrate and nitrite. *Nitric Oxide* 2001; **5**(1): 62-71.
- [26] Kulmacz RJ, Lands WE. Requirements for hydroperoxide by the cyclooxygenase and peroxidase activities of prostaglandin H synthase. *Prostaglandins* 1983; **25**(4): 531-540.
- [27] Sreelatha S, Padma P. Antioxidant activity and total phenolic content of *Moringa oleifera* leaves in two stages of maturity. *Plant Foods Hum Nutr*

- 2009; **64**(4): 303-311. Doi: 10.1007/s11130-009-0141-0.
- [28]Suvarna KS, Layton C, Bancroft JD. *Bancroft's theory and practice of histological techniques e. Book* [Online]. 7th ed. Churchill Livingstone: Elsevier Health Sciences; 2012. Available from: [https://books.google.com.eg/books?id=wPPU4NyGm3gC&printsec=frontcover&source=gs\\_bse\\_summary\\_r&cad=0#v=onepage&q&f=false](https://books.google.com.eg/books?id=wPPU4NyGm3gC&printsec=frontcover&source=gs_bse_summary_r&cad=0#v=onepage&q&f=false) [Accessed on 1 Oct 2012].
- [29]MacPherson BR, Pfeiffer CJ. Experimental production of diffuse colitis in rats. *Digestion* 1978; **17**(2): 135-150.
- [30]Gahring LC, Carlson NG, Kulmer RA, Rogers SW. Neuronal expression of tumor necrosis factor alpha in the OVOUJI fme brain. *Neuroimmunomodulation* 1996; **3**(5): 289-303. Doi: 10.1159/000097283.
- [31]Walsh LJ, Trinchieri G, Waldorf HA, Whitaker D, Murphy GF. Human dermal mast cells contain and release tumor necrosis factor alpha, which induces endothelial leukocyte adhesion molecule 1. *Proc Natl Acad Sci USA* 1991; **88**(10): 4220-4224.
- [32]Ayala A, Muñoz MF, Argüelles S. Lipid peroxidation: Production, metabolism, and signaling mechanisms of malondialdehyde and 4-hydroxy-2-nonenal. *Oxid Med Cell Longev* 2014; **2014**: 360438. Doi: 10.1155/2014/360438.
- [33]Farmer EE, Davoine C. Reactive electrophile species. *Curr Opin Plant Biol* 2007; **10**(4): 380-386.
- [34]Del Rio D, Stewart AJ, Pellegrini N. A review of recent studies on malondialdehyde as toxic molecule and biological marker of oxidative stress. *Nutr Metab Cardiovasc Dis* 2005; **15**(4): 316-328.
- [35]Heinecke JW, Li W, Francis GA, Goldstein JA. Tyrosyl radical generated by myeloperoxidase catalyzes the oxidative cross-linking of proteins. *J Clin Invest* 1993; **91**(6): 2866-2872.
- [36]Hampton MB, Kettle AJ, Winterbourn CC. Inside the neutrophil phagosome: Oxidants, myeloperoxidase, and bacterial killing. *Blood* 1998; **92**(9): 3007-3017.
- [37]Klebanoff SJ. Myeloperoxidase. *Proc Assoc Am Physicians* 1999; **111**(5): 383-389.
- [38]Loria V, Dato I, Graziani F, Biasucci LM. Myeloperoxidase: A new biomarker of inflammation in ischemic heart disease and acute coronary syndromes. *Mediators Inflamm* 2008; **2008**: 135625. Doi: 10.1155/2008/135625.
- [39]van Faassen EE, Bahrami S, Feelisch M, Hogg N, Kelm M, Kim-Shapiro DB, et al. Nitrite as regulator of hypoxic signaling in mammalian physiology. *Med Res Rev* 2009; **29**(5): 683-741. Doi: 10.1002/med.20151.
- [40]Abraham C, Medzhitov R. Interactions between the host innate immune system and microbes in inflammatory bowel disease. *Gastroenterology* 2011; **140**(6): 1729-1737.
- [41]Montoro P, Braca A, Pizza C, De Tommasi N. Structure-antioxidant activity relationships of flavonoids isolated from different plant species. *Food Chem* 2005; **92**(2): 349-355. Doi: 10.1016/j.foodchem.2004.07.028.
- [42]Luqman S, Srivastava S, Kumar R, Maurya AK, Chanda D. Experimental assessment of *Moringa oleifera* leaf and fruit for its antistress, antioxidant, and scavenging potential using *in vitro* and *in vivo* assays. *Evid Based Complement Alternat Med* 2012; **2012**: 519084. Doi: 10.1155/2012/519084.
- [43]Pakade V, Cukrowska E, Chimuka L. Comparison of antioxidant activity of *Moringa oleifera* and selected vegetables in South Africa. *S Afr J Sci* 2013; **109**(3/4): 1-5. Doi: 10.1590/sajs.2013/1154.
- [44]Adebayo IA, Arsad H, Samian MR. Total phenolics, total flavonoids, antioxidant capacities, and volatile compounds gas chromatography-mass spectrometry profiling of *Moringa oleifera* ripe seed polar fractions. *Pharmacogn Mag* 2018; **14**(54): 191-194. Doi: 10.4103/pm.pm\_212\_17.
- [45]Kumar GS, Kumar B, Srinivasan BP, Nag TC, Srivastava S, Saxena R, et al. Retinoprotective effects of *Moringa oleifera* via antioxidant, anti-inflammatory, and anti-angiogenic mechanisms in streptozotocin-induced diabetic rats. *J Ocul Pharmacol Ther* 2013; **29**(4): 419-426. Doi: 10.1089/jop.2012.0089.
- [46]Kim Y, Wu AG, Jaja-Chimedza A, Graf BL, Waterman C, Verzi MP, et al. Isothiocyanate-enriched moringa seed extract alleviates ulcerative colitis symptoms in mice. *PLoS One* 2017; **12**(9): e0184709. Doi: 10.1371/journal.pone.0184709.
- [47]Kou X, Li B, Olayanju JB, Drake JM, Chen N. Nutraceutical or pharmacological potential of *Moringa oleifera* Lam. *Nutrients* 2018; **10**(3). pii: E343. Doi: 10.3390/nu10030343.
- [48]Jaja-Chimedza A, Graf BL, Simmler C, Kim Y, Kuhn P, Pauli GF, et al. Biochemical characterization and anti-inflammatory properties of an isothiocyanate-enriched moringa (*Moringa oleifera*) seed extract. *PLoS One* 2017; **12**(8): e0182658. Doi: 10.1371/journal.pone.0182658.
- [49]Yu CW, Li WH, Hsu FL, Yen PL, Chang ST, Liao VH. Essential oil alloaromadendrene from mixed-type *Cinnamomum osmophloeum* leaves prolongs the life span in *Caenorhabditis elegans*. *J Agric Food Chem* 2014; **62**(26): 6159-6165. Doi: 10.1021/jf500417y.
- [50]Hu JJ, Wang H, Pan CW, Lin MX. Isovitexin alleviates liver injury induced by lipopolysaccharide/d-galactosamine by activating Nrf2 and inhibiting NF- $\kappa$ B activation. *Microb Pathog* 2018; **119**: 86-92. Doi: 10.1016/j.micpath.2018.03.053.
- [51]Omodanisi EI, Aboua YG, Oguntibeju OO. Assessment of the anti-hyperglycaemic, anti-inflammatory and antioxidant activities of the methanol extract of *Moringa oleifera* in diabetes-induced nephrotoxic male Wistar rats. *Molecules* 2017; **22**(4): E439. Doi: 10.3390/molecules22040439.
- [52]Al-Dabbas MM. Antioxidant activity of different extracts from the aerial part of *Moringa peregrina* (Forssk.) Fiori, from Jordan. *Pak J Pharm Sci* 2017; **30**(6): 2151-2157.
- [53]Fitriana WD, Ersam T, Shimizu K, Fatmawati S. Antioxidant activity of *Moringa oleifera* extracts. *Indones J Chem* 2016; **16**(3): 297-301. Doi: 10.22146/ijc.21145.
- [54]Tan WS, Arulselvan P, Karthivashan G, Fakurazi S. *Moringa oleifera* flower extract suppresses the activation of inflammatory mediators in lipopolysaccharide-stimulated RAW 264.7 macrophages via NF- $\kappa$ B pathway. *Mediators Inflamm* 2015; **2015**: 720171. Doi: 10.1155/2015/720171.

- [55] Paikra BK, Dhongade HKJ, Gidwani B. Phytochemistry and pharmacology of *Moringa oleifera* Lam. *J Pharmacopuncture* 2017; **20**(3): 194-200. Doi: 10.3831/KPL.2017.20.022.
- [56] Dos Santos AO, do Val DR, da Silveira FD, Gomes FIF, Freitas HC, de Assis EL, et al. Antinociceptive, anti-inflammatory and toxicological evaluation of semi-synthetic molecules obtained from a benzyl-isothiocyanate isolated from *Moringa oleifera* Lam. in a temporomandibular joint inflammatory hypernociception model in rats. *Biomed Pharmacother* 2018; **98**: 609-618. Doi: 10.1016/j.biopha.2017.12.102.
- [57] Nfambi J, Bbosa GS, Sembajwe LF, Gakunga J, Kasolo JN. Immunomodulatory activity of methanolic leaf extract of *Moringa oleifera* in Wistar albino rats. *J Basic Clin Physiol Pharmacol* 2015; **26**(6): 603-611. Doi: 10.1515/jbcpp-2014-0104.
- [58] Attia YA, Al-Khalaifah H, Ibrahim MS, Al-Hamid AEA, Al-Harathi MA, El-Naggar A. Blood hematological and biochemical constituents, antioxidant enzymes, immunity and lymphoid organs of broiler chicks supplemented with propolis, bee pollen and mannan oligosaccharides continuously or intermittently. *Poult Sci* 2017; **96**(12): 4182-4192. Doi: 10.3382/ps/pex173.
- [59] Oliveira-Tintino CDM, Pessoa RT, Fernandes MNM, Alcântara IS, da Silva BAF, de Oliveira MRC, et al. Anti-inflammatory and anti-edematogenic action of the *Croton campestris* A. St.-Hil (Euphorbiaceae) essential oil and the compound  $\beta$ -caryophyllene in *in vivo* models. *Phytomedicine* 2018; **41**: 82-95. Doi: 10.1016/j.phymed.2018.02.004.
- [60] Elnakady YA, Rushdi AI, Franke R, Abutaha N, Ebaid H, Baabbad M, et al. Characteristics, chemical compositions and biological activities of propolis from Al-Bahah, Saudi Arabia. *Sci Rep* 2017; **6**(7): 41453. Doi: 10.1038/srep41453.
- [61] Wang K, Ping S, Huang S, Hu L, Xuan H, Zhang C, et al. Molecular mechanisms underlying the *in vitro* anti-inflammatory effects of a flavonoid-rich ethanol extract from Chinese propolis, poplar type. *Evid Based Complement Alternat Med* 2013; **2013**: 127672. Doi: 10.1155/2013/127672.
- [62] Wang K, Zhang J, Ping S, Ma Q, Chen X, Xuan H, et al. Anti-inflammatory effects of ethanol extracts of Chinese propolis and buds from poplar (*Populus canadensis*). *J Ethnopharmacol* 2014; **155**(1): 300-311. Doi: 10.1016/j.jep.2014.05.037.