

The effect of a tongue on lower anterior alveolar trough- A clinical case report

Denny J Payapilly¹, Sunil Sunny², Roshini Sara Rajan³, Lincy Stephen Joseph^{4,*}

¹Professor and HOD, ^{2,3}Former Professor, ⁴Post graduate Student, ^{1,4}Dept. of Orthodontics, Kuhs University Annoor Dental College and Hospital Perumattom, Muvattupuzha, Kerala, India

***Corresponding Author: Lincy Stephen Joseph**

Email: lincy248@gmail.com

Abstract

Introduction: The purpose of these case reports was to evaluate the thickness of the lower anterior alveolar trough in patients with tongue thrusting habit.

Materials and Methods: Lateral cephalogram and CBCT was evaluated in these patients.

Result: Both lateral cephalogram and CBCT confirmed reduced thickness of anterior trough in patients with tongue thrust habit.

Conclusion: Depending on the thickness of the alveolar bone, the extend of lower incisor retraction could be evaluated.

Keywords: Tongue, alveolar trough, Lateral cephalogram, CBCT

Introduction

Tongue thrusting or an imbalance of orofacial musculature is a common problem encountered in orthodontic practice. There is no consensus about the effect of tongue thrusting on lower anterior alveolar bone. It has been suggested that the size, function and posture of the tongue might have some effects on the surrounding oral environment.³

Materials and Methods

Case 1

A 22 year old female patient reported to the department of orthodontics with an angles class I malocclusion and open bite on a skeletal class II jaw base (Fig. 1a, 1b and 1c). The patient presented with a severe tongue thrusting habit.

On clinical examination the patient had proclined upper and lower anteriors. Both lateral cephalogram and CBCT was evaluated (Fig. 2 a, b and 3)

Case 2

A 23 year old female patient reported to the department of orthodontics with an Angles class I malocclusion and open bite on a skeletal class I jaw base (figure 4a, 4b and 4c).

Severe tongue thrusting habit was present. Similarly a lateral cephalogram and CBCT was taken (Fig. 5 a,b and 6)

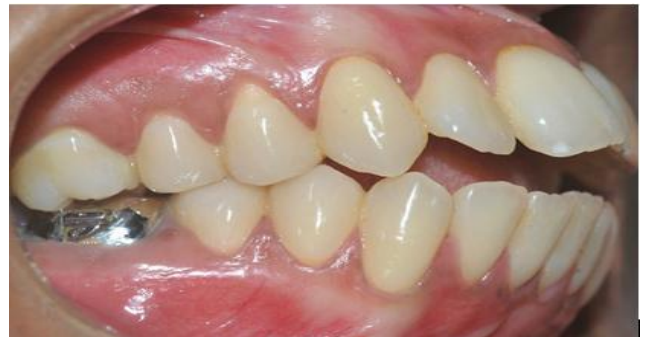

Fig. 1b: Intra oral photograph – right lateral

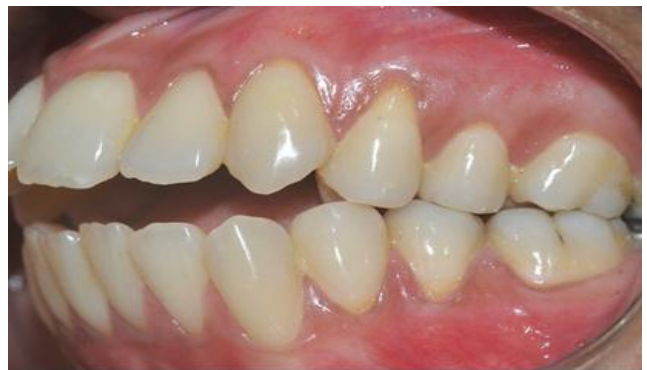

Fig. 1c: Intra oral photograph – left lateral

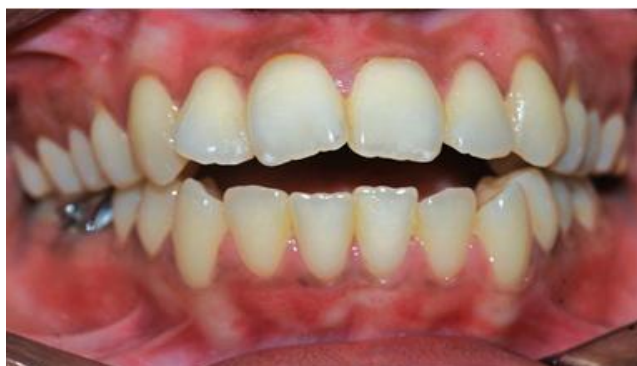

Fig. 1a: Intra oral photograph – frontal view

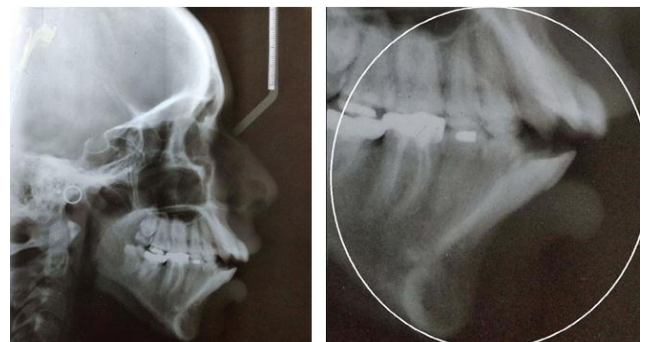


Fig. 2 a, b: Lateral cephalogram

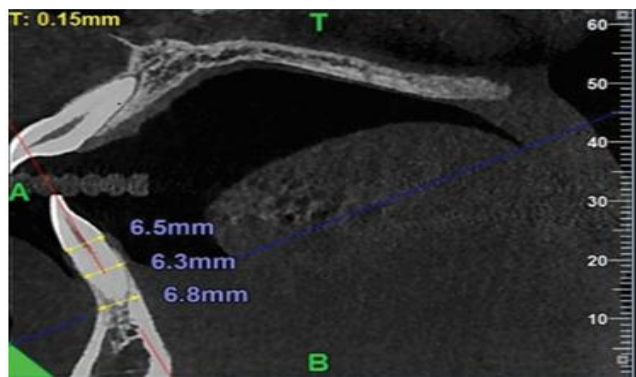


Fig. 3: CBCT

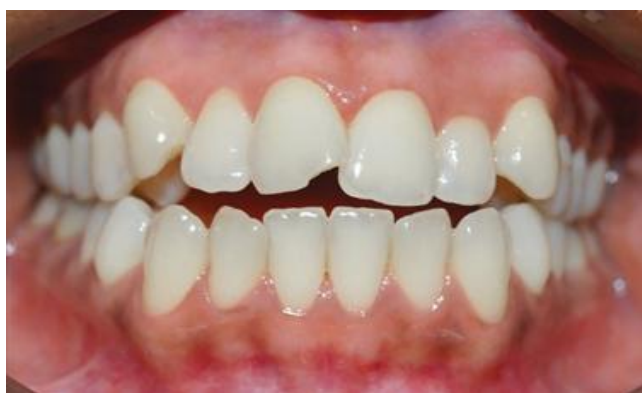

Fig. 4a: Intra oral photograph- frontal view

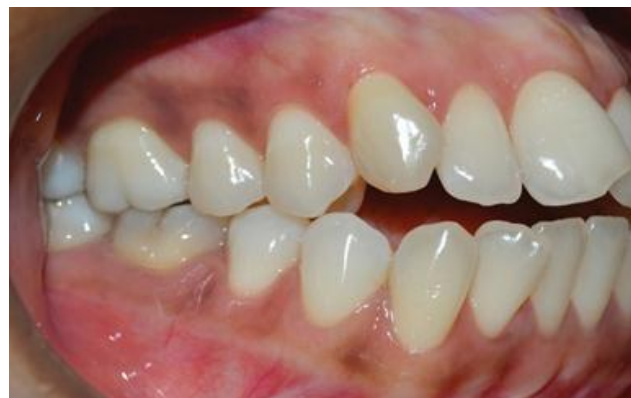

Fig. 4b: Intra oral photograph- right lateral

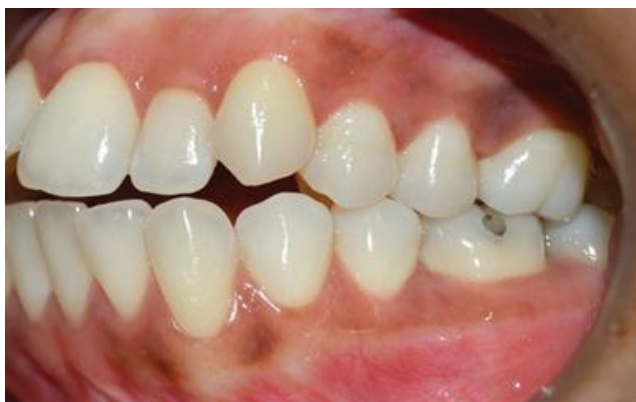

Fig. 4c: Intra oral photograph – left lateral

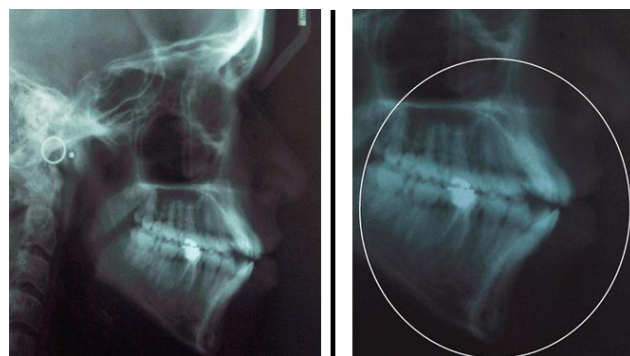


Fig. 5 a, b: Lateral cephalogram

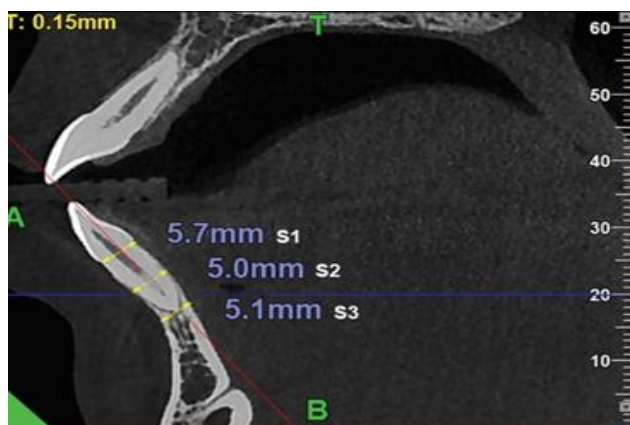


Fig. 6: CBCT

Discussion

The direction of movement, the frequency and magnitude of orthodontic force, the volume and anatomic integrity of periodontal tissues should be taken in to account in treatment planning or else it may lead to fenestration and dehiscence.² Alveolar bone loss can occurs if the incisors are moved in this way, and there is disagreement about whether the remodelling capacity of the alveolar bone can compensate for the bone loss in every case.⁴ Orthodontist can improve the outcome and can make a right decision by a thorough assessment of alveolar bone of mandibular and maxillary incisors.

To improve the anteroposterior relationship, labial-lingual movement of the anterior teeth of the maxillary and mandibular arches is mandatory to attain a well balanced profile. Retraction of incisors can cause adverse effect, so observation should be done carefully to avoid negative iatrogenic effects. Our lateral cephalogram shows that the marginal alveolar plate thickness was reduced which was confirmed by CBCT findings. Considering all these points this study done by using CBCT measurements is more accurate to evaluate the bone width changes. Use of the CBCT scan allowed us to evaluate every tooth at three different levels. In orthodontic practice, high force does not help to produce a efficient tooth movement. In contrast they will effect negatively to the periodontal tissues and will hinder the tooth movement.⁵

If compensatory orthodontics are chosen for patients with slight skeletal discrepancy, orthodontists should

control the torque of the maxillary and mandibular anterior teeth and to attain root-control movement.¹

Conclusion

Compared with traditional radiographs, CBCT provides clear visualization and three-dimensional images (axial, sagittal, coronal planes) without distortions or overlapping of structures.

During orthodontic tooth repositioning, dense cortical plates of the incisors are considered as orthodontic walls. Only with the adequate alveolar bone support effectual orthodontic tooth movement can be achieved.

High resolution CBCT has proven to be effective in evaluating the structure of labial and lingual alveolar bone and determining dehiscence. Even though computed tomography is not yet accessible for regular orthodontic screening because of technical and financial aspects and additional radiation risks, it may lead to elucidate scientific issues and be used as an additional diagnostic aid.

Reference

1. Tian Y, Liu F, Sun H. Alveolar bone thickness around maxillary central incisors of different inclination assessed with cone-beam computed tomography. *Korean J Orthod* 2015;45(5):245-252. doi:10.4041/kjod.2015.45.5.245.
2. Sonnier KE, Horning GM. Spontaneous bony exposure: a report of 4 cases of idiopathic exposure and sequestration of alveolar bone. *J periodontol* 1997;68(8):758-762.
3. Posen AL. The influence of maximum perioral and tongue force on the incisor teeth. *Angle Orthod* 1972;42(4):285-309.
4. Vardimon AD, Oren E, Ben-Bassat Y. Cortical bone remodelling/ tooth movement ratio during maxillary incisor retraction. *Am J Orthod Dentofacial Orthop* 1998;114:520-9.
5. Nayak Krishna U S, Shetty A, Girija M P, Nayak R. Changes in alveolar bone thickness due to retraction of anterior teeth during orthodontic treatment: A cephalometric and computed tomography comparative study. *Indian J Dent Res* 2013;24:736-741.

How to cite this article: Payapilly DJ, Sunny S, Rajan RS, Joseph LS, The effect of a tongue on lower anterior alveolar trough- a clinical case report. *Int Dent J Student's Res* 2019;7(1):19-21