

## A comparison of hemiarthroplasty with total hip replacement for displaced fracture of femoral neck in the elderly

S Aathithya<sup>1\*</sup>, Mohan B Chowdhary<sup>2</sup>

<sup>1</sup>Post Graduate, <sup>2</sup>Associate Professor, Dept. of Orthopaedics, Sri Ramachandra Medical College and Research Institute, Chennai, Tamil Nadu, India

\*Corresponding Author: S Aathithya

Email: kirubasam01@gmail.com

### Abstract

**Introduction:** Globally about 70% of the hip fractures are due to the neck of femur fracture. Surgical management has proved to be clinically and functionally superior to conservative immobilization. Hence the study is to assess the optimal treatment modality for the treatment of neck of femur fractures.

**Materials and Methods:** The present study is an analytical cross-sectional study. About 70 patients diagnosed with unstable neck of femur fractures who were treated with total hip replacement as 35 cases (Group 1) and bipolar hemiarthroplasty as 35 cases (Group 2). The study duration was from April 2016 to September 2018.

**Results:** The female population was also found to be more prone for fractures in both -THR group (65%) and bipolar hemiarthroplasty group (60%). The mean duration of stay in the hospital is lower in the THR group (6 days) when compared with the bipolar hemiarthroplasty group (8 days). The mean time till full weight bearing walking (days) was observed to be significantly reduced in the THR group (2.73 days) when compared with the bipolar hemiarthroplasty group (3 days). The mean mortality rate in the THR group (3.3%) was observed to be lower than the bipolar hemiarthroplasty group (5.5%).

**Conclusion:** Total hip replacement, however is observed to be superior to bipolar hemiarthroplasty in terms of duration of hospital stay, immediate full-weight bearing walking and better functional outcomes with fewer complications.

**Keywords:** Fracture of femoral neck, Elderly, Hemiarthroplasty, Total hip replacement.

### Introduction

Fractures of the neck of femur are usually seen in the elderly population causing in significant morbidity and mortality in the vulnerable age group. Globally about 70% of the hip fractures are due to the neck of femur fracture. The range of minimum to moderate trauma is often adequate to effect in fracture of neck of femur and is complicated further by prevailing medical comorbidities altering the prognosis.

The mounting attention in fractures of neck of femur has been a consequence of the significant impact of these fractures in the quality of life of the growing population of geriatric patients. In geriatric patients accidental slip and fall can generate sixteen times the force required to fracture the proximal femur. In the malnourished elderly, while the muscle bulk and fat act as shock absorbers, the osteoporotic nature of the bone predisposes further to the fracture.

Surgical management has proved to be clinically and functionally superior to conservative immobilization and has hence become the mainstay of treatment. Communion at the postero-medial cortex, postero-lateral communiton and fractures extending in to the proximal femoral diaphysis result in unstable neck of femur fractures which are often challenging to treat.

In the 1960's total hip arthroplasty was introduced which revolutionised the management of these challenging fractures.<sup>1</sup> The treatment of the fracture with primary arthroplasty helped in rapid mobilisation, while decreasing the chances of implant failure and complications such as deep vein thrombosis, pulmonary complications, infection and bed sores. The post-operative duration of time required for the patient to return to pre-injury status was also found to be reduced.<sup>2,3</sup> The purpose of this study, is to assess the optimal

treatment modality for the treatment of neck of femur fractures, resulting in the best clinical and functional outcomes while minimising the complication rates.

### Aim of the Study

To determine whether total hip replacement is clinically and functionally better than bipolar hemiarthroplasty in neck of femur fracture in older patients.

### Materials and Methods

The present study is an analytical cross-sectional study conducted in Department of Orthopaedics at Sri Ramachandra Medical College and Research institute, Chennai. The study participants were 70 patients diagnosed with unstable neck of femur fractures who were treated with bipolar hemiarthroplasty and total hip replacement. The study duration was from April 2016 to September 2018. The patients who underwent total hip replacement were chosen and categorized as Group 1 (35 cases) and those patients who underwent bipolar hemiarthroplasty were categorized as Group 2 (35 cases).

The inclusion criteria was patients more than 60 years of age and the unstable neck of femur fractures (Garden classification). The exclusion criteria were pathological fractures, patients aged less than 60 years, associated fracture of lower limbs and non-ambulatory patients prior to injury.

### Procedure

Pre-operative treatment protocol - The general condition, clinical and radiological evaluation of the patients was assessed at the time of admission. Any pre-existing comorbidities were taken in to account. The injured limb was

immobilized using skin traction till the day of surgery. Patients received either mechanical or chemical thromboprophylaxis following injury. Patients were taken up for surgery after obtaining medical fitness. Radiographs of the pelvis with both hips and antero-posterior and lateral views of the affected hip were taken. The Garden system of classification was used to classify the fractures.

### Surgical Procedure

Prior to surgical draping, the skin is cleansed thoroughly with three applications of povidone iodine solution. Intravenous antibiotic prophylaxis with 1.5g of cephoperazone and sulbactam was administered to all patients half an hour prior to incision.

### Procedure for Bipolar Hemi-Arthroplasty

Epidural anaesthesia, which aids in post-operative analgesia, was administered to the patient, following which the patient is positioned in the lateral decubitus position. Adopting the Posterior Moore approach, the skin is incised 10cm distal to the posterior superior iliac spine and extended along the posterior border of the greater trochanter. Superficial dissection is carried out, the subcutaneous tissue is dissected and the deep fascia is incised, by blunt dissection within 7cm of the greater trochanter, the fibres of the gluteus maximus are carefully separated to preserve the branches of the inferior gluteal nerves and vessels.

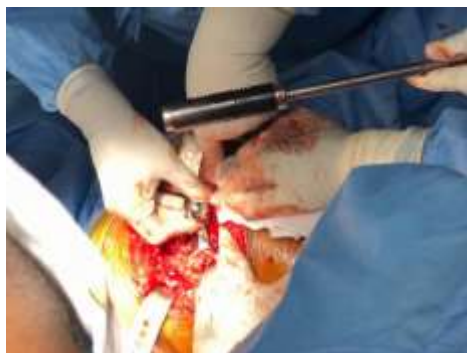The fibres of the gluteus maximus are then retracted to expose the greater trochanter, following which the sciatic nerve is identified and isolated. The gemelli, piriformis and the obturator internus are retracted and the posterior joint capsule is visualised. The capsule is then incised, the distal part of which is subsequently detached from the femur. An oscillating saw is then used to carefully remove the neck of femur with the neck fragment, while preserving the integrity of the greater trochanter and the abductor musculature.

The size of the head is measured and the femoral canal is adequately prepared using broaches (in approximately 20° of anteversion). The prostheses frequently used in this study included the corail stem and the modular bipolar cup. Aiming to attain maximum stability, a trial reduction is performed to assess the necessary neck length offset and version. The femoral canal is then lavaged and dried. The femoral component is then impacted gently in to the femur achieving

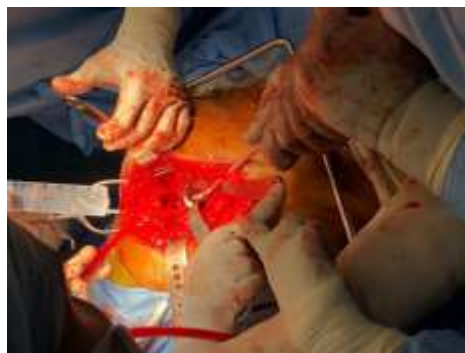good compaction at the inter-trochanteric line. If the greater trochanter is identified to be fractured and avulsed, it is pulled distally and fixed to the distal shaft fragment by tension band wiring technique. To hold it in place, circlage wires, which are used to align the postero-medial fragment may also be used. The wound is then thoroughly washed and a drain is placed in situ. The wound is subsequently closed in layers following which a sterile dressing is applied.

### Procedure for Total Hip replacement

Under general or epidural anaesthesia, the patient is placed in the lateral decubitus position. Parts are painted and the involved limb is draped freely. Adopting the postero-lateral approach, a 10-12-inch incision is made, beginning 5cm lateral to the greater trochanter, continuing proximally. The subcutaneous tissue is dissected and the iliotibial band is incised to expose the periosteum. Blunt dissection of the fibres of the gluteus maximus is carried out to the short rotators. The gluteus maximus is then retracted exposing the greater trochanter. The sciatic nerve is identified and preserved. The piriformis is then identified and tenotomised along with the short external rotators at their incision on the greater trochanter. The posterior joint capsule is thus visualised and incised, exposing the femoral neck and head. The head of femur is then dislocated and a femoral neck osteotomy is subsequently performed protecting the underlying soft tissues using Hohmann retractors. The acetabulum is then visualised and adequately prepared, verifying acetabular version and inclination. A reamer is used to reshape the acetabulum following which the acetabular cup prosthesis is placed in to the acetabulum. Exposure of the proximal femur is achieved with the patients leg internally rotated, flexed and adducted. Adequate femoral preparation is carried out and the prosthetic femoral stem is inserted in to it. Confirming ease of movement and ensuring the absence of any dislocation, the prosthetic ball is placed at the proximal end of the femoral stem articulating with the acetabular cup prosthesis and insert. The short external rotators and the posterior joint capsule are then repaired, the wound is thoroughly washed and a drain is placed in situ. The operative wound is closed in layers and a sterile dressing is applied.



Intra-Op



### Post-Operative Procedures

Adequate analgesia and IV antibiotics were administered to the patients for 48-72 hours post-operatively. Thrombo prophylactic measures were also carried out. Physiotherapy was initiated on the first post-operative day in the form of bed mobilisation, chest physiotherapy and deep breathing exercises. On the second post-operative day, following wound inspection, the drains were removed. The patients who underwent bipolar hemiarthroplasty were mobilised full weight bearing with the support of a walker on post-op day three and the patients who underwent THR were mobilised full weight bearing on the second post-op day. Sutures were removed on post-operative day 12.

Follow up - After being discharged from the hospital, patients were followed up and reviewed at regular intervals of 6 weeks, 3 months, 6 months and at the end of one year.

Functional assessment was carried out in both patient groups using the Harris Hip Score.

### Results

A higher incidence of fracture was found in the 70-79 age group in both total hip replacement (71%) and bipolar hemiarthroplasty (74%) groups.  $p$  value 0.12. The female population (52%) was observed to be more than the male population (48%) in this study. The female population was also found to be more prone for fractures in both -THR group (65%) and bipolar hemiarthroplasty group (60%).

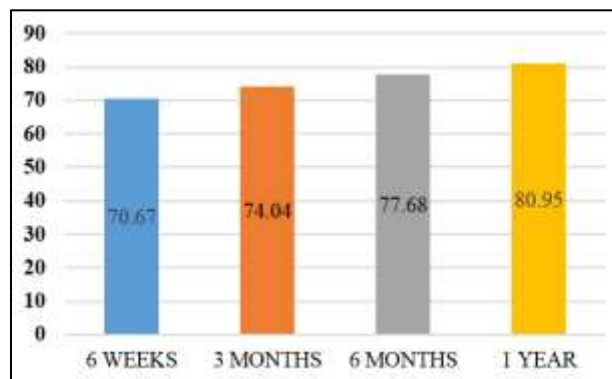
In the Total Hip Replacement group, the fractures were noted to be predominantly left sided (60%) whereas in the group that underwent bipolar hemiarthroplasty, predominantly right sided fractures were observed (56.70%). The mode of injury most commonly reported in this study, was accidental slip and fall with 86.7% of patients in the THR group and 86.7% in the bipolar hemiarthroplasty group.

The comorbidities associated were found to be higher overall in the group that underwent bipolar hemiarthroplasty. The mean operative time (in minutes) was observed to be lesser in the bipolar hemiarthroplasty group (109.3) when compared with the patient group that underwent total hip replacement (148.0). The mean operative blood loss (ml) was observed to be significantly lower in the group of patients who underwent bipolar hemiarthroplasty (191.3) in comparison to the total hip replacement group (228.0)  $p$  value 0.0005. The mean amount of blood transfusions was lower in the bipolar hemiarthroplasty group (20.3%) when compared to the THR group (23.3%).

The mean duration of stay in the hospital is lower in the THR group (6 days) when compared with the bipolar hemiarthroplasty group (8 days). The mean time till full weight bearing walking (days) was observed to be significantly reduced in the THR group (2.73 days) when

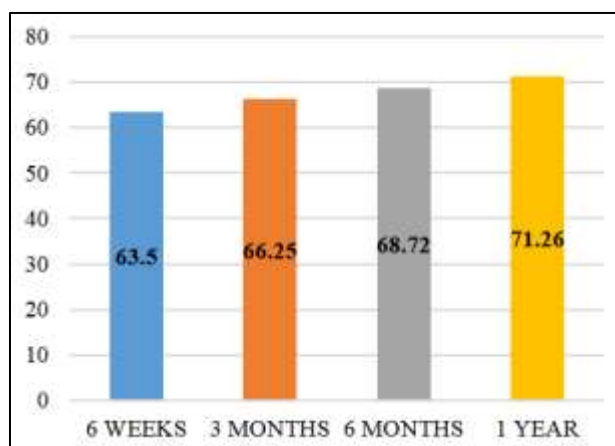
compared with the bipolar hemiarthroplasty group (3 days). The mean mortality rate in the THR group (3.3%) was observed to be lower than the bipolar hemiarthroplasty group (5.5%).  $p$  value 0.246.

A higher rate of complications was observed in the group of patients that underwent bipolar hemiarthroplasty in comparison to the THR group.



**Fig. 1: Harris hip score for total hip replacement**

The functional outcome of patients in both groups was analysed during their follow up at 6 weeks, 3 months, 6 months and after 1 year using the Harris Hip Score. In the above bar diagram described that the patient underwent total hip replacement, the mean Harris Hip Score was 70.6, 74.4, 77.68 and 80.95 at the follow up visits at week 6, 3 months, 6 months and 1 year respectively.  $p$  value 0.005.



**Fig. 2: Harris hip score for the bipolar hemiarthroplasty**

Fig. 2 explains that bipolar hemiarthroplasty, the mean Harris Hip Scores were 63.50, 66.25, 68.72 and 71.26 at the follow up visits at week 6, 3 months, 6 months and 1 year respectively.  $p$  value 0.005.

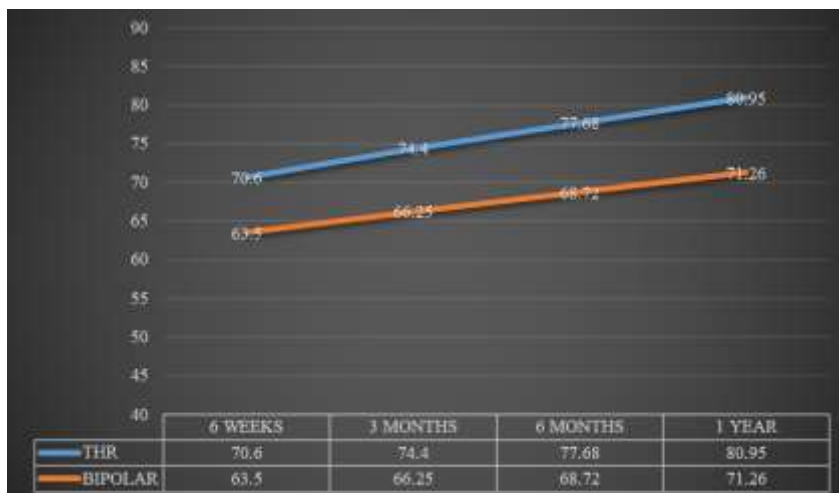


Fig. 3: Trend comparison between total hip replacement and bipolar arthroplasty

Table 1: Complications after the procedures

Complications	Total Hip Replacement	Bipolar hemiarthroplasty
Bed Sores	0	1
Chronic hip pain	0	4
Respiratory tract infections	0	1
Urinary tract infections	0	3
Shortening of > 2cm	0	0
Deep wound infections	1	1
Implant failure	1	1
Dislocation	0	0

**Discussion**

Neck of femur fractures are associated with significant morbidity and mortality in the vulnerable elderly population.<sup>4-6</sup> The debilitating consequences of hip fractures include a mortality rate of nearly 30% in addition to a substantial impairment of the quality of life of the patients.<sup>7</sup>

The management of displaced femoral neck fractures is still a subject of debate although a general consensus regarding the operative treatment of displaced neck of femur fractures exists.<sup>7</sup> The higher mean Harris Hip Score in the THR group reflected the better functional outcome when compared with the bipolar group<sup>8</sup> which was in agreement with the results obtained from our study.

With advancing age, a significant decrease in soft tissue bulk reduces the ability of the muscles and soft tissue to act as shock absorbers, further increasing the likelihood of these debilitating fractures in the elderly. The incidence of hip fractures is reportedly more in females when compared to males. With declining levels of oestrogen post-menopause, the (protective) effect of this hormone on maintaining bone density declines, contributing to the risk of fracture in post-menopausal women. Hip fractures followed by distal radius fractures are the most commonly reported.

In agreement with the population standard, in our study, both THR (65%) and bipolar hemiarthroplasty groups (60%) had a predominantly female population. This could be attributed to the reduced bone mineral density and post-menopausal osteoporosis.

The results from Group 1-that underwent THR were found to be superior to the results from Group 2 (bipolar hemiarthroplasty) in terms of better functional outcome, as assessed by the Harris Hip Score and shorter duration of stay in the hospital (6 days versus 8 days). The duration of surgery significantly impacts the treatment outcome in the elderly population. Prolonged surgery often predisposes the patient to higher risks of infection. However it was observed that although THR was associated with a higher operative time of 148 min. when compared to the 109.3 min of bipolar hemiarthroplasty (p value 0.931), complications were reportedly higher in the bipolar group which was in agreement with the findings published by Dawson et al.<sup>9</sup>

Although Dawson et al’s<sup>9</sup> retrospective study comparing hip-hemiarthroplasty with THR, reported no significant difference in the requirement of blood transfusions in the two cohorts (23.9% in each group), our study revealed that Total Hip Replacement had a higher mean requirement for transfusions (23.3%) when compared to Bipolar Hemiarthroplasty (20.3%) with a p value of 0.754.

In this study found a shorter mean duration of stay in the hospital in Total Hip Replacement (6 days) when compared with Bipolar Hemiarthroplasty (8 days). The longer duration of hospital stay after bipolar hemiarthroplasty potentially increases the risk of hospital acquired infections.<sup>9</sup>

In our study, the mean time (days) till full weight-bearing walking in Total Hip Replacement (2.70) is shorter than the results obtained from Bipolar Hemiarthroplasty (3). This was

in agreement with Baker et al<sup>10</sup> who reported that although THR and hemiarthroplasty were both associated with some degree of post-operative functional deterioration, the patients who underwent THR had less deterioration and maintained their walking distances. THR thus aids in rapid mobilisation of the patients and early return to functional independence.

### Complications

Wound infection has been reported to be the most frequent complication with hemiarthroplasty and the most frequent complication with after total hip arthroplasty.<sup>26</sup> Implant failure is a common complication with surgical fixation of neck of femur fracture.<sup>30,31</sup>

In our study only one case each of implant failure was identified in both groups which was in agreement with Bekerom et al<sup>11</sup> and Dawson et al.<sup>9</sup> Grade 1 bed sores over the gluteal region were observed in one patient (3.3%) in Bipolar hemiarthroplasty whereas none of the patients (0%) who underwent Total Hip Replacement developed bed sores. The bed sores following bipolar hemiarthroplasty could be attributed to the generalised weakness and hence poor compliance with post-operative mobilisation.

In our study, 3 patients in Group Bipolar Hemiarthroplasty who underwent bipolar hemiarthroplasty developed an UTI. It was reported by Yassa et al<sup>12</sup> that UTI predisposed the patient to the development of surgical site infections, however, Park et al<sup>13</sup> reported no significant association between UTI and peri-prosthetic joint infection.

A prospective evaluation of 2448 patients revealed that of the 20% patients who developed post-op complications (498/2448), 9% developed a respiratory tract infection.<sup>14</sup> In our study, one patient in bipolar hemiarthroplasty (3.3%) and none of the patients in Total hip replacement developed a chest infection.

Total hip arthroplasty when compared with bipolar hemiarthroplasty is superior with better functional outcomes, lower re-operation rates and significant improvement in the quality of life.<sup>15</sup> Although patient reported satisfaction approaches 90% after THR, some patients continue to experience chronic pain after elective surgery. In our one-year follow up study, 4 patients who had undergone bipolar hemiarthroplasty developed chronic hip pain. This could be potentially be attributed to articular cartilage degeneration in the acetabulum, infection or loosening of the prosthesis.<sup>16</sup>

The Harris Hip Score was significantly better in Total Hip Replacement when compared to the scores from Bipolar Hemiarthroplasty at the end of the follow-up period of 1 year (p value 0.0005). This was in agreement with the results from a study by Yu et al<sup>17</sup> which also reported higher Harris Hip Scores at 3, 4 years. Total hip arthroplasty is thus recommended over hemiarthroplasty for displaced neck of femur fractures in elderly patients owing to the higher Harris Hip Scores and lower re-operation rates.

During the one-year follow-up period, 3 patients in Total Hip Replacement and 5 patients in Group 2 Bipolar Hemiarthroplasty. The mean mortality rate for THR was observed to be 3.3% and 5.5% for bipolar hemiarthroplasty

(p value 0.246). However, the results were not statistically significant concurring with Baker et al<sup>10</sup> and Hopley et al.<sup>18</sup>

### Conclusion

The results obtained from this prospective and retrospective study comparing the clinical and functional outcomes after total hip replacement and bipolar hemiarthroplasty for neck of femur fractures in the elderly population indicate that both procedures are acceptable modalities of treatment for unstable neck of femur fractures. Total hip replacement, however is observed to be superior to bipolar hemiarthroplasty in terms of duration of hospital stay, immediate full-weight bearing walking and better functional outcomes with fewer complications.

**Conflict of Interest:** None.

### References

1. Petis S, Howard JL, Lanting BL. Surgical approach in primary total hip arthroplasty: anatomy, technique and clinical outcomes. *Can J Surg* 2015;58:128-39.
2. Blomfeldt R. Comparison of internal fixation with total hip replacement for displaced femoral neck fractures: randomized, controlled trial performed at four years. *J Bone Jt Surg* 2005;87:1680.
3. Rogmark C, Johnell O. Primary arthroplasty is better than internal fixation of displaced femoral neck fractures: A meta-analysis of 14 randomized studies with 2,289 patients. *Acta Orthop* 2006;77:359-67.
4. Giannoudis PV, Kontakis G, Christoforakis Z. Management, complications and clinical results of femoral head fractures. *Inj* 2009;40:1245-1251.
5. Nettleman MD, Alsip J, Schroder M. Predictors of mortality after acute hip fracture. *J Gen Intern Med JGIM* 1996;11:765-767.
6. Keene GS, Parker MJ, Pryor GA. Mortality and morbidity after hip fractures. *BMJ: Br Med J* 1993;307:1248-1250.
7. Bhandari M. Operative management of displaced femoral neck fractures in elderly patients: an international survey. *J Bone Jt Surg* 2005 87:2122.
8. Sharma V, Awasthi B, Kumar K. Outcome Analysis of Hemiarthroplasty vs. Total Hip Replacement in Displaced Femoral Neck Fractures in the Elderly. *J Clin Diagn Res JCDR* 2016;10:RC11-RC3.
9. Dawson D. Hip Hemi-Arthroplasty vs Total Hip Replacement for Displaced Intra-Capsular Hip Fractures: Retrospective Age and Sex Matched Cohort Study. *Ulster Med J* 87:17.
10. Baker RP, Squires B, Gargan MF. Total hip arthroplasty and hemiarthroplasty in mobile, independent patients with a displaced intracapsular fracture of the femoral neck. A randomized, controlled trial. *J Bone Jt Surg* 2006;88:2583-2589.
11. van den Bekerom MPJ, Hilverdink EF, Sierevelt IN. A comparison of hemiarthroplasty with total hip replacement for displaced intracapsular fracture of the femoral neck. *J Bone Jt Surg* 92:1422-1428.
12. Yassa RRD, Khalfauoi MY, Veravalli K. Pre-operative urinary tract infection: is it a risk factor for early surgical site infection with hip fracture surgery? A retrospective analysis. *JRSM open* 2017; 8:205427041667508.
13. Park CH, Lee Y-K, Koo K-H. Lower Urinary Tract Infection and Periprosthetic Joint Infection after Elective Primary Total Hip Arthroplasty. *Hip & Pelvis* 2017;29:30.

14. Jjw R. Effect of comorbidities and postoperative complications on mortality after hip fracture in elderly people: prospective observational cohort study. *BMJ : Br Med J* 2005;331.
15. Ferrata P, Carta S, Fortina M. Painful hip arthroplasty: definition. *Clin Cases miner and Bone Metab* 2011;8:19-22.
16. Taheriazam A. Conversion of failed hemiarthroplasty to total hip arthroplasty: A short-term follow-up study. *Med* 2017;96.
17. Yu L, Wang Y, Chen J. Total Hip Arthroplasty Versus Hemiarthroplasty for Displaced Femoral Neck Fractures: Meta-analysis of Randomized Trials. *Clin Orthop Relat Res* 2012;470:2235-2243.
18. Hopley C. Primary total hip arthroplasty versus hemiarthroplasty for displaced intracapsular hip fractures in older patients: systematic review. *BMJ : Br Med J* 2010;340.

**How to cite this article:** Aathithya S, Chowdhary MB. A comparison of hemiarthroplasty with total hip replacement for displaced fracture of femoral neck in the elderly. *Indian J Orthop Surg* 2019;5(1):46-51.