

## Management of both forearm bone diaphyseal fractures - ORIF v/s CRIF v/s hybrid fixation: An operative dilemma

Anil Nayak<sup>1</sup>, Zulfikar Patel<sup>2</sup>, Hriday Acharya<sup>3,\*</sup>, Dhaval Devani<sup>4</sup>

<sup>1</sup>Assistant Professor, Dept. of Orthopedics, GMERS, Medical College & Hospital, Patan, Gujarat,

<sup>2</sup>Associate Professor, <sup>3,4</sup>Resident, Dept. of Orthopedics, Civil Hospital, Ahmedabad, Gujarat, India

\*Corresponding Author: Hriday Acharya

Email: hridayacharya21@gmail.com

### Abstract

**Introduction:** Long bone fracture of forearm is common skeletal injury. The most common causes of such injuries include road traffic accident, fall or direct trauma, amongst the various types of forearm fractures, both-bone diaphyseal forearm fractures in adults are frequently met by the orthopaedic doctors. There are various methods available for fixation of both bone diaphyseal fractures like both bone plate fixation, both bone intramedullary nailing and hybrid method with nailing in one of the bones and plating in other. Our aim of the study is which method of fixation is most clinically justifiable in both bone diaphyseal fractures amongst all the available choices.

**Materials and Methods:** This is a retrospective study of 200 cases of diaphyseal fractures of radius ulna selected randomly over a period two year from March 2016 to March 2018 conducted at civil hospital Ahmedabad. All patients were followed up for a period 6 months post operatively.

**Result and Conclusion:** After studying result of all four method of fixation hybrid fixation showed good union rate, less chance of infection, less chance of malunion and non union, relatively good stability, less incidence of swelling and better recovery with a less chance of implant removal incidence and failure.

**Keywords:** Radius ulna fracture, Plating nailing, Both bone diaphyseal fracture.

### Introduction

Long bone fracture of forearm is common skeletal injury. The most common causes of such injuries include road traffic accident, fall or direct trauma.<sup>1</sup> AO has classified these fractures as

1. AO/OTA

a. 22

b. Fracture type

2. A = simple

3. B = Wedge

4. C = complex

a. Involved bones

5. 1 = ulna

6. 2 = radius

7. 3 = both bones

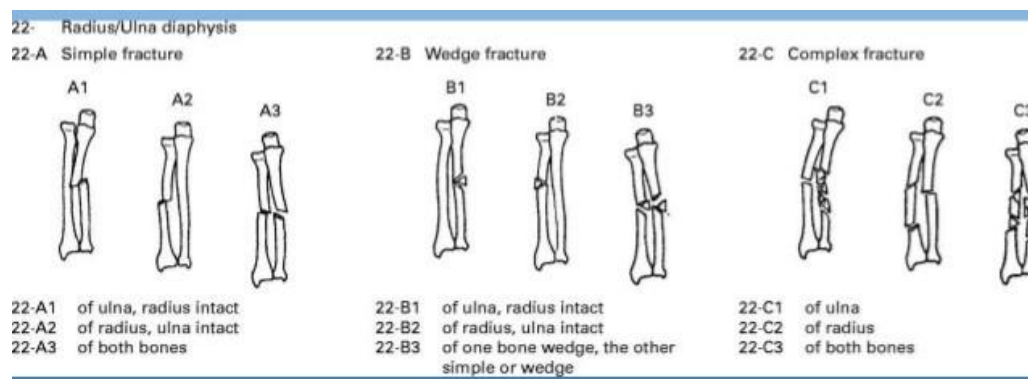


Fig. 1

Amongst the various types of forearm fractures, both-bone diaphyseal forearm fractures in adults are frequently met by the orthopaedic doctors in clinical practice which at times do our main focus is on AO 22-A3 There is various method of bone fixation

1. Radius ulna both plate fixation
2. Radius ulna both intramedullary nail fixation
3. Radius nail-ulna plate fixation
4. Radius plate -ulna nail fixation

The aim of our study was to evaluate the clinical outcomes of four different methods for fixation of both-bone diaphyseal fracture: plate fixation in both radius and ulna, IM nailing in radius and ulna both, plating of ulna and IM nailing in radius, and IM nailing of ulna and plate fixation of radius. Our aim of the study is which method of fixation is most clinically justifiable in both bone diaphyseal fractures amongst all the available choices.

### Materials and Methods

This is a retrospective study of 200 cases of diaphyseal fractures of radius ulna selected randomly over a period two year from March 2016 to March 2018 conducted at civil hospital Ahmedabad. All patients were followed up for a period 6 months post operatively.

#### Inclusion Criteria

1. Closed # shaft radius ulna
2. Open grade 1 # shaft radius ulna
3. Age 20-70yr

#### Exclusion Criteria

1. Open fractures more than open grade 1 fracture.
2. Pathological fractures
3. Only one bone #
4. Communicated #
5. Monteggia fracture.
6. Galezzie fracture.

**Techniques:** Patients were decided into four group

1. Group A :- 50 patient of Radius ulna both plate
2. Group B:- 50 patient of radius ulna both intramedullary nail
3. Group C : 50 patient of Radius nail-ulna plate
4. Group D:-50 patient of Radius plate –ulna nail

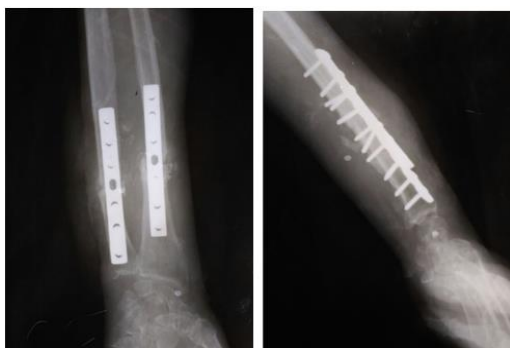

Fig. 2a: Group A

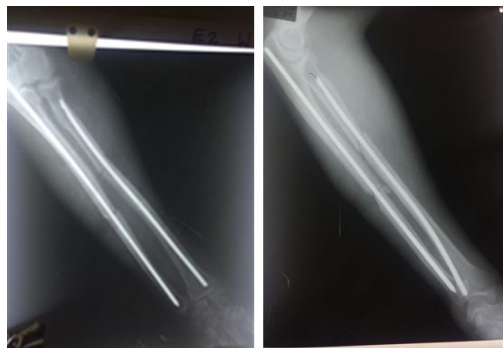

Fig. 2b: Group B

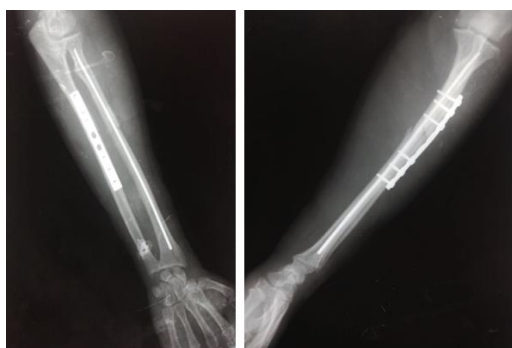

Fig. 2c: Group C

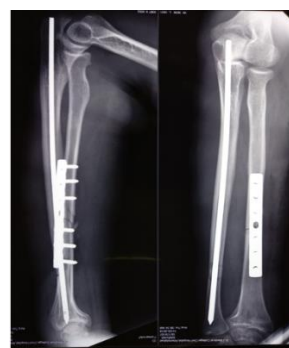

Fig. 2d: Group D

In plating we used 7 hole LCDCP plate with 3 screw both proximal and distal to fracture site.<sup>2</sup>

In intramedullary nailing ulna nail of appropriate size inserted after gaining entry from olecranon process and in radius nailing app. size ulna nail inserted through Size inserted after gaining entry from distal radius (listers' tubercle).

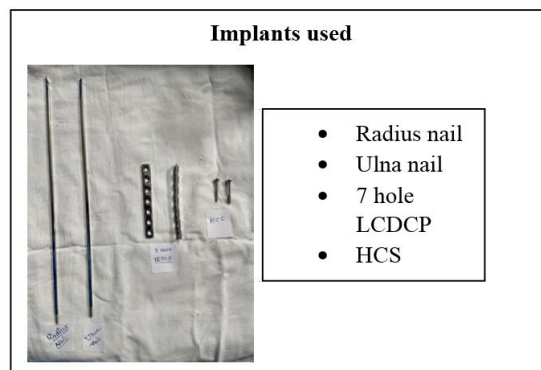


Fig. 3

**Post operative Care and Rehabilitation:** In all patients 2 sutureline dressing done one on 1 St post op day and one on 3<sup>rd</sup> post op day. In case of both plate immediate post-op crap bandage given and mobilisation exercise was started. But in case of radius nail + ulna plate and radius plate ulna nail postop slab given for 15 days and then mobilization exercise started. And in case of both nail postop slab given for 1.5 month and mobilization started.

## Results

In this study out of 200 case 140 were male and 60 were female indicating that the incidence of shaft radius ulna fracture is more common in male due to outdoor work. In our study age group distribution was as under:

1. Age 20-40 :- 92 patients
2. Age 40-60:-68 patients
3. Age> 70. :-40patients

Classification base on site of fracture

1. Proximal third: 37
2. Midshaft: 103
3. Distalthird: 60

**Operative time of Different Method:** Both radius ulna nailing had average time of 30 min while both radius ulna plating had maximum average time of 120 min and ulna plate radius nail have average time of 60 min and radius plate ulna nail had average time of 80 min

## Complications

1. **Non-union:** Group A had a 3patient with nonunion while group B has 0 patient of non union while

group C has 1 nonunion while group D has 0 patient of nonunion

2. **Malunion:** Group A had a 0 patient with malunion while group B has 5 patient of malunion while group C has 1 malunion while group D has 0 patient of malunion
3. **Post op Swelling:** Group A had a maximum incidence of Swelling while group B Had minimum incidence of swelling while group C and D had intermediate incidence of swelling. Post operative limb elevation, crape banadage or slab and medication were methods used to decrease swelling.
4. **Distal neurovascular deficit:** Group B had least no. Of DNVD while group A and D had 10% chance of EPL tendon injury. 3 Patients in group B had ehl weakness which was due to tendon injury rather than nerve injury.
5. **Infection:** Group A had a 4 patient with infection while group B has 0 patient of infection while group C has 3 infection while group D has 0 patient of infection
6. **Removal of Implant:** Group A had a 3 patient with removal of implant while group B has 5 patient of removal of implant while group C has 6 removal of implant while group D has 0 patient of removal of implant

**Hospital Stay:** Group A patient had average hospital stay of 5 day while group C and D had average rate of 4 day of stay and group b had average 1 day of hospital stay

**Table 1**

	Group A (Radius ulna both plate)	Group B (radius ulna both IM nail)	Group C (Radius nail + ulna plate)	Group D (Radius plate + ulna nail)
No of patient	50	50	50	50
Operation time (in min)	120	30	60	80
Incision size(cm)	20	6	14	15
nonunion	3	0	1	1
malunion	0	5	1	0
DNVD (including EHL weakness associated with tendon injury)	2	3	3	1
infection	4	0	3	0

## Discussion

Diaphyseal forearm fracture is one of common fractures of upper limb. The major cause of these fractures is road traffic accidents and direct trauma.<sup>3</sup> This makes it more common in younger age group and more common in male than female.<sup>4</sup> There are various methods available for fixation of these fractures and each of them have their pros and cons. Both plating method had very stable fixation with rotational stability and early mobilization while both nailing had less stable than plating and had no rotational stability but have lesser chance of swelling, infection, shorter

operative time, smaller wound size, preservation of fracture hematoma with no periosteal stripping hence less chances of implant failure which are relatively common in plating while hybrid method had both merit and demerit of the above methods.<sup>5,6</sup> There have been a few studies in the past describing about which method is better in these fractures. Our study compares the outcome of various modalities of treatment and also which of them is the best in Asian subcontinent with the available setup.

Tabet A et al conducted the study comparing the two method and found that Open reduction and internal

fixation with compression plates with strict adherence to surgical technique is the gold standard method of treatment in both bones forearm fractures with excellent results than closed reduction, internal fixation with “Talwarkar” square.<sup>7</sup> A similar study by X.F. Zhang et al stated that the hybrid fixation method of intramedullary nailing of ulna and plate fixation of radius showed good stability in biomechanics, fewer complications and better functional clinical outcomes.<sup>8</sup> A meta analysis conducted to compare these methods yielded similar radiographic outcomes, functional outcomes and complications in the treatment of adult diaphyseal both forearm bone. Intra medullary nail fixation for these fractures seems to be an alternative and effective treatment with shorter operating times and minimal invasion.<sup>9</sup>

In our study, it was found that IM nailing showed significantly shorter operative time, smaller incision size and periosteal stripping area compared with plate fixation, confirmed the advantages of intramedullary nail fixation. The results showed the two methods had similar complication rate. However, there were 4 cases of delayed union and 4 cases of infections in group A, while 5 cases of malunion and 3 cases of radial nerve injury in group B. This could be explained by several reasons. On one hand, plate fixation requires large incision and attaching a rigid plate inhibits the blood supply of periosteum. On the other hand, the rotational alignment may be difficult with IM nailing and this method is associated with the neurovascular injury patients in group D (IM nailing fixation of ulna and plate fixation of radius) presented fewer complications and better functional outcomes compared with other three methods. One possible reason for this may be due to the special anatomical characteristics of ulna and radius. The ulna is relatively straight compared with radius, which was easier for the insertion of intramedullary nail and decreased surgical trauma. The advantage of plate fixation of radius was the rigid stabilization limiting the rotation of radius.

The results showed that both-bone IM nailing method presented with shorter operative time, smaller wound size and periosteal stripping area, that both-bone plate fixation method presented with better biomechanical stability, and that the hybrid fixation method with IM nailing of ulna and plate fixation of radius showed better biomechanical stability, fewer complications and well functional outcomes.

### Conclusion

After studying result of all four method of fixation hybrid fixation with radius plate ulna nail showed good union rate, less chance of infection, less chance of malunion and non union, relatively good stability, less incidence of swelling and better recovery with a less chance of implant removal incidence and failure. Hence this is our recommended method of fixation of both bone diaphyseal fractures.

### References

1. Frederick M Azar, MD, S. Terry Canale, MD and James H. Beaty, Campbells' operative orthopedics Vol-4, Thirteenth Edition.
2. Saikia K, Bhuyan S, Bhattacharya T, Borgohain M, Jitesh P, Ahmed F. Internal fixation of fractures of both bones forearm: Comparison of locked compression and limited contact dynamic compression plate. *Indian Journal of Orthopaedics*. 2011;45(5):417-421.
3. Alffram PA, Bauer GC. Epidemiology of fractures of the forearm. *J Bone Joint Surg Am*. 1962;44(1):105-14.
4. Court-Brown CM, Caesar B. Epidemiology of adult fractures: a review. *Injury*. 2006;37(8):691-7.
5. Anderson LD, Sisk D, Tooms RE, Park WI. Compression-plate fixation in acute diaphyseal fractures of the radius and ulna. *J Bone Joint Surg Am*. 1975;57(3):287.
6. Amit Y, Salai M, Chechik A, Blankstein A, Horoszowski H. Closing intramedullary nailing for the treatment of diaphyseal forearm fractures in adolescence: a preliminary report. *Journal of Pediatric Orthopaedics*. 1985;5(2):143.
7. Tabet A. Al-Sadek Desislav Niklev Ahmed Al-Sadek., Diaphyseal Fractures of the Forearm in Adults, Plating Or Intramedullary Nailing Is a Better Option for the Treatment?, *Open Access Maced J Med Sci*. 2016;4(4):670-673.
8. X.F. Zhang, J.W. Huang, H.X. Mao, W.B. Chen, Y. Luo, Adult diaphyseal both-bone forearm fractures: A clinical and biomechanical comparison of four different fixations, *Orthop Traumatol Surg Res*. 2016;102(3):319-25.
9. Comparison of intramedullary nailing versus plating fixation in the treatment of adult diaphyseal both-bone forearm fractures: a meta-analysis. *Int J Clin Exp Med* 2017;10(8):11360-11370.

**How to cite this article:** Nayak A, Patel Z, Acharya H, Devani D. Management of both forearm bone diaphyseal fractures - ORIF v/s CRIF v/s hybrid fixation: An operative dilemma. *Indian J Orthop Surg*. 2018;4(3):221-224.