

Clinicopathological study of conjunctival and epibulbar lesions

Ravindra Banakar¹, Shruti Muddebihal^{2,*}

¹Professor and HOD, ²Post Graduate, Dept. of Ophthalmology, JJM Medical College, Davangere, Karnataka, India

*Corresponding Author: Shruti Muddebihal

Email: drshruti.ms@gmail.com

Abstract

Purpose: A retrospective study conducted to evaluate the profile of patients with conjunctival and epibulbar lesions who underwent surgical excision with or without ocular surface reconstruction.

Setting: This study included 126 patients of either sex diagnosed to have benign and malignant tumors of conjunctiva, eyelid and orbit who were subjected to excision biopsy.

Materials and Methods: A retrospective chart review of all patients treated between 2009 to 2015 was done. Only those patients whose clinical diagnosis was confirmed by histopathology examination were included.

Results: Of the 126 patients 66(52.38%) were males and 60(47.62%) were females with mean age 40.77 years (1-80years). In a total 126 patients conjunctival tumors were found in 46(36.50%), lid lesions in 53(42.06%) and orbital lesions in 27(21.42%).

Keywords: Conjunctival lesions, Epibulbar lesions.

Introduction

Eyelid tumors are rarely lethal, but late diagnosis of the tumors requires more invasive surgery and consequently will have adverse esthetic effects. Cutaneous periocular tumors can block vision or alter the normal shape of the eyelids. Malignant tumors such as basal cell carcinoma (BCC), squamous cell carcinoma (SCC), sebaceous gland carcinoma (SGC), and malignant melanoma can affect the eyelids leading to morbidity or even mortality. The incidence of eyelid skin tumors is mostly a result of environmental factors including sunlight and ultra violet exposure and genetic factors including skin pigmentation. Therefore, the prevalence of these types of tumors shows a geographical variation.

Excised lesions of the conjunctiva include a wide spectrum of conditions ranging from benign lesions to malignant. The conjunctiva is readily visible, so related lesions that occur in the conjunctiva are generally recognized at a relatively early stage. Benign lesions include dermolipoma, papilloma and dermoid, conjunctival cyst, polyp and sebaceous cyst.

There has been a less focus on the conjunctival and epibulbar lesions occurring in a rural population and the aim of this prospective study was to determine the frequency of the most commonly excised conjunctival and epibulbar lesions in a cohort of subjects with histopathologically confirmed diagnoses over a 7-year period in a rural population.

Aims of this study were to evaluate the clinicopathological spectrum of conjunctival and epibulbar lesions.

Materials and Methods

This retrospective study was conducted in the Dept. of Ophthalmology after obtaining approval from the Institutional Review Board. It included all patients with conjunctival and epibulbar lesions who underwent surgical excision with or without ocular surface reconstruction at our institution between 2009-2015.

Inclusion Criteria: Only those patients with benign and malignant tumors of conjunctival and eyelid and orbit whose clinical diagnosis was confirmed by histopathological examination were included.

Exclusion Criteria: Patients with traumatic and infective lesions of eyelids, orbit and conjunctiva were excluded.

The demographic details including age, gender and clinical findings related to the tumor such as laterality, site, number and clinical diagnosis were noted.

The histological type of the tumor were determined from histopathological study report of the patient.

Results

A total of 126 patients were include in the study. Retrieved specimens examined in the pathology department for a period of 7 years 2009 to 2015. 66(52.38%) were from males and 60 (47.62%) for females. The mean age of the cohort was 40.77 years (range, 1–80 years) of 126 specimen (46 conjunctival lesions, 53 lid lesions, 27 orbital lesions) were retrieved and analysed.

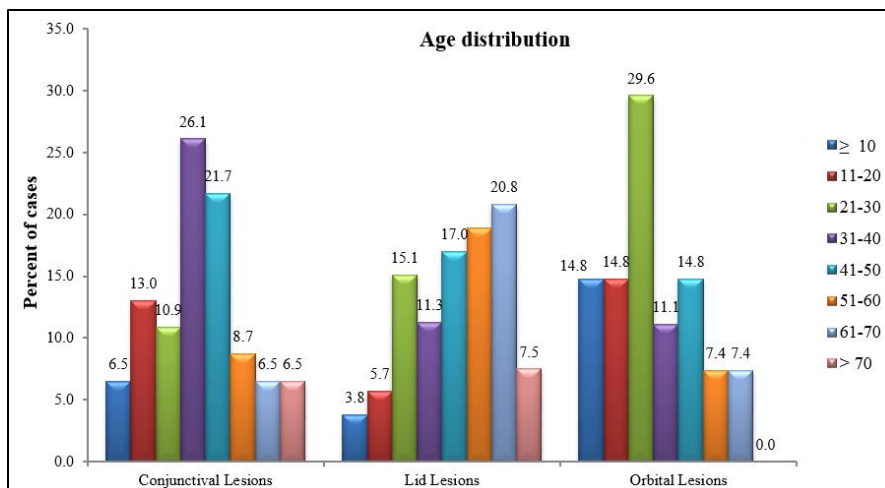


Fig. 1: Age distribution of lesions

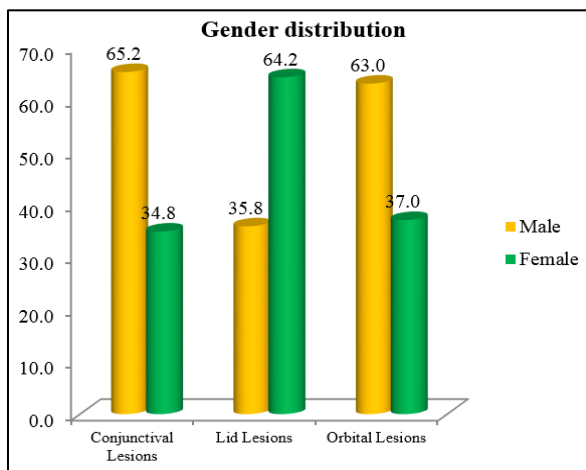


Fig. 2: Gender distribution of lesions

Conjunctival Lesions: Conjunctival lesions were found in 46 patients. The age of patients ranged between 3-80 years with mean age of 38.15 years.

Out of 46 conjunctival lesions 39 cases (84.8%) were diagnosed as benign lesions, 7 cases (15.2%) were

diagnosed as malignant on clinical examination. On histopathological examination 2 cases thought to be benign lesions were malignant.

The conjunctival lesions encountered in the study as depicted in the table

Table 1: Conjunctival lesions

Benign lesions	Number of cases	Percentage
Chalazion	9	24.32%
Naevi	8	21.62%
Conjunctival inclusion cyst	4	10.81%
Pterygia with cystic degeneration	4	10.81%
Pyogenic granuloma	2	5.40%
Dermolipoma	2	5.40%
Squamous papilloma	1	2.70%
Epidermoid cyst	1	2.70%
Conjunctival polyp	1	2.70%
Subconjunctival herniation of fat	1	2.70%
lymphangioma	1	2.70%
Periocular amyloidosis	1	2.70%
Rhinosporidiosis of conjunctiva	1	2.70%
Dermoid cyst caruncle	1	2.70%

Gender distribution of lesions

Among 46 lesions 30 (65.2%) patients were males and 16 (34.8%) patients were females.

Table 2: Gender distribution of lesions

Conjunctival Lesions					
Gender	Histopathological Diagnoses				Total
	Benign	%	Malignant	%	
Male	24	64.86	6	66.66	30
Female	13	35.13	3	33.33	16
Total	37	100	9	100	46

Malignant Lesions: Conjunctival intraepithelial neoplasia was the malignant lesion noted in 9 cases (19.50%).

Among 9 cases (19.50%) of Conjunctival intraepithelial neoplasia reported in this study has higher incidence among males 6 (66.66%).

Out of 37 benign lesions 24 (64.80%) were males, 13 (35.13%) were females. Among malignant lesions 6 (66.66%) were males and 3 (33.33%) were females indicating prevalence of conjunctival lesions in males more than females for both benign and malignant conditions.

Clinical diagnosis was consistent with histopathological diagnosis in 96% of cases.

Lid Lesions: Lid lesions were found in 53 cases. The age of patients ranged between 3-80 years with mean age of 48.08 years.

Among 53 cases of lid lesions 33 (62.26%) cases comprised of benign lid lesions and 20 (37.73%) cases were malignant on both clinical and histopathological examination.

Lid lesions encountered in the study are

Table 3: Lid lesions

Benign lesions	No of cases	Percentage	Malignant lesions	No of cases	Percentage
Intradermal naevus	9	27.27%	Basal cell carcinoma	9	45%
Epidermal cyst	8	24.24%	Squamous cell carcinoma	3	15%
Chronic inflammatory lesion	4	12.12%	Sebaceous cell carcinoma	6	30%
Squamous papilloma	2	6.06%	Apocrine hydrocystoma	1	5%
Apocrine hidradenoma	2	6.06%	Undifferentiated carcinoma	1	5%
Capillary haemangioma	2	6.06%	Total	20	100
Dermoid cyst	1	3.03%			
Inflamed chalazion	1	3.03%			
Amyloidosis	1	3.03%			
Syringocystadenoma papilliforme	1	3.03%			
Foreign body reaction	1	3.03%			
Dermolipoma	1	3.03%			

Gender Distribution

Among 53 cases studied 19(35.8%) cases were seen in males and 34(64.2%) seen in females.

Table 4: Gender distribution of lesions

Lid Lesions					
Gender	Histopathological Diagnoses				Total
	Benign		Malignant		
Male	13	39.39%	6	30%	19
Female	20	60.60%	14	70%	34
Total	33	100	20	100	53

Of 33 benign lesions 13(39.39%) were seen in males and 20 (60.60%) in females. Among malignant conditions 6(30%) were in males and 14(70%) in females. Implies prevalence of lid lesions both benign and malignant are more common in females compared to males.

On histopathological examination of 1 case thought to be benign lesion was malignant.

Clinical diagnosis was consistent with histopathological diagnosis in 96% of cases.

Orbital Lesions: Orbital lesions examined were 27 cases. Age of patients ranging between 1-70 years with mean age of 36.10years.

Out of 27 cases studied, 17(62.96%) cases were benign lesions and 10(37.03%) were malignant both on clinical and histopathological diagnosis.

Orbital lesions encountered in the study are

Table 5: Orbital lesions

Benign lesions	Number of cases	Percentage	Malignant lesions	No of cases	Percentage
Lymphoproliferative lesion	3	17.64%	Solitary fibrous tumour	2	20
Pseudotumor	2	11.76%	Infiltrating well differentiated squamous cell carcinoma	3	30
Haemangioma	1	5.88%	basal cell carcinoma – eyelids (exentration)	3	30
Epidermoid cyst	1	5.88%	Alveolar soft part sarcoma – orbit	1	10
Necrotizing granulomatous inflammatory lesion	1	5.88%	Meningioma(extracranial)	1	10
Xanthogranulomatous lesion	1	5.88%	Total	10	100
Cysticercosis	1	5.88%			
solitary plasmacytoma	1	5.88%			
Idiopathic dacroadenitis	1	5.88%			
Benign mixed tumour	1	5.88%			
Dermoid cyst	1	5.88%			

Table 6: Gender distribution of lesions

Orbital Lesions					
Gender	Histopathological Diagnoses				Total
	Benign	%	Malignant	%	
Male	13	76.47%	4	40%	17
Female	4	23.52%	6	60%	10
Total	17	100	10	100	27

Clinical diagnosis was consistent with histopathological diagnosis in 100% of cases.

Discussion

Ophthalmic neoplasms are an important cause of morbidity and mortality. Incidence of benign lesions was higher as compared to malignant.

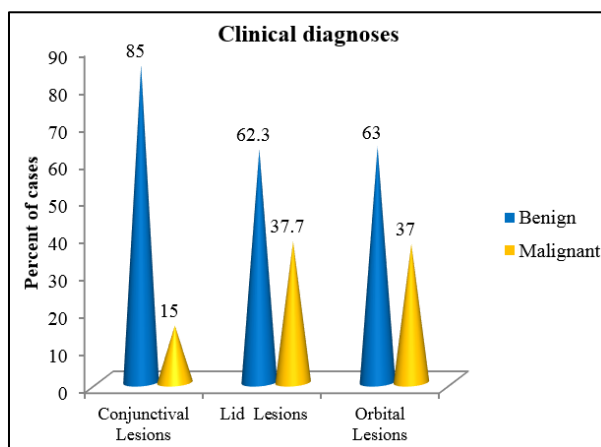


Fig. 3: Incidence of lesions

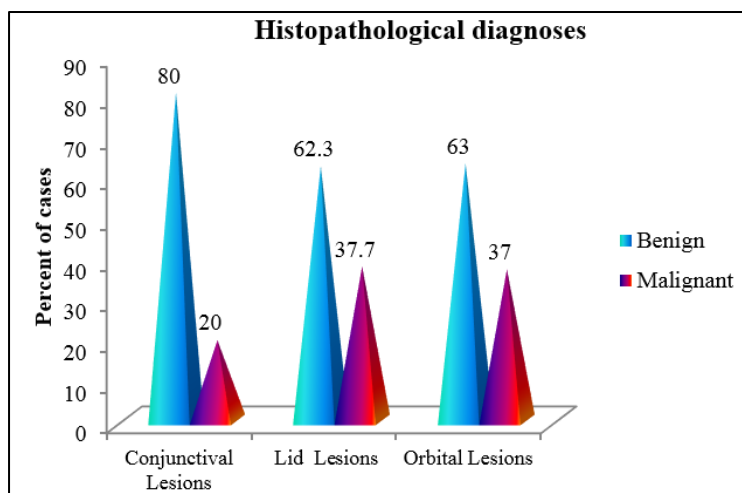


Fig. 4: Histopathological diagnosis of lesions

In this report, males outnumbered female subjects for conjunctival and orbital lesions. But ratio was reversed for lid lesions showing prevalence of lid lesions higher in females compared to males.

The conjunctiva is readily visible, so related lesions generally recognized at a relatively early stage.¹

Conjunctival tumors comprise a large variety of conditions from benign lesions such as squamous papilloma, or nevus, to malignant lesions such as melanoma or squamous cell carcinoma (SCC) which may cause visual loss. So, early diagnosis by conjunctival biopsies and treatment are essential to prevent ocular and systemic spread and to preserve visual function.²

The most frequent benign conjunctival lesions were chalazion 9(24.32%). It presents as slow growing painless, firm nodule in the tarsal plate which is visible through the skin. The lesion is lipogranulomatous inflammatory reaction to extravasated fat globules, around a meibomian gland with a blocked duct. Histopathology shows granulomas consisting of giant cells, epithelioid cells and other inflammatory cells around fat lobules.³

The two clinical misdiagnoses were foreign body granuloma and pterygium with degenerative changes.

Melanocytic nevi were the second most common benign conjunctival lesion 8(21.62%) which comparable with Laila Hassan et al study.⁴ Conjunctival nevi are mostly located near the limbus in the interpalpebral area. Other locations are the caruncle, semilunar folds, fornix, tarsus, and cornea. Characteristic clear cysts strongly support the diagnosis. They may also clinically demonstrate feeder vessels (64%) and intrinsic vascularity (77%). It can vary in size, color, and location. Conjunctival nevus can increase in size in growing young children, during puberty, pregnancy, and sun exposure. Malignant transformation was estimated to be <1%. Histopathologically, a conjunctival nevus is composed of nests of benign melanocytes in the stroma near the basal layers of the epithelium. Positive immunostaining for HMB-45 and Ki-67 are useful adjuncts in differentiating benign melanocytic lesion from suspected malignant entities.⁵

In this study, OSSN was the most frequent tumor as comparable with Laila Hassan et al study with higher incidence among males.⁴ Squamous cell carcinoma, a plaque-like, gelatinous, or papilliform growth, occurs in limbal and bulbar conjunctiva in the interpalpebral fissure zone of older individuals.⁶

Conjunctival defects more than 3 clock hours due to excision of large SCCs have been used to repair with tissue replacement techniques. The disadvantages of conjunctival tissue replacement techniques such as tissue foreshortening, symblepharon, pseudopterygium, and recurrence of tumor have encouraged clinicians to investigate alternative or adjuvant treatment options such as topical mitomycin C and 5-fluorouracil.⁷

In the study of Obata H et al most common benign lid lesion was intradermal nevus (21.33%) which was comparable to our study with incidence of 27.27%.⁸

Nevi are the third most common benign lesions encountered in the periocular region nevi arise initially as junctional nevi, which are typically flat, pigmented macules. Beyond the second decade, most nevi become compound, at which stage they appear as elevated, pigmented papules. Later in life, the pigmentation is lost, and the compound nevus remains as a minimally pigmented or amelanotic lesion. By age 70 years, virtually all nevi have become dermal nevi and have lost pigmentation. Nevi are frequently found on the eyelid margin, characteristically molded to the ocular surface. Asymptomatic benign nevi require no treatment, but malignant transformation of a junctional or compound nevus can occur in rare cases. Nevi may become symptomatic if they rub on the ocular surface or enlarge and obstruct vision. They are managed with shave excision or wedge resection.⁹

In the study of Obata H et al most common malignant lesion was sebaceous (meibomian) carcinoma (15%).⁸ But in our study the most common malignant lesion was Basal cell carcinoma followed by Squamous cell carcinoma. Basal cell carcinoma, the most common eyelid malignancy, accounts for approximately 90%–95% of malignant eyelid tumors. Basal cell carcinomas are often located on the lower eyelid margin (50%–60%) and near the medial canthus

(25%–30%). Less commonly, they may occur on the upper eyelid (15%) and lateral canthus (5%). Basal cell carcinomas may have many different clinical manifestations in the eyelid.⁹ The basosquamous carcinoma is an aggressive malignancy with a greater tendency to metastasise to distant sites. This tumour was reported in 3.6–8.2% of cases in other studies.¹⁰

In the study of Tesluk GC et al 14 the most common lesion of the eyelid was basal cell carcinoma, which represented 14.3% of the total and 82.4% of the malignant lesions which was comparable to our study.

In this study most common orbital benign lesion Lymphoproliferative lesion 3(17.64%). Lymphoproliferative lesions of the ocular adnexa constitute a heterogeneous group of neoplasms that are defined by clinical, histologic, immunologic, molecular, and genetic characteristics. Lymphoproliferative neoplasms account for more than 20% of all orbital tumors, presents as a gradually progressive, painless mass. Bone erosion or infiltration is usually not seen except with high-grade malignant lymphomas. Up to 50% of orbital lymphoproliferative lesions arise in the lacrimal fossa. Lymphomas in the retrobulbar fat may

appear more infiltrative. Approximately 17% of orbital lymphoid lesions occur bilaterally, but this does not necessarily indicate the presence of extraorbital disease.⁹

Most common malignant orbital lesion encountered were squamous cell carcinoma and basal cell carcinoma. Squamous cell carcinoma may metastasize through lymphatic transmission, blood borne transmission, or direct extension, often along nerves. Recurrences of squamous cell carcinoma should be treated with wide surgical resection, possibly including orbital exenteration or neck dissection, and may require collaboration with a head and neck cancer surgeon. Targeted therapy using hedgehog pathway and epidermal growth factor receptor (EGFR) inhibitors has shown promise in the treatment of orbital and periorcular basal cell carcinoma and cutaneous squamous cell carcinoma in patients who are not candidates for surgery.⁹ Solitary fibrous tumor is the second most common malignant lesion in our study. It is composed of spindle-shaped cells that are strongly CD34-positive on immunohistochemical studies. It can occur anywhere in the orbit. It may recur, undergo malignant degeneration, and metastasize if incompletely excised.

Table 7: Comparison of incidence of benign and malignant lesions with other studies

Name of the study	Benign	Malignant
Obata H et al study. 2005	73%	27%
Abdi U et al study, ¹¹ 1996	58.90%	41.10%
Tesluk GC et al. 1984 ¹²	82.60	17.40%
Present study; 2017	70.03%	29.97%

Premalignant and malignant tumors such as carcinoma, lymphoma, or melanoma are aggressive, which jeopardize the vision and may endanger the patient's life. Therefore, early diagnosis is important and their existence must be confirmed by biopsy with histologic evaluation. Surgery combined with different supporting therapies (cryotherapy, chemotherapy, or others) is required to treat these lesions and for achieving local control of the disease. The core of a good approach for treating conjunctival tumors continues to hinge on a good histopathologic study and diagnostic. So, clinicopathological correlation is crucial, requiring good communication between the clinician (ophthalmologist) and the pathologist.²

Conflict of Interest: None.

References

- Mondal SK, Banerjee A, Ghosh A. Histopathological study of conjunctival lesions. *J Indian Med Assoc* 2007;105:206,208, 212.
- Santosh K. Mondal, Dipanwita R. Nag. Conjunctival biopsies and ophthalmic lesions: A histopathologic study in eastern India. *Journal of Research in Medical Sciences* 2012.
- Zia Chaudhari, Murugesan Vanathi, Holland EJ. Post graduate ophthalmology. 1st edition: Jaypee Brothers Medical Publishers;2012.p-1352.
- Laila Hasan. *Middle East Afr J Ophthalmol* 2011;18(1):48–54.
- Santosh G Honavar and Fairouz P Manjandavida. Tumors of the ocular surface: A review. *Indian J Ophthalmol* 2015;63(3):187–203.
- Robert W. Weisenthal. Basic and clinical science course. AAO: Section 8 External disease and cornea. 2015-2016:p-231.
- Hemalatha Krishnamurthy, Manjuladevi N, Tanushree V, Venkatesgowda H.T, Bharathi M, Archana S, Shivani Nayak, Valijwala Ehatasham Ul Hak. Clinical and Histo-pathological Analysis of Conjunctival Tumours at a Tertiary Care Centre in Indian Population. *J Evol Med Dent Sci* 2014;3(58):13092-13100.
- Obata H, Aoki Y, Kukbota S, Kanai N, Tsuru T, Incidence of benign and malignant lesions of eyelid and conjunctival tumors. *Nippon Ganka Gakkai Zasshi* 2005;109(9):573- 579.
- Jill Annette Foster. Basic and clinical science course. AAO: Section 8 Orbit, Eyelid and Lacrimal system. 2015-2016:p-204,209,109,213,107.
- Rajendra Kumar. Clinicopathologic study of malignant eyelid tumours. *Clin Exp Optom* 2010;93:4:224–227.
- Abdi U, Tyagi N, Maheshwari V, Gogi R, Tyagi SP. Tumors of eyelid: a clinicopathologic study. *J Indian Med Assoc* 1996;94(11):405-409, 416, 418.
- Tesluk GC. Eyelid lesions: incidence and comparison of benign and malignant lesions. *Ann Ophthalmol* 1985;17(11):704-707.

How to cite this article: Banakar R, Muddebihal S. Clinicopathological study of conjunctival and epibulbar lesions. *Indian J Clin Exp Ophthalmol* 2019;5(1):108-113.