

## Analysis of ocular complications of isolated facial nerve paralysis in a teaching hospital

Sheetal<sup>1,\*</sup>, P Anuradha<sup>2</sup>

<sup>1</sup>Junior Resident, <sup>2</sup>Associate Professor, Dept. of Ophthalmology, Saveetha Medical College, Thandalam, Chennai, Tamil Nadu, India

\*Corresponding Author: Sheetal

Email: sheetalrjkmr@gmail.com

### Abstract

**Objective:** To analyze the various causes of facial nerve paralysis and its ocular complications (which can lead to permanent loss of vision) in our hospital.

**Design:** Prospective study.

**Materials and Methods:** A sample of 32 patients with facial nerve paralysis who attended our hospital for one year from October 2016 to September 2017 were taken for the study. A thorough neurological and ENT examination was done for all cases. Visual acuity, extra ocular movements, Bell's phenomenon, fluorescein staining of cornea, slit lamp examination and fundus examination was done for all cases.

**Results:** 22 cases were due to Bell's palsy (68.75%), 5 case were due to complication of mastoid & parotid surgery (15.62%), 3 cases were due to trauma (9.375%), one case was congenital (3.125) and one case was due to diabetes (3.12%). Only 10 cases (31.25%) showed corneal staining (exposure keratitis) of which only 3 cases required lateral tarsorrhaphy (9.375%).

**Conclusion:** Most common cause of isolated facial nerve paralysis was found to be Bell's palsy. Most common ocular complication was exposure keratopathy and rarely corneal ulceration.

**Keywords:** Bell's palsy, Fluorescein staining, Exposure keratitis, Lateral tarsorrhaphy.

### Introduction

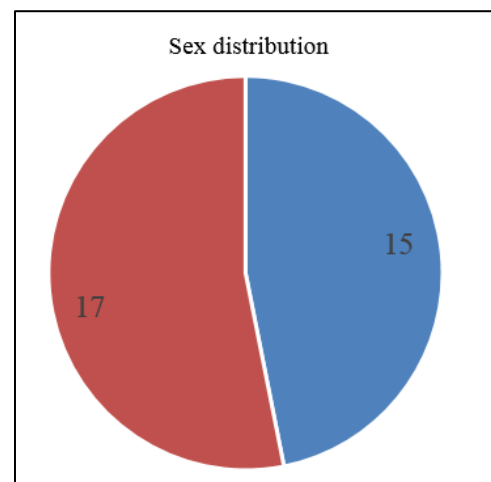
Impairment of functions of facial nerve can severely affect the quality of life. The facial nerve supplies the muscle of facial expression. Nerve passes through the temporal bone and is the longest nerve that travels in a bony canal with a complex course and high susceptibility to injury.<sup>1</sup> Facial nerve paralysis can produce significant impact on the patient both psychologically and in daily life, and should be treated in a timely manner. Management of peripheral facial paralysis may involve otolaryngologists, ophthalmologists, facial plastic surgeons and psychologists.<sup>2,3</sup> In Bell's palsy, oral steroids at early time often lead to good outcomes.<sup>4-7</sup> Steroids have reduced the duration of the palsy and risk of developing long term complications.<sup>8</sup>

Bell's palsy has been used in lieu of "idiopathic" facial paralysis in the past, referring to idiopathic paralysis from lower facial neuron disorders and requiring exclusion of other etiologies. David proposed the hypothesis that Bell's palsy is a result of herpes virus infection or its reactivation, which has been supported by some studies at serology levels using polymerase chain reaction (PCR) technology. Active invasion of the nerve by the virus could be the reason for the underlying pathology.

In adults, of all potential facial paralysis risk factors (including diabetes and pregnancy), only aging is supported by evidence. In children, Bell's palsy appears to be more common in cold seasons. Some have found that the incidence of Bell's palsy in pregnant women is 45.1/100,000, almost three times as high as in nonpregnant women of similar age, and possible causes may be hypercoagulability, elevated blood pressure, increased fluid load, virus infection and suppressed immunity.

### Materials and Methods

All patients with isolated facial nerve paralysis who attended our hospital from October 2016 to October 2017 were retrospectively analyzed. 32 patients record were collected, and study was done. 15 patients were male, and 17 patients were female.



**Fig. 1: Sex wise distribution of cases**

Age ranged between 20– 60 years. Average 34±5 years. There were no paediatric cases. For all cases visual acuity was recorded, extra ocular movement, corneal staining, slit lamp examination and fundus examination was done. Thorough neurological and ENT examination was done by neurologist and otolaryngologist. Radio-imaging were done as per requirement.

**Inclusion Criteria:** All cases of isolated facial nerve paralysis were taken up for the study.

**Exclusion Criteria:** Other cranial nerve involvement, old corneal scars.

## Results

Out of thirty-two cases of isolated Facial nerve paralysis, table 1 gives the various causes of the condition. All the cases of facial palsy were unilateral in our study.

**Table 1: Causes of Facial nerve paralysis**

S. No	Causes	Number of Patients (%)
1.	Bell's Palsy	22 (68.75%)
2.	Surgical trauma	5 (15.62%)
3.	Road traffic Accidents	3 (9.375%)
4.	Congenital	1 (3.12%)
5.	Diabetes	1 (3.12%)
	Total	32

The most common cause was Bell's palsy also called idiopathic facial nerve palsy. The incidence of Bell's palsy was most common between 25 and 40 years and it is less common below 20 and above 60 years. Of 32 patients, 15 were males (46.87%) and 17 were females (53.12%). The second most important cause of facial nerve palsy was trauma to the nerve during surgery performed for parotid tumor and middle ear surgeries. Three of the cases with severe head injury due to road traffic accident suffered facial nerve palsy, one of these three patients had hemotympanum and the imaging of the other two revealed one sided temporal bone fracture involving the facial canal. Of 32 one case presented with congenital facial palsy and the other one due to diabetes mellitus.

The most common symptom the patients had was watering of eyes followed by photophobia, decreased vision, dry eye, taste disorders. Few of them complained of post auricular pain and hearing loss. All patients were treated with oral prednisolone and acyclovir. Lubricant eye drops at daytime and lubricating gel at night were prescribed. In severe cases where the cornea was exposed on attempted lid closure in spite of good Bell's phenomenon, strapping of eyelids was advised.

All cases were given physiotherapy and severe cases were given galvanic stimulation. In spite of this regimen, 10 cases developed corneal staining for which lid strapping was done and prophylactic antibiotic eye drops were given.

Of these 10 patients, three patients developed severe congestion with corneal ulceration in the inferior part of cornea. Of 32, three patients were advised lateral tarsorrhaphy, of which two were due to post-surgical trauma and one was due to RTA.

**Table 2: Complications of facial nerve paralysis**

S. No.	Complication	Number	%
1	Watering	32	100
2	Corneal staining	10	31.25
3	Corneal ulceration	3	9.375

## Discussion

According to a study conducted by Chang Il Che in 2008, the mean age group of facial nerve palsy in adults was 48.6 years. Most common etiology being bells palsy (54.9%) followed by infection (26.8%) trauma (5.9%),

iatrogenic (2%), others like diabetes, Gullian barre syndrome contributed to 8.4%. 70% of facial palsy according to Vasque and LM was bell's palsy.<sup>1</sup> Also, according to Keane JR, most common cause of bilateral facial nerve palsy was bells palsy followed by GBS, intracranial tumors and encephalitis.<sup>3</sup> The results of our study coincided with these studies for the fact that most common cause of facial palsy was bell's palsy (68.75%) but the second most common cause was surgically induced trauma (15.62%) instead of infection followed by RTA (9.375%), congenital (3.125%) and diabetes (3.12%). Facial nerve palsy can cause reduction in vision, lack of facial expression and has a significant impact on social life. Therefore, evaluation and early rehabilitation of these patients is an important responsibility of an ophthalmologist.<sup>6</sup> In our study the most common complication was epiphora (100%) followed by exposure keratitis (31.25%) and corneal ulceration (9.735%) which agrees with the study conducted by Shyam et al where most complications were epiphora followed by exposure keratitis, paralytic ectropion, lid laxity and lid retraction.<sup>4</sup> The long-term sequelae results from the incomplete return of the facial motor function and synkinesis.<sup>16</sup>

The main aim of the treatment should ensure adequate corneal protection and restoration of blink mechanism. The surgical management includes gold weight implants for upper lid retraction, ectropion repair and temporary or permanent lateral tarsorrhaphy can be initiated when the cornea decompensates inspite of the supportive management.<sup>7</sup>

## Conclusion

Most common cause of isolated facial nerve paralysis was found to be Bell's palsy. Most common ocular complication was exposure keratopathy and rarely corneal ulceration. Early treatment of the patients with steroids had a faster recovery and less complications. Younger patients have a better prognosis than the older ones. Complete recovery is observed in most of the bell's palsy.

## Limitation of the Study

Long term complication could not be assessed due to lack of follow up.

**Conflict of Interest:** None.

## References

- Vásquez LM, Medel R. Lagophthalmos after facial palsy: current therapeutic options. *Ophthalmic Res* 2014;52(4):165-169.
- Cha CI, Hong CK, Park MS, Yeo SG. Comparison of facial nerve paralysis in adults and children. *Yonsei Med J* 2008;49(5):725-734.
- Keane JR. Bilateral seventh nerve palsy Analysis of 43 cases and review of the literature. *Neurol* 1994;44(7):1198.
- Prasad SS, Pershad V. Paralytic lagophthalmos and ophthalmic consequences. *Orbit* 1995;14(4):183-188.
- Zwick OM, Seiff SR. Supportive care of facial nerve palsy with temporary external eyelid weights. *Optom-J Am Optometric Assoc* 2006;77(7):340-342.

6. Lee V, Currie Z, Collin JR. Ophthalmic management of facial nerve palsy. *Eye* 2004;18(12):1225.
7. Holland NJ, Weiner GM. Recent developments in Bell's palsy. *BMJ: Br Med J* 2004;329(7465):553.
8. Davis RE, Telischi FF. Traumatic facial nerve injuries: review of diagnosis and treatment. *J Cranio-maxillofac Trauma* 1995;1(3):30-41.
9. Seiff SR, Chang J. Management of ophthalmic complications of facial nerve palsy. *Otolaryngol Clin North Am.* 1992;25(3):669-690.
10. Seiff SR, Chang JJ. The staged management of ophthalmic complications of facial nerve palsy. *Ophthalmic Plast Reconstr Surg* 1993;9(4):241-249.
11. Elner VM, Mauffray RO, Fante RG, Harris M, Morton AD, Hassan AS. Comprehensive midfacial elevation for ocular complications of facial nerve palsy. *Arch Facial Plast Surg* 2003;5(5):427-433.
12. Harrisberg BP, Singh RP, Crosson GR, Taylor RF, McCluskey PJ. Long-term outcome of gold eyelid weights in patients with facial nerve palsy. *Otol Neurotol* 2001;22(3):397-400.
13. Mavrikakis I. Facial nerve palsy: anatomy, etiology, evaluation, and management. *Orbit* 2008;27(6):466-474.
14. Fayad JN, Wanna GB, Micheletto JN, Parisier SC. Facial nerve paralysis following cochlear implant surgery. *Laryngoscope* 2003;113(8):1344-1346.
15. Hato N, Matsumoto S, Kasaki H, Takahashi H, Wakisaka H, Honda N, Gyo K, Murakami S, Yanagihara N. Efficacy of early treatment of Bell's palsy with oral acyclovir and prednisolone. *Otol Neurotol* 2003;24(6):948-951.
16. Gantz BJ, Rubinstein JT, Gidley P, Woodworth GG. Surgical management of Bell's palsy. *Laryngoscope* 1999;109(8):1177-1188.

**How to cite this article:** Sheetal, Anuradha P. Analysis of ocular complications of isolated facial nerve paralysis in a teaching hospital. *Indian J Clin Exp Ophthalmol* 2019;5(1):102-104.