

## Clinical staging and visual prognosis of patients with papilloedema

Rohit Agrawal<sup>1,\*</sup>, Pravin Tidake<sup>2</sup>

<sup>1</sup>Resident, <sup>2</sup>Professor, Dept. of Ophthalmology, Datta Meghe Institute of Medical Sciences, Maharashtra, India

\*Corresponding Author: Rohit Agrawal

Email: agrawaldrohit@gmail.com

### Abstract

**Introduction:** Papilledema is one of the true neuro ophthalmic emergencies. Most patients with elevated intra-cranial pressure (ICP) present to ophthalmologist with non-visual symptoms such as headache, nausea, vomiting and sometimes CSF rhinorrhoea. Patients may also note transient obscuration of visual (TOV) -episodes of unilateral or bilateral vision loss lasting 5-15 seconds. Papilledema serves as an important indicator and warning signal of intracranial pathology.

**Materials and Methods:** It was a cross-sectional study. Patients with papilloedema were examined for clinical stage (Early, Established, Chronic and Atrophic), aetiology, visual acuity, colour vision, contrast and perimetry.

**Results:** The most common aetiology for papilloedema was found to be ICSOL. Maximum number of patients were found to have early papilloedema. The correlation showed that visual acuity, colour vision and contrast were less affected in early stages of papilloedema as compared to late stages.

**Keywords:** Intra-cranial pressure, Papilledema.

### Introduction

Papilloedema is defined as passive, non-inflammatory oedema of optic disc, always bilateral, which results due to increased intracranial pressure.<sup>3</sup> In the absence of increased intra-cranial pressure (ICP), the swelling of the optic nerve head is called optic disc oedema. Chronic or atrophic papilledema usually reflects intracranial pathology, which results in bilateral optic nerve dysfunction.<sup>3</sup> Papilledema is one of the true neuro ophthalmic emergencies.<sup>1</sup> Papilledema serves as an important indicator and warning signal of intracranial pathology. Hence, here we want to study the Clinical staging and visual prognosis of patients of papilloedema.

### Materials and Methods

Aims of this study was to Clinical staging and visual prognosis of patients of papilloedema.

This cross-sectional study was done over a period of 2 years (October 2016-September 2018). The study was adhered to the tenets of the declaration of Helsinki, and it was approved by an institutional ethical committee of DMMSU.

Informed consent was obtained from all subjects after the nature and possible consequences of the study were explained to them.

All the procedures were conducted in the department of ophthalmology, AVBRH, Sawangi (Meghe), Wardha. Followings were inclusion and exclusion criteria.

#### Inclusion Criteria

1. Patients having pupillary reactions normal and afferent pupillary defect (APD).
2. Patients having papilloedema.
3. Age >5 years.
4. Patients giving informed consent.

#### Exclusion Criteria

1. Patients with altered sensorium.

2. Patients with hazy media impairing the visualization of the fundus.

3. Patients in whom dilation of pupil was contraindicated.

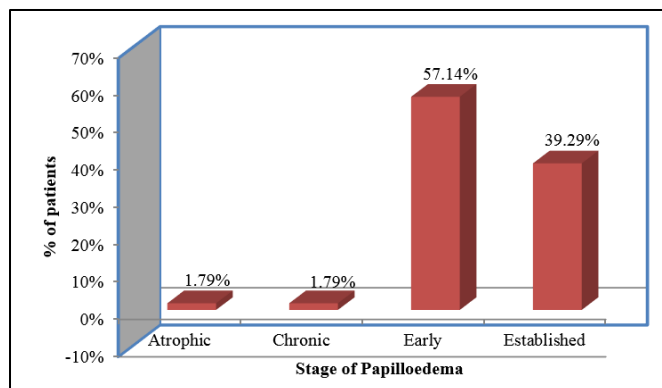
A comprehensive eye examination, including best corrected visual acuity (BCVA), slit lamp examination (SLE), intra ocular pressure (IOP) measurement and fundus examination, was performed in all patients- by direct, indirect ophthalmoscopy and slit lamp bio-microscopy. Statistical analysis was done using Chi-square test, and values were considered significant when  $p < 0.05$ .

### Results

In our study 56 patients were included in the age group above 5 years. Maximum number of patients were in age group 35-44 years i.e. 12 (21.43%) patients, followed by age group of 15-24 years which had 10 (17.86%) patients.

In our study maximum patients were male i.e. 36 (64.29%) patients. Male to female ratio was 2:1.

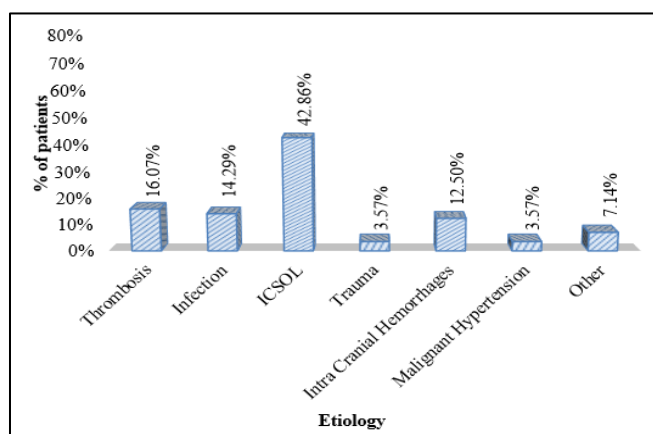
Early papilloedema was noted in 32 cases (57.14%), established papilloedema was found in 22 cases (39.29%) only 1(1.79%) case had chronic papilloedema and 1(1.79%) had atrophic papilloedema.



**Fig. 1: Distribution of patients according to stages of papilloedema**

On examination 37 patients i.e. 66.07% patients had BCVA between 6/12-6/6, followed by 15 (26.79%) patients who had BCVA between 6/36-6/18.

4 patients had visual acuity  $\leq 6/60$ . Out of these 4 patients 2 patients had macular oedema and 1 patient each belong to chronic and atrophic stage.



**Fig. 2: Distribution of patients according to etiology**

**Table 1: Distribution of patients according to colour vision**

Colour Vision	No of patients	Percentage (%)
Normal	54	96.43%
Abnormal	2	3.57%
Total	56	100

On examination colour vision by Ishihara charts it was found to be abnormal in 2 cases (3.57%) out of 56 cases.

In the patients with early papilloedema i.e. 32 (57.14%) patients, maximum patients i.e. 30 had visual acuity 6/12 and better.

In patients with established papilloedema i.e. 22 (39.29%) patients, maximum patients i.e. 13 had visual

acuity between 6/36-6/18. The cause decreased vision in established papilloedema was sub-retinal haemorrhage and retinal pigment epithelial changes at macula.

Thus best visual acuity was seen in patients with early papilloedema.

The correlation with stages of papilloedema and visual acuity came out to be significant.

$\chi^2$ -value=49.62, p-value=0.0001, Significant

**Table 2: Correlation between stages of papilloedema and aetiology**

Stage of Papilloedema	Thrombosis	Infection	ICSOL	Trauma	Intra Cranial Hemorrhages	Malignant Hypertension	Other
Atrophic	0(0%)	0(0%)	0(0%)	0(0%)	0(0%)	0(0%)	1(1.79%)
Chronic	0(0%)	0(0%)	0(0%)	0(0%)	0(0%)	1(1.79%)	0(0%)
Early	5(8.93%)	7(12.50%)	10(17.86%)	2(3.57%)	5(8.93%)	0(0%)	3(5.36%)
Established	4(7.14%)	1(1.79%)	14(25%)	0(0%)	2(3.57%)	1(1.79%)	0(0%)
Total	9(16.07%)	8(14.29%)	24(42.86%)	2(3.57%)	7(12.50%)	2(3.57%)	4(7.14%)

Out of 32 cases of early stage of papilloedema 31.25% was due to ICSOL, 21.87% caused due to infection and 15.62% were due to venous thrombosis and intra-cranial hemorrhages each. 6.25% was also caused by trauma.

Out of total 22 cases of established papilloedema 63.63% had ICSOL and 18.18% were due to venous thrombosis.

1 case of chronic papilloedema was due to malignant hypertension and 1 case of atrophic papilloedema was due to obstructive hydrocephalus.

The correlation between stages of papilloedema and its etiology came out to be significant according to chi-square test.

$\chi^2$ -value=50.91, p-value=0.0001, Significant

In the pediatric age group (5-14 years), most common cause of papilloedema was intra cranial infection (meningitis). In the age group of 25-34 years, most common cause of papilloedema was venous thrombosis. In the rest of the groups most common cause of papilloedema was ICSOL.

The correlation between age of patients and etiology of papilloedema came out to be significant according to chi-square test.

$\chi^2$ -value=68.57, p-value=0.006, Significant

Out of 56 patients, Perimetry was done in 47 patients only. 9 patients were not cooperative for Perimetry.

13 (27.65%) patients showed enlargement of blind spot on 24-2 perimetry.

5 (10.63%) patients had defective visual field and remaining 29(61.70%) patients had normal visual field.

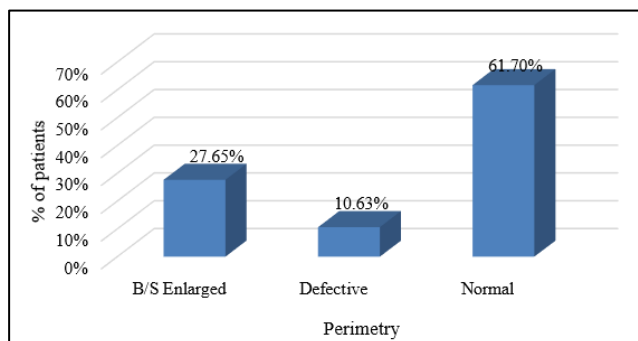


Fig. 3: Distribution of patients according to perimetry

Table 3: Distribution of patients according to contrast sensitivity

Contrast Sensitivity	No of patients	Percentage (%)
0-0.5	1	1.79%
0.6-1	2	3.57%
1.1-1.5	16	28.57%
1.6-2	33	58.93%
2.1-2.25	4	7.14%
Total	56	100%
Mean $\pm$ SD	1.64 $\pm$ 0.36(0-2.10)	

Contrast sensitivity was done using Pelli-Robson's chart.

Maximum number of patients i.e. 33 (58.93%) had contrast sensitivity ranging from 1.60-2.00, followed by 16 (28.57%) patients who had contrast sensitivity between 1.10-1.50.

Using chi-square test statistical analysis was done by descriptive and inferential statistics. P<0.05 was considered as the level of significance. SPSS 22.0 version and Graph Pad Prism 6.0 version software were used.

### Discussion

The majority of patients belonged to 35-44 years of age group which constitute about 21.43%, followed by 15-24 years of age group constituting 17.86% of patients. Only 1 patient was seen in >75 years of age group i.e. 1.79%.

Sivakalai,<sup>5</sup> et al in their study observed maximum number of patients were in 21-30 years age group i.e. 44% and least number of patients were in 51-60 years of age group.

In our study maximum patients were male i.e. 36 (64.29%) patients. Male to female ratio was 2:1.

In a study conducted by Sivakalai<sup>5</sup> et al showed a different result with female preponderance of 66.7%. Male: female ratio in this study was 1:2.

In a study conducted by D. Solanki<sup>6</sup> et al 42% affected were males and 58% females. The male: female ratio was 3:4.1.

In a study conducted by Ambika<sup>8</sup> et al on 50 patients of papilloedema, 40 were female i.e. male: female ratio was 1:4.

In our study maximum number of patients had early papilloedema which was 57.14%, followed by established papilloedema which was found in 39.29% of the patients. Chronic and atrophic papilloedema constituted 1 patient each i.e. 1.79%.

In a study conducted by Scott<sup>9</sup> et al on 36 patients of papilledema, showed that 47% of the patients had early papilledema followed by 22% patients who had chronic papilledema and 11% had established papilledema.

In study conducted by Ambika<sup>8</sup> et al in 50 patients of papilloedema due to idiopathic intracranial hypertension, 26 (52%) patients had early papilloedema, 10 (20%) patients had established papilloedema, 3 (6%) patients had chronic papilloedema, and 9 (18%) patients atrophic papilloedema.

In this study the visual acuity was tested by using snellen's chart at 6 meter distance and also finger counting. 66.07% patients had BCVA between 6/12-6/6, followed by 26.79% patients who had BCVA between 6/36-6/18. Only 4 patients in our study had visual acuity  $\leq$ 6/60.

In study conducted by Ambika<sup>8</sup> et al in 50 patients of papilloedema due to idiopathic intracranial hypertension, 26 patients had 6/6 visual acuity, 10 patients had 6/9-6/18 visual acuity, 3 patients had visual acuity 6/24-6/60, and 9 patients had acuity < 6/60.

In a study conducted by Sivakalai<sup>5</sup> et al 53.36% patients had visual acuity of 6/6.

In a study conducted by Mitalia<sup>10</sup> et al in a patient of neurocysticercosis i.e. a type of ICSOL found chronic papilloedema with visual acuity of no perception of light in the right eye and 6/12 in the left eye.

Out of 56 cases, in our study we observed 24 cases (42.86%) of papilloedema were having space occupying lesion as aetiology. 9 cases (16.07%) had venous thrombosis as an etiological factor for papilloedema. Intracranial infection such as meningitis and encephalitis was the cause in 8 cases (14.29%). In 2 cases (3.57%) trauma was etiological factor.

Similar results are found in a study done by Gower (1904) and Paton (1909) in which 77.9% patients of papilloedema were due to ICSOL out of 1239 patients.

In a study conducted by Blagojevic and Armbasic,<sup>12</sup> 1956, they found 23% of cases papilloedema belonged to tuberculous meningitis. Above result is similar to our study.

In a study conducted by D. Solanki<sup>6</sup> et al out of 50 patients, 24% cases of ICSOL in systemic causes followed by 12% cases of meningitis, 10% cases of malignant hypertension and 2% case of head injury. These results are found nearly similar with our study.

In the study by Br'egat<sup>13</sup> (1956) who analysed 734 cases of papilloedema found that 89% were due to cerebral tumours.

On examination colour vision by Ishihara charts it was found to be abnormal in 2 cases (3.57%) out of 56 cases in our study.

In study conducted by Ambika<sup>8</sup> et al on 50 patients of papilloedema, colour vision was done in 24 patients, out of which 58.33% i.e. 14 patients had normal colour vision and 41.67% i.e. 10 patients had abnormal colour vision.

In a study conducted by Michel<sup>15</sup> et al in 50 patients of papilloedema due to idiopathic intracranial hypertension, 8 patients had abnormal colour vision i.e. 16%.

In our study out of 32 cases of early stage of papilloedema 31.25% was due to ICSOL, 21.87% caused due to infection and 15.62% were due to venous thrombosis and intra-cranial haemorrhages each. 6.25% was also caused by trauma.

Out of total 22 cases of established papilloedema 63.63% had ICSOL and 18.18% were due to venous thrombosis. 1 case of chronic papilloedema was due to malignant hypertension and 1 case of atrophic papilloedema was due to obstructive hydrocephalus.

In our study, in the paediatric age group (5-14 years), maximum patients presented with early papilloedema i.e. 75%. Also early papilloedema was most common in the age groups of 15-24 years (70%), 25-34 years (87.5%) and 55-64 years (71.42%). While the age group of 35-44 years (66.66%), maximum patients presented with established papilloedema.

Walsh<sup>2</sup> reviewed the case records of the paediatrics department of the Johns Hopkins Hospital from 1928 to 1944 and found 18 cases of cerebral tumour in children 3 years of age or younger (26); 13 patients (72%) had papilledema.

In our study out of 56 patients, Perimetry was done in 47 patients only. 9 patients were not cooperative for Perimetry. 13 (27.65%) patients showed enlargement of blind spot on 24-2 perimetry. 5 (10.63%) patients had defective visual field and remaining 29(61.70%) patients had normal visual field.

Sivakalai<sup>5</sup> et al in their study found that 20 cases (44.4%) of papilledema had normal visual field pattern. 13 cases (28.9%) of papilledema had only blind spot enlargement. 6 cases (13.3%) of papilledema had defective visual field pattern.

In a study by F. Grehn<sup>17</sup> et al, 19 patients out of 31 eyes with chronic papilledema were found to have visual field defects other than enlarged blind spots.

In a study conducted by Sirisha<sup>16</sup> et al enlargement of blind spot was the most common visual field defect which was noted in 28 cases (56%). In 17 cases i.e. 34%, normal visual fields were noted.

These results are similar to our results.

Contrast sensitivity was done using Pelli-Robson's chart. Maximum number of patients i.e. 33 (58.93%) had contrast sensitivity ranging from 1.60-2.00, followed by 16 (28.57%) patients who had contrast sensitivity between 1.10-1.50. In 4 patients (7.14%) contrast was found to be between 2.10-2.25.

In a study conducted by Rusu<sup>21</sup> et al in diabetic patients suggested that Contrast sensitivity is the first of visual functions affected and the last to return to normal in neuro-ophthalmologic disorders.

In a study conducted by Michel<sup>15</sup> et al in 50 patients of papilloedema due to idiopathic intracranial hypertension, 25 patients i.e. 50% patients had reduced contrast sensitivity.

Out of 37 patients with visual acuity between 6/12-6/6, 78.38% patients i.e. 29 patients had contrast sensitivity between 1.60-2.00. Out of 15 patients with visual acuity between 6/36-6/18, 66.67% patients i.e. 10 patients had contrast sensitivity between 1.10-1.50. 50% Patients with visual acuity  $\leq 6/60$  had contrast sensitivity less than 1.1.

In a study done by Rowe<sup>19</sup> et al Pelli-Robson chart was used to measure contrast sensitivity. An abnormal response was often only obtained where a visual field defect of mild or moderate grade or visual acuity of 6/12 or less was documented.

## Conclusion

1. In our study the most common aetiology for papilledema was ICSOL.
2. Papilledema can be caused by a wide variety of conditions that result in increased ICP. The symptoms of papilledema ranges from headache to sudden or chronic loss of vision.
3. Visual prognosis establishment in a patient with papilloedema was often difficult.
4. Generally more severe the papilloedema, worse is the visual prognosis.
5. Disc pallor that becomes evident while papilloedema is present is an indication of poor visual prognosis, even if

ICP is lowered immediately, because the pallor is caused by axonal loss.

6. Once there is a decline in visual acuity and significant visual field deficits the visual prognosis is extremely poor.
7. A careful history, general and complete ophthalmological workup with necessary investigations like CT, MRI/MRV are mandatory to diagnose patients with papilledema. Since papilledema can be manifestations of life threatening condition, the ophthalmologist should be able to detect early papilledema and refer them immediately.
8. Therefore, in our study, we have found that early papilloedema has relatively good visual acuity, and normal / minimal field defects and by giving early medical treatment irreversible vision loss and optic atrophy can be prevented.

**Conflict of Interest:** None.

## References

1. Neuro Ophthalmology by Desmond P- Kidd, Nancy J. Newman, Vallevie Biousse; Page 280.
2. Deborah I. Friedman. PAPILLEDEMA. In: Walsh & Hoyt's Clinical Neuro-Ophthalmology. 6th Edition. p. 238–338.
3. Alfredo A. Sadun. Papilledema and Raised Intracranial Pressure. In: Ophthalmology by Yanoff & Dukers. Fourth. p. 875–9.
4. Zimmerman LE. Histology and general pathology of the optic nerve: Symposium on diseases of the optic nerve. *Trans Am Acad Ophthalmol Otolaryngol* 1956;60:14–30.
5. Sivakalai R. Clinical analysis of papilledema. [Internet] [masters]. Madras Medical College, Chennai; 2010 [cited 2018 Sep 13]. Available from: <http://repository-tnmgrmu.ac.in/2394/>
6. Solanki D, Meena V, Sharma U, Agrawal S. Optic disc edema/papilledema: a clinical profile [Internet]. Journal of Evolution of Medical and Dental Sciences. 2016 Available from: <http://link.galegroup.com/apps/doc/A470461638/AONE?sid=google scholar>
7. Saoji CP, Wadgaonkar SP, Patil PA, Kamble BS. The prospective study of clinico-etiological analysis on patients of papilloedema. *Indian J Clin Exp Ophthalmol* 2016;2(3):253.
8. Ambika S, Arjundas D, Noronha V, Anshuman. Clinical profile, evaluation, management and visual outcome of idiopathic intracranial hypertension in a neuro-ophthalmology clinic of a tertiary referral ophthalmic center in India. *Ann Indian Acad Neurol* 2010;13(1):37–41.
9. Scott CJ, Kardon RH, Lee AG, Frisén L, Wall M. Diagnosis and Grading of Papilledema in Patients With Raised Intracranial Pressure Using Optical Coherence Tomography vs Clinical Expert Assessment Using a Clinical Staging Scale. *Arch Ophthalmol* 2010;128(6):705–711.
10. Matalia J, Anaspure H, Kasturi N, Shetty BK. Chronic papilledema with vision loss as the presenting feature in racemose neurocysticercosis. *Can J Ophthalmol* 2014;49(1):e26–28.
11. Acute visual loss in papilloedema: the diagnostic pitfalls. - PubMed - NCBI [Internet]. [cited 2018 Sep 15]. Available from: <https://www.ncbi.nlm.nih.gov/pubmed/23749238>
12. Sir Stewart Duke –Elder. System of ophthalmology. *Neuro-Ophthalmol* Vol. XII. 34–41 p.
13. Sir Stewart Duke –Elder. Neuro-ophthalmology Duke & Elder's. In: System of Ophthalmology. p. 50–2.
14. Petrohelos MA, Henderson JW. The Ocular Findings of Intracranial Tumor\*: A Study of 358 Cases. *Am J Ophthalmol* 1951;34(10):1387–1394.
15. Wall M, George D. Idiopathic intracranial hypertension: a prospective study of 50 patients. *Brain* 1991;114A(1):155–180.
16. Sirisha G, Swetha S, Chowdary NL. Evaluation of Etiological Factors and Visual Field Defects in Patients with Papilloedema. 2016;3(9):3.
17. Grehn F, Knorr-Held S, Kommerell G. Glaucomatouslike visual field defects in chronic papilledema. *Albrecht Von Graefes Arch Für Klin Exp Ophthalmol* 1981;217(2):99–109.
18. al WM et. Visual field defects in idiopathic intracranial hypertension (pseudotumor cerebri). - PubMed - NCBI [Internet]. [cited 2018 Sep 13]. Available from: <https://www.ncbi.nlm.nih.gov/pubmed/6638133>
19. Rowe FJ, Sarkies NJ. Assessment of visual function in idiopathic intracranial hypertension: A prospective study. *Eye* 1998;12(1):111–118.
20. Wall M, White WN. Asymmetric papilledema in idiopathic intracranial hypertension: prospective interocular comparison of sensory visual function. *Invest Ophthalmol Vis Sci* 1998;39(1):134–142.
21. Rusu V, Mihai E, St A. Contrast Sensitivity in Diabetic Retinopathy. *Clin Asp.* 2014;2(3):193-195.

**How to cite this article:** Agrawal R, Tidake P. Clinical staging and visual prognosis of patients with papilloedema. *Indian J Clin Exp Ophthalmol* 2019;5(1):30-34.