

# Foreign body aspirations in children: A retrospective analysis in a tertiary care paediatric hospital

Sheetal K.<sup>1</sup>, Sandhya Ghodke<sup>2,\*</sup>

<sup>1</sup>Assistant Professor, <sup>2</sup>Senior Resident, Dept. of Anaesthesiology, Indira Gandhi Institute of Child Health, Bengaluru, Karnataka, India

**\*Corresponding Author: Sandhya Ghodke**

Email: sheetal.kotegar@gmail.com

Received: 11<sup>th</sup> August, 2018

Accepted: 20<sup>th</sup> November, 2018

## Abstract

A one year retrospective analysis of tracheobronchial foreign body aspiration done at a tertiary care paediatric referral hospital in south India admitted in one year span in 2016-2017. The anaesthetic management in these cases is one of challenging aspect in the retrieval of the foreign body. Most of these cases present as emergency and delay in proper management which results in serious morbidity and mortality. Bronchoscopy is required in most of these cases and because of the shared airway by anaesthetist and surgeon it becomes extremely challenging, requiring well trained and experienced team and can lead to disastrous situations if not managed in a proper and timely manner. Here we are discussing and analyzing the anaesthetic management and outcome of all these foreign body cases which had come to the operation theatre for foreign body removal in the one year from October 2016 to September 2017. Out of the 98 patients who had presented with features of tracheobronchial foreign body we were able to retrieve foreign bodies in 82.6% of the cases. The safest method to retrieve a airway foreign body is by using general anaesthesia.

**Keywords:** Tracheobronchial foreign bodies, Anaesthetic management, Outcome.

## Introduction

Foreign body aspiration is one of the most common emergencies in paediatrics and is a leading cause of mortality and morbidity in otherwise normal and healthy children.<sup>1</sup> It can be life threatening and if not properly managed can lead to chronic lung injury<sup>2</sup> and a lot of psychological stress to the child and family. Children mostly in the preschool age group out of curiosity, lack of the ability to assess the danger and lack of parental supervision can contribute to this hazard. In most these cases rigid bronchoscopy has to be performed for the differential diagnosis of suspected tracheobronchial foreign body. Sharing of the airway by both the anaesthesiologist and surgeon makes bronchoscopy a challenging affair requiring a careful planning and better communication skills between both the anaesthesiologist and surgeon.<sup>3</sup> This study analyses the anaesthetic management and outcome of tracheobronchial foreign body cases in paediatric age group in a span of one year in a tertiary care paediatric hospital setting.

## Materials and Methods

Medical records of all patients subjected to diagnostic and therapeutic bronchoscopy for suspected foreign body removal from October 2016 to September 2017 were studied retrospectively. The subjected data was collected as per age, sex, suspected history of foreign body aspiration, clinical features and their duration, location and type of foreign body based on physical examination and radiological evaluation, anaesthetic management and outcome, Intraoperative and postoperative complications if any, postoperative mechanical ventilation if required. All children underwent bronchoscopy using Storz rigid bronchoscope.

## Anaesthetic Management

General anaesthesia is the most preferred method for these patients with tracheobronchial foreign body. The problem faced by anaesthetist are these children will be full stomach as they arrive on emergency basis. In patients who were taken up with full stomach for the procedure, feeding tube was used to decompress the stomach before commencing the procedure. The other problem is the sharing of the airway with the surgeons. Rigid ventilating bronchoscope with optical light source has been used in all our patients.

After receiving the child in pre operative area, no child received any premedication. After securing a good intravenous access, children were induced with injection (inj) Thiopentone 3-4mg/kg intravenous (IV), along with oxygen with sevoflurane. For muscle relaxation inj succinylcholine 1.5mg/kg IV was administered and repeated as required with a maximum dose of 5mg/kg IV (Rocuronium was not used as it was not available) and lidocaine spray 2-3mg/kg was used in all children to facilitate bronchoscopy and prevent laryngospasm. Inj propofol boluses were used for maintenance of anaesthesia. Injection Dexamethasone 0.5mg/kg IV (as a institutional protocol given to all patient to prevent PONV), humidified oxygen, inj Hydrocortisone 2 mg/kg IV and nebulisation with bronchodilators was given in all our patients prophylactically. Patients were monitored continuously by pulse oximetry, NIBP and ECG.

Our main goals were to ensure adequate oxygenation, rapid return of airway reflexes, to prevent any laryngospasm, controlled cardiorespiratory reflexes.

In all patients, as per institutional protocol chest x-ray was taken 6 hours post operatively to assess lung expansion, to exclude pneumothorax and residual foreign body, if any.

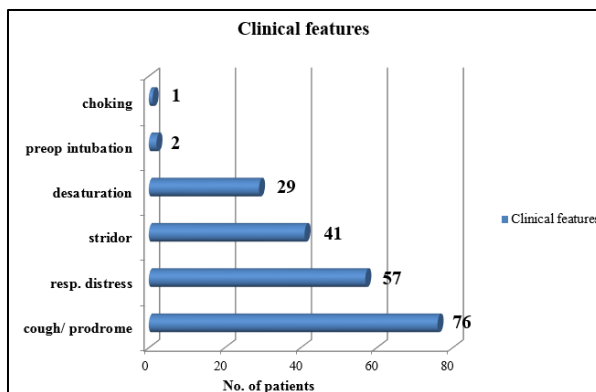
**Results**

Total 98 cases of suspected foreign body in airway required removal under anaesthesia in a span of one year, out of which 75 cases were of acute onset (76.5%) and 23 cases presented with prolonged duration of symptoms. 2/3rd (69.4%) of the cases had male preponderance. Also more than 50% of these were in the age group below 3 years of age, out of which 15.3% were below 1 year of age (Table 1).

**Table 1**

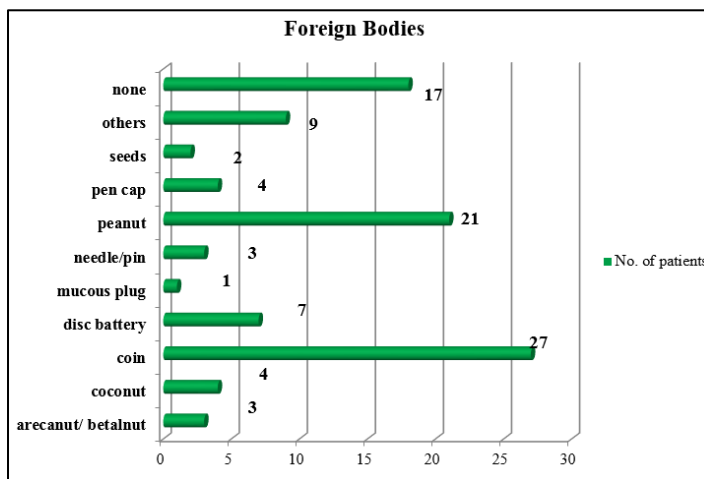
Age Distribution		
S. No.	Age in years	No. of patients
1	<1 year	15
2	1-3 years	50
3	3-5 years	15
4	>5 years	18

70 of the 98 cases came for emergency intervention, rest were posted as elective ones. 76 out of the 98 cases commonly had cough and other prodromal features, out of which 58.2% had respiratory distress as well. 41.8% of the cases also had stridor while 1/3<sup>rd</sup> of these presented with desaturation also (Fig. 1).



**Fig. 1**

63 cases underwent bronchoscopy, in 06 cases esophagoscopy was done, 29 patients underwent laryngoscopy out of which one patient required esophagoscopy as well. In 82.6% cases we were able to retrieve foreign bodies, while 17.3% had negative bronchoscopy. 34.7% patients had vegetative foreign bodies and most common in these were peanuts. Coconut pieces were retrieved in 04 patients, arecanut/ betelnut in 03 patients and fruit seeds in 02 patients. Coin was the most common non-vegetative foreign body retrieved during laryngoscopy followed by disc battery (Fig. 2).



**Fig. 2**

On bronchoscopy it was discovered that the most common site of lodgement of foreign bodies was in right main bronchus followed by left main bronchus (Table no. 2), while coin/ disc batteries were retrieved in 34 patients with laryngoesophagoscopy.

**Table 2: Location of foreign body in the airway**

S. No.	Location of FB	No. of patients
1	Cricopharynx	34
2	Right main bronchus (RMB)	21

3	Left main bronchus (LMB)	13
4	Left lower bronchus (LLB)	4
5	Trachea	3
6	LMB & Trachea	2
7	RMB & Trachea	1
8	Esophagus	3

More than 95% of the patients had some amount of laryngeal edema and approximately 70% had hoarseness of voice post procedure which subsided in due course of time. Almost 40 patients developed either desaturation upto SpO2 80% or bradycardia during the procedure which was treated

with adequate oxygenation and assisted ventilation with 100% oxygen. Of all the patients, 10 patients required intubation during or post procedure. 08 patients required postop ventilation and icu care, mostly these patients also had significant stridor and desaturation in preoperative period also (Fig. 3), out of which 02 were already intubated in preoperative period itself. Mostly these patients had vegetative foreign bodies (arecanut, coconut, peanuts) and

presented late features suggestive of airway foreign bodies. One patient had small cement balls in the airway, another had granite stone pieces. 02 patients who were already intubated in preoperative period and had negative bronchoscopies. In 01 patient foreign body was dislodged into stomach with esophagoscopy and was later retrieved per rectally. 01 patient each developed subcutaneous emphysema, seizures and choking. One patient had Down's syndrome.

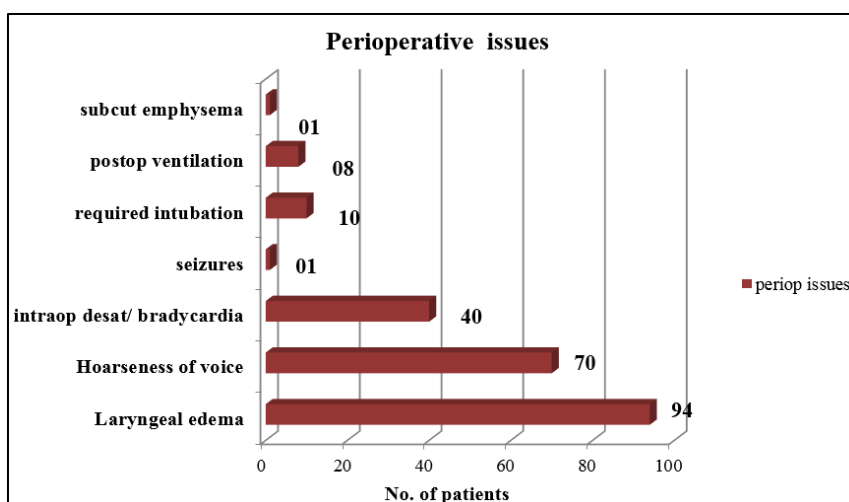


Fig. 3

## Discussion

The curiosity to explore things by mouth and lack of adequate supervision is the main reason for foreign body aspiration in the age group of 1-3 years. History of choking during eating is also significant during history taking. In our study more than 50% of the patients were below 3 years of age.<sup>4-6</sup> Also the incidence is almost twice more common in males as compared to females. In our study more than 2/3<sup>rd</sup> of these are seen in males which is in accordance with the previous studies.<sup>7,8</sup> Most common location is in right main bronchus followed by left which is in concurrence with the earlier studies.<sup>8-10</sup> However coin and disc batteries were found most commonly lodged in cricopharynx.<sup>10</sup> In few cases no foreign bodies were present.

The bronchoscopies / esophagoscopies performed were either diagnostic or therapeutic, majority being emergency procedures with general anaesthesia as the preferred technique.<sup>11</sup> Proper preanaesthetic assessment done in all the cases- bilateral air entry checked with focus on the location of the foreign body and the degree of airway obstruction, chest X-ray examined in order to determine the location of foreign body and to rule out secondary pathological changes like atelectasis, airtrapping or pneumonia, history of medical ailments elicited if any, preoperative oxygen saturation assessed, risk/high risk explained and written informed consent taken by parents/guardians.

In stable children preferred technique is intravenous induction. For muscle relaxation succinylcholine boluses are used as it is short acting, allowing controlled ventilation, allows less use of anaesthetic agents, prevents coughing and trauma and facilitates removal of foreign bodies through the

vocal cords.<sup>12</sup> All the patients were given 100% oxygen which was delivered through the sidearm of the bronchoscope by intermittent ventilation, sometimes requiring high flows of oxygen to compensate for the leak around the bronchoscope. However ventilation was also interrupted during suctioning and removal of foreign body.

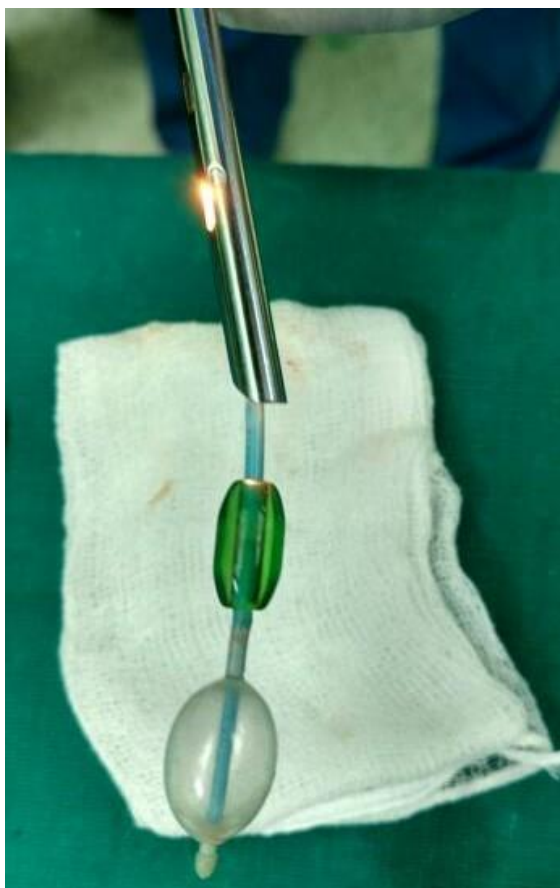Anaesthesia maintenance was done with intermittent boluses of inj propofol and muscle relaxation with boluses of inj succinylcholine upto a maximum of 3mg/kg. On completion of the procedure, once the bronchoscope is removed from the patients' airway, all the patients were given bag and mask ventilation with 100% oxygen.<sup>13</sup> Immediate post procedure, all patient received nebulization with bronchodilator with oxygen by face mask, patients are kept under observation in postoperative recovery area for stridor, respiratory distress or other signs of subglottic edema, bronchospasm. In our study 10(ten) patients required intubation during or post procedure. 08(eight) patients required postoperative ventilation and ICU care, mostly these patients also had significant stridor and desaturation in preoperative period also and they had long standing history of foreign body of >2 weeks.

Organic foreign bodies like groundnut/ peanut/ coconut soften because of the secretions and generally break during their removal. In these cases larger pieces were extracted with the help of bronchoscopy forceps and very small pieces are removed with through suctioning. In some cases only mucous plugs were removed and no foreign bodies were retrieved.

In cases with non-vegetative foreign bodies, enbloc removals were performed. Coin and disc batteries lodged in cricopharynx were removed with laryngoscopy and magill's forceps using only boluses of inj propofol. In cases with disc

batteries esophagoscopy was also performed to check and rule out any damage to the esophageal mucosa. Such cases did not require any bronchoscopy. Two patients presented with non-vegetative foreign bodies in trachea, one of which was an all-pin and other a pen-cap. The patient who had pen-cap as foreign body had cough, respiratory distress, stridor and had desaturation in both preoperative and intraoperative period, however he had an uneventful recovery.

One child had an elliptical shaped bead which was lodged in the right main bronchus. Because of the smooth surface of the bead it was difficult to catch and hold it with the telescopic forceps. Finally, through the opening of the bead, one small size Fogarty catheter was passed and once its balloon was distal to the bead, its balloon was inflated and the bead was removed along with the bronchoscope and the catheter (Fig. 4).



**Fig. 4**

In another case, safety pin was present in the esophagus which was not retrievable hence it was pushed down into the stomach and finally got removed with stools.

Most of the patients had laryngeal edema post procedure followed by hoarseness of voice. All patients in the recovery received a bronchodilator nebulization and was closely monitored for spasm, stridor, cough. Hypoxia followed by bradycardia is other main complication seen in children with chronic foreign bodies and undergoing bronchoscopy for which adequate monitoring and caution is required.<sup>14</sup>

## Conclusion

The safest method to remove a foreign body of the airway in pediatric case is by utilizing general anesthesia. Communication between the surgeon and anesthesiologist is essential for good outcome. The choice between maintenance of spontaneous and controlled ventilation is based on personal preference and does not affect the outcome of the procedure. Thorough and detailed clinical history, proper clinical assessment including chest X-ray, prompt and proper preoperative and perioperative anesthetic and surgical management ensure safe and successful recovery and outcome.

**Conflict of Interest:** None.

## References

1. Blumhagen JD, Wesenberg RL, Brooks JG, Cottan EK. Endotracheal foreign bodies: Difficulties in diagnosis. *Clin Paediatr* 1980;19:480-484.
2. Burton EM, Brick WG, Hall JD. Tracheobronchial foreign body aspiration in children. *South Med J* 1996;89:195-198.
3. Pinar K. The anaesthetic consideration of tracheobronchial foreign body aspiration in children. *J Thorac Dis* 2016;8(12):3803-3807.
4. Carluccio F, Romeo R. Inhaling foreign bodies: An epidemiological, clinical study of 92 cases. *Acta Otorhinolaryngol Ital* 1997;17(1):45-51.
5. Ashoore A, Baraka M, Kholania E. Foreign bodies in paediatric tracheobronchial tree. *Saudi Med J* 1987; 5: 481-86.
6. Siddiqui MA, Banjar AH, Al-Najjar SM. Frequency of tracheobronchial foreign body in children and adolescents. *Saudi Med J* 2000;21:368-371.
7. Weissberg D, Schwartz I. Foreign bodies in the tracheobronchial tree. *Chest* 1991;5:730-733.
8. Aravind Sehgal, Varinder Singh, Jagadish Chandra N, N. Mathur. Foreign body aspiration. *Indian paediatrics* 2002; 39: 1006-10.
9. Wiseman NE. The diagnosis of foreign body aspiration in childhood. *J Pediatr Surg* 1984;19:531-535.
10. D. Agarwal et al. Management of foreign bodies in tracheobronchial tree in paediatric age group- A brief review. *Indian J Anaesth* 2001;45(5):348-349.
11. Cummins CF, English IC, Loder RE, Parish C. General anaesthesia for bronchoscopy; an assessment of 1,310 cases. *Anesth Analg* 1958;37(6):336-337.
12. Morrison JD, Mirakhor RK, Craig HJL. Trachea and bronchi. In: *Anaesthesia for eye, ear, nose and throat surgery*. Newyork: Churchill Livingstone, 1985;69-72.
13. Kalyanappagol VT, Kulkarni NH, Bidri LH. Management of tracheobronchial foreign body aspirations in paediatric age group- A 10 year retrospective analysis. *Indian J Anaesth* 2007;51(1):20-23.
14. Geetha C, Rupa Kumari A, Deepraj Singh B. Incidence of the nature of foreign body in cases of foreign body bronchus- one year (2013) retrospective analysis and anaesthetic management. *J Evolution of Medical and Dental Sci* 2015;4(16):2739-2745.

**How to cite this article:** Sheetal K, Ghodke S. Foreign body aspirations in children: A retrospective analysis in a tertiary care paediatric hospital. *Indian J Clin Anaesth* 2019;6(1):30-33.