



Studies on Coccidia in Experimental Infection with *Eimeria* spp in Rose-Cobb Broiler Chicken

Samrawit Melkamu^{1*}, Mersha Chanie² and Mulat Asrat³

¹College of Veterinary Medicine, Samara University, ETHIOPIA

²Faculty of Veterinary Medicine, University of Gondar, ETHIOPIA

³School of Veterinary medicine, Wollo University, ETHIOPIA

*Corresponding author: M Samrawit: Email: amarech05@gmail.com

Received: 14 Jan., 2017

Revised: 20 Jan., 2017

Accepted: 27 Jan., 2017

ABSTRACT

The experimental completely randomized design was conducted on poultry coccidiosis of Rose-Cobb breed of one hundred broiler chicken from November 2015 to April 2016 in the Faculty of Veterinary Medicine, University of Gondar. The experimental animals (n=100) were randomly allocated into four equal groups, group one (G-I), group two (G-II), group three (G-III) and group four (G-IV) with 25 chickens in each group. The G-I, G-II, and G-III were treatments groups challenged by different *Eimeria* sporulated oocysts, while G-IV served as the control group. In this study, the infective dose of *E. tenella* (G-I), *E. acervulina* (G-II) and mixed *Eimeria* spp (G-III) was 2×10^4 sporulated *Eimeria* oocyst inoculated orally at three weeks of age in broiler chicken and subsequent alterations in different haematological constituents were evaluated at interval of 5, 7 and 9 day of post inoculation. The *Eimeria* species identified from the natural infected chickens were *E. tenella*, *E. acervulina*, *E. maxima* and *E. necatrix*. *E. tenella* was more pathogenic than *E. acervulina* and mixed *Eimeria* spp. Oocyst counts per gram of faeces in pure (*E. tenella* and *E. acervulina*) and mixed *Eimeria* spp. infection showed marked increase from the 5 to 8 DPI. Pure single infection of *E. acervulina* and *E. tenella* showed highest oocyst excretion on 6 DPI (62,395 oocyst/g of faeces) and 7 DPI (86,535 oocyst/g of faeces) respectively. Whereas mixed *Eimeria* spp. infection reached a maximum oocyst count of 51,270 oocyst/gm of faeces on 7 DPI.

Keywords: Broiler chicken, Coccidiosis, *Eimeria*

The main parasites found in poultry are caused by protozoa of the genus *Eimeria*, also known as coccidia, being responsible for serious economic losses, mainly due to diarrhoea and deaths in young poultry. The annual worldwide cost is estimated at about \$800 million. These estimates include the costs of prophylactic in feed medication for broilers and broiler breeders, alternative treatments if medication fails and losses due to mortality, morbidity, impaired growth rate, temporary reduction of egg production in layers and poor feed conversion of chickens that survive outbreaks (Asadi *et al.*, 2015). Poultry coccidiosis is prevalent in various parts of Ethiopia and affects mostly young growing birds (Mersha *et al.*, 2009). The main constraints for development of commercial poultry is development of disease conditions and management problem which can have a devastating

effect in intensive production. Commercial poultry consist of exotic breed selected for their capacity in producing eggs and meats, because of this selection these animals are more susceptible to disease than local traditional backyard poultry (CIRAD, 2005). *Eimeria* spp. are frequently described by the morphology of the oocyst, a thick walled zygote shed in faecal material by the infected host. Infective oocyst contains four sporocysts, which in turn contain two sporozoites (Saif *et al.*, 2003). Majority of *Eimeria* oocysts; *E. tenella*, *E. maxima*, *E. acervulina*, *E. hagani* and *E. brunetti* are ovoid while, *E. necatrix* is oblong-ovoid shape. *E. maxima* ($30.5 \times 20.7 \mu\text{m}$) is the largest and *E. mitis* ($15.6 \times 14.2 \mu\text{m}$) is the smallest as compared to other *Eimeria* species (Ahmed *et al.*, 2012). Oocyst size, shape, zone of intestine parasitized, nature of macroscopic lesions, minimum sporulation

time, minimum prepatent period and location of the parasite within the intestinal lesions and histopathological characteristics are the characteristics useful in species identification (Arabkhazaeli *et al.*, 2011). Diagnosis by faecal examination may lead to quite erroneous results. In some instances the major pathology is produced before oocysts are shed in the faeces and conversely the presence of large number of oocysts may not necessarily indicate a serious pathogenic condition. Diagnosis of coccidiosis in chicken is best accomplished by post mortem examination of representative number of birds. Size of oocysts, sites of infection, prepatent period and sporulation time are the morphological and biological features used for the diagnosis of coccidiosis. *E. maxima* can be easily identified based on oocyst size but *E. tenella* and *E. necatrix* produce confused lesions (Hadipour *et al.*, 2011). Therefore, this study was carried out to identify and diagnose parasitological effect of *Eimeria* spp. in broiler chicken.

MATERIALS AND METHODS

Study area

The experimental study was conducted in the Faculty of Veterinary Medicine at the premises of Tewodrose Campus, University of Gondar. The area is found in Amhara National Regional State, located in the north-western part of Ethiopia, (12.3° to 13.38° north latitudes and 35.5° to 38.3° east longitudes) (NMA, 2011). The research was conducted from November 2015 to April 2016.

Experimental animals and grouping

One hundred day-old Ross broiler breed chickens were purchased for this experiment from Alema, a private commercial broiler farm, Debre Zeit, Ethiopia. Unsexed day old chickens were randomly and equally allocated into four groups. All groups were maintained at the same management system. The chickens were reared for eight weeks in separate room under strict biosecurity measures and no vaccine was used during the study period. On the start of the experiment the birds were tagged with identification numbers on their wing and leg in each group.

Housing and management of experimental chickens

In this study, day-old chickens were kept with floor housing system. The house, feeder, water utensils were thoroughly cleaned, disinfected prior to stocking of chickens. The utensils were also cleaned daily to avoid reinfection and contamination. Thus, the chickens were reared under strict coccidia free conditions through repeated cleaning and disinfection. Chickens were fed ad libitum on a commercial broiler starter, grower and finisher diet based on their ages throughout the period of the experiment. Continuous heating program with 120 watt bulbs were suspended at head height of the birds. The amount of temperature present in the house was measured and recorded by thermometer and the heat released from brooder was adjusted based on the age of chickens from suspended height. The temperature was maintained at 29-31°C for the first week and was reduced by 1-3°C on weekly basis. Bio-safety of chickens was maintained in study area through fenced farm, protected against wild animals and using footbath. The experimental house had gate and there were special store for feed, disinfectant, personal protective equipment's and closing for the researchers and assistance. The current experiment was conducted with the approval of university of Gondar ethical review board. The experiment was conducted based on the international guidelines of animal experimentation and handling where they were fed ad libitum. The board approved the protocol to be done. Attached here with is the clearance copy.

Experimental design and inoculation of sporulated oocysts

The experimental design used for this research was completely randomized design. The experimental animals (n=100) were randomly allocated into four equal groups: group one (G-I), group two (G-II), group three (G-III) and group four (G-IV) with 25 chickens in each group. The G-I, G-II, and G-III were treatment groups challenged by different *Eimeria* sporulated oocysts, while G-IV served as the control group. All chickens were maintained until the 10th day of age the experiment with a ration containing anticoccidial additives following the recommended producer. After the 10th days of age, the chickens were fed on a ration without anticoccidial additives until the end of experiment. Ad libitum provision of feed and water were maintained. Faecal material from each group was

examined at 10th and 21th days of age before the infection, to ensure that the chickens were free from coccidia or other parasitic diseases. Additionally, blood examination was conducted for the detection of pathogenic bacterial agents. One bird from each group was sacrificed and examined to confirm the absence of any parasitic stage of *Eimeria* species and other pathological lesions at 21th day of age.

The treatment groups of chickens (G-I, G-II, G-III) were infected artificially infected with sporulated *Eimeria* oocysts at the age of three weeks as described by You (2014). They were infected orally with infective dose of 2×10^4 sporulated oocysts of *E. tenella*, *E. acervulina* and field isolated mixed *Eimeria* oocysts. The G-I chickens were infected with *E. tenella*, G-II with *E. acervulina* and G-III with mixed *Eimeria* spp. (*E. acervulina*, *E. tenella*, *E. necatrix* and *E. maxima*). G-IV was remained as uninfected control groups.

Preparation of infective *Eimeria* species for the experiment

Pure culture *E. tenella*, *E. acervulina* and mixed identified *Eimeria* species were used for this experiment. The pure cultures of *E. tenella* and *E. acervulina* were acquired from India. The mixed *Eimeria* species were identified from the naturally infected chickens. For identification of these mixed species, oocysts were collected from a total of 22 local and koeykoey breed chickens of different sex and ages of clinically coccidiosis suspected chickens were purchased from Gondar town and donated from Kombolcha poultry research and multiplication centre. The chickens were sacrificed in the laboratory at post-mortem room by cervical dislocation using the technique described by Zander (1999). The gastrointestinal tract was grossly examined carefully. Intestinal contents from the respective sections of intestine with lesions were collected. The floatation technique using sodium chloride solution was applied to harvest oocysts (Bowman, 2003). The harvested *Eimeria* oocysts were identified by a combination of oocyst size, location in the gut and appearance of the lesions (Conway and McKenzie, 2007; McDougald and Fitz-Coy, 2008). The different species of *Eimeria* were identified according to the length, width and shape index of the individual oocyst after measuring 50 oocysts in each positive sample using a calibrated ocular microscope (McDougald, 2003).

The identified *Eimeria* spp. oocysts were spread out in shallow Petri dish containing 2.5% potassium dichromate ($K_2Cr_2O_7$) solution and incubated with a temperature 29°C, with adequate oxygen and humidity to allowed sporulation as describe by Conway and McKenzie (2007). The sporulation of the oocyst was confirmed by taking a drop of the mixture starting from the second day of incubation and examined for the presence of sporocysts under the microscope. The sporulated oocysts were collected and preserved in 2.5% $K_2Cr_2O_7$ and stored at 4°C. The sporulated oocysts were counted using the McMaster method (Holdsworth *et al.*, 2004).

Observation of prepatent period and clinical signs

The animals from each experimental group were monitored closely for possible observable clinical signs throughout the course of the experiment. The predominant clinical signs were recorded in each infected groups, daily faecal samples were collected starting on the 3 DPI from each group of the experimental chickens. Detect the presence of oocysts using a simple floatation test to determine the prepatent period of the infection in each group. Body weight of the chickens was measured on 7DPI using a weighing balance (made in China by Hana) in the morning prior to feeding.

Oocyst Count

The faeces from each group were collected twice a day starting from day 3 to 11 DPI to count oocyst per gram of faeces. Excreted oocysts were counted using a McMaster counting chamber method. The oocysts counts were expressed as the mean number oocysts per gram of faeces (Holdsworth *et al.*, 2004).

RESULTS

An experimental trial for *Eimeria* spp. infection in broiler chickens was conducted to evaluate the clinical sign, *Eimeria* spp. identification and parasitological changes.

Eimeria species identified from the natural infection

One of the groups (group three) in this experiment was inoculated with *Eimeria* spp. identified from the field. The *Eimeria* species identified through calibrated ocular

microscope from the natural infected chickens were *E. tenella*, *E. acervulina*, *E. maxima* and *E. necatrix* (Fig. 1). The un sporulated oocysts contained zygote filling the entire space (Fig. 2) *E. tenella* was the most abundant species followed by *E. acervulina*. Culture of oocysts was made to sporulated in 2.5% $K_2Cr_2O_7$ solution maintained at 29°C in the incubator and the sporulation time was varies from two to three days. The morphological characteristics of the oocysts of *Eimeria* species that was used in the identification the different species were summarized in (Table 1).

Table 1: The morphological identification of mixed infection of *Eimeria* species oocyst in natural infected chickens.

Site of infection	Mean oocyst length (µm)	Mean oocyst width (µm)	Shape index	Identified <i>Eimeria</i> spp.
Caecum	21.31	17.92	1.19	<i>E. tenella</i>
Duodenum	18.23	14.02	1.3	<i>E. acervulina</i>
Jejunum and ileum	29.80	23.69	1.24	<i>E. maxima</i>
Jejunum and ileum	20.02	16.75	1.2	<i>E. necatrix</i>

Note: µm=micro meter

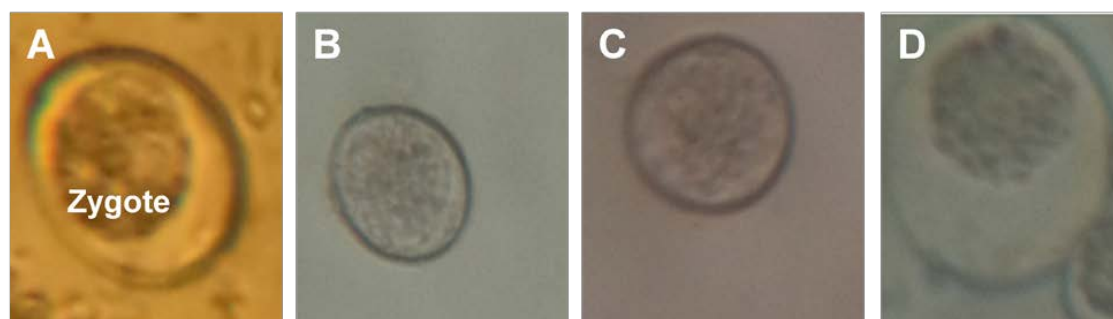


Fig. 1: Un- sporulated *Eimeria* oocyst of *E. tenella* (A), *E. acervulina* (B), *E. necatrix* (C) and *E. maxima*

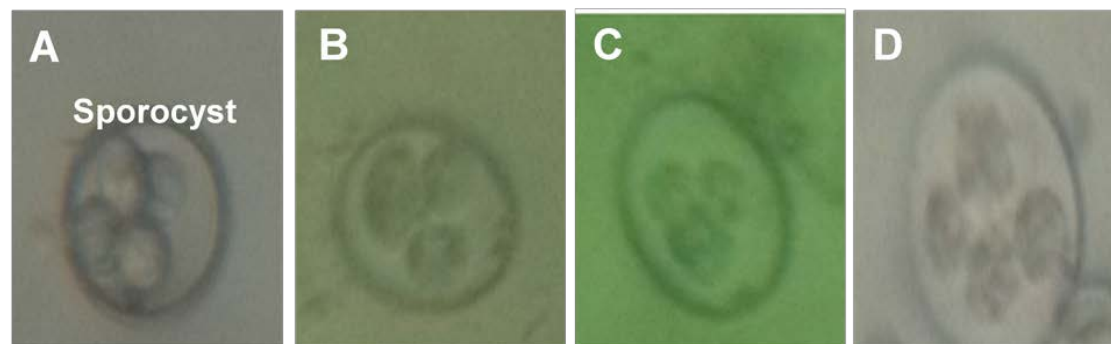


Fig. 2: Sporulated *Eimeria* oocyst. *E. tenella* (A), *E. acervulina* (B), *E. necatrix* (C) and *E. maxima* (D) (40X)



Fig. 3: Measured length and width of sporulated *Eimeria* spp. *E. tenella* (A), *E. acervulina* (B) and *E. maxima* (C) using calibrated ocular microscope (40X)

Table 2: Illustration of prepatent period, body weight and clinical signs of experimentally infected chickens

Group	Species	Prepatent period	Bodyweight (Mean±SD)	Clinical sings
G-I	<i>E. tenella</i>	5 days	820±208.36*	Weakness, inappetance, dropping of wing and whitish diarrhoea showed on 4 DPI. By the 5 DPI the faeces became bloody and more number of <i>E. tenella</i> oocysts were presented in the faeces. Severe depression, decreased body weight, straining, somnolence, pale wattle and combe. Mortality occurred from 7 to 9DPI.
G-II	<i>E. acervulina</i>	4 days	884±117.84*	Whitish and bloody diarrhoea, wing drop, depression, muffled feathers, closed eyes and inappetance, pale wattle and combe, decrease body weight, straining, mortality occurs from 7 to 9 DPI .
G-III	Mixed <i>Eimeria</i> spp.	5 days	932±139.47*	Decrease body weight, watery, whitish and bloody diarrhoea, wing drop and inappetance, mortality occurs from 7 to 10 DPI.
G-IV	—	—	1065±198.5*	No clinical signs of the disease

Note: Mean ± SD= mean plus or minus standard deviation, *= Non statistical difference between groups.

Prepatent period and clinical signs in the experimentally infected chickens

The prepatent period, mean body weight and the clinical sings observed in the different experimental groups were summarized in (Table 2). The clinical signs manifested mainly were loss of weight, severe anaemia and bloody watery diarrhoea. In *E. tenella* infected groups 6 chickens, in *E. acervulina* infected group 4 chickens and 3 chickens in mixed *Eimeria* spp. infection were died from 7 to 9 DPI. Morbidity in all three infected groups were 100%. However, no other gastrointestinal parasites were detected by sedimentation and floatation techniques and normal bacterial colony were appreciated in appropriately prepared bacterial growth media.

The body weight of the experimental group were recorded at 7 DPI. There was no statistical difference in the average body weight obtained at 7DPI between the experimental infected and control group. Although, G-IV chickens demonstrated the higher body weight (Table 2).

Oocyst count per gram of faeces

In the present study, oocysts count in faeces demonstrated different kinetics shedding rate in different infected groups. Oocyst counts per gram of faeces in pure (*E. tenella* and *E. acervulina*) and mixed *Eimeria* spp. infection showed marked increase from the 5 to 8DPI. Pure single infection of *E. acervulina* and *E. tenella* showed highest oocyst

excretion on 6 DPI (62,395 oocyst/g of faeces) and 7 DPI (86,535 oocyst/g of faeces) respectively. Whereas mixed *Eimeria* spp. infection reached a maximum oocyst count of 51, 270 oocyst/gm of faeces on 7DPI. After the oocyst count reaches its highest level it was gradually reduced and only a few number were seen on 11DPI (Fig. 6).

DISCUSSION

In the present experiment, there were successful developments of infection with *Eimeria* species. The disease coccidiosis observed in all three experimental groups were discussed with regard to sporulation of oocysts, identification of *Eimeria* spp., prepatent period, clinical signs, body weight, oocyst count examination. In the present study, oocyst length, width, shape index and shape, were an indicative of the *Eimeria* species identification. This finding is in agreement with Al-Quraishy (2009), Amer *et al.* (2010) who reported as the length and width of *E. tenella* inµm (19.5-26 and 16.5-22.8); *E. acervulina* (17.7-20.2 and 13.7-16.3) and *E. maxima* (21.5-42.5 and 16.5-29.8) to identify *Eimeria* spp. In the present findings, most of the *Eimeria* oocyst shape were ovoid. Similar findings are also reported by Ahmed *et al.* (2012) who reported that *E. tenella*, *E. acervulina*, *E. maxima* and *E. necatrix* oocyst were ovoid in shape.

In this study, four *Eimeria* species from intensive and extensive reared chickens collected sample were identified




Fig. 4: Clinical signs of *E. tenella* infected group. Day old chicken (A), control chicken (B), bloody diarrhoea(C).

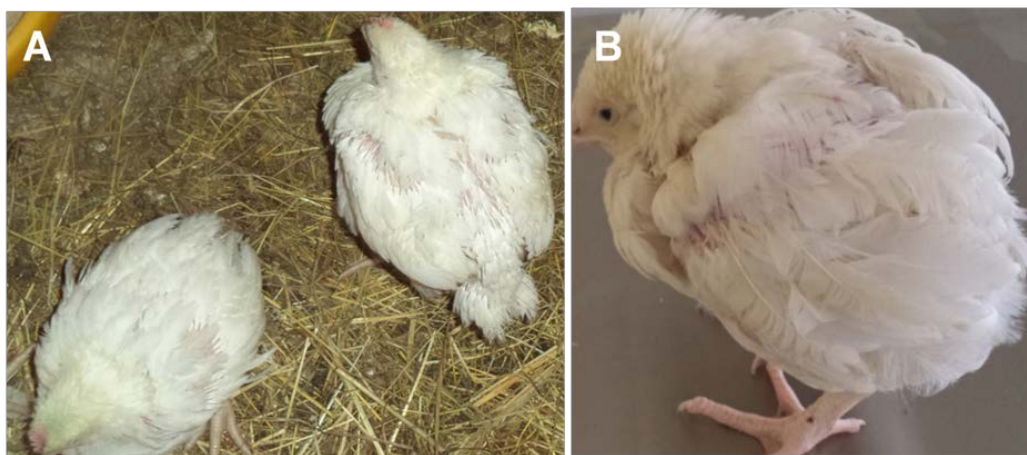


Fig. 5: Clinical sign of *E. acervulina* infected group (A) and mixed *Eimeria* spp. infected groups (B)

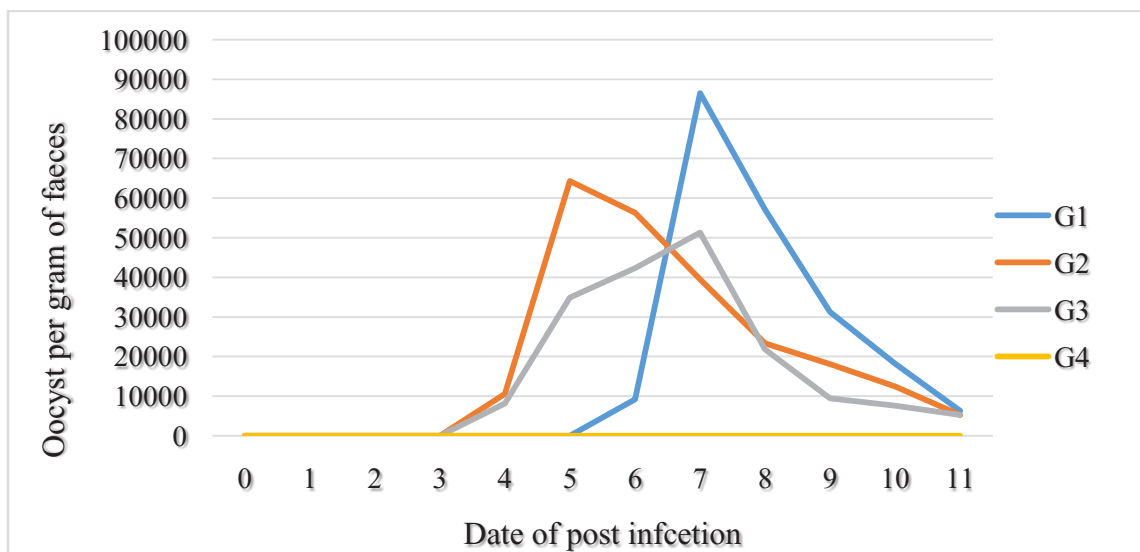


Fig. 6: Oocysts shedding in chickens infected in G-I, G-II, G-III and G-IV

mainly as mixed infection of *E.tenella*, *E. acervulina*, *E. maxima* and *E. necatrix* but the former *Eimeria* spp. occurs more pre dominantly. Similar findings with earlier reports of Abadi *et al.* (2012), Bereket and Abdu (2014) who stated that in cases of mixed infections of *Eimeria* spp. predominant cases were due to *E. tenella* together with any of the four species (*E. brunetti*, *E. necatrix*, *E. acervulina* and rarely with *E. maxima*). On contrary, Jatau *et al.* (2012) who reported that as mixed infection of *Eimeria* species in free range indigenous and intensively managed exotic chickens, *E. maxima* is the predominant species.

The prepatent period observed during the present study for *E. tenella*, *E. acervulina* and mixed *Eimeria* spp. varied from 4 to 5 DPI. Similar result is described by Ahmed *et al.* (2012) who stated that the prepatent period for *E.tenella*, *E. acervulina*, *E. mitis* and *E. necatrix* varied from 4 to 7 DPI. In the present study, the lower prepatency period could be due to variation of species.

In the current study, the most common clinical findings of chickens infected with *E. tenella*, *E. acervulina* and mixed *Eimeria* spp. infection were weakness, inappetance, bloody diarrhoea, pallor of the comb and wattles and mortality among the infected chickens in group one than the others due to the excessive loss of blood. Similar findings are also reported by Awais *et al.* (2012). The clinical signs manifested in the infected groups could be due to tissue destruction from the release of the merozoites and oocysts from the mucosal surface during the last generations of merogony and throughout gametogony much of the mucosal epithelium was sloughed off and compromised nutrient absorption. The agents that cause coccidiosis are intracellular parasites that are multiplied in the intestine, causing tissue destruction and harming digestion and absorption of food, resulting in clinical watery or bloody diarrhoea Vieira (2004).

Significant statistical differences are not observed between the average weight gain of chickens from G-I, G-II and G-III when compared with G-IV chickens. However, G-IV recorded higher average body weight. These values agreed with Fagner (2014) who described that there is no significant difference in weight gain but always lower average for the infected group. The non-significant decrease of body weight observed could be the short period of experimental infection. On the contrary,

Danladi *et al.* (2014) and Arabkhazaeli *et al.* (2011) opined that by using a single dose of 2×10^4 oocysts of *E. acervulina*, *E. tenella* and 3×10^5 mixed isolated *Eimeria* species showed a significant decrease in weight gained compared to the control group. This difference in results might be associated to several factors such as genetics of the birds, route of administration, amount of infective oocysts administered and strain of *Eimeria* spp.

In the present study, oocyst count was markedly increased from 5 to 8 DPI. Similar observations were reported by You (2014) and Luciana da *et al.* (2014) who stated that mean oocyst counts of *E. tenella*, *E. maxima* and *E. acervulina* species increased more quickly on the 5 to 8 DPI. Among the infected groups, *E. tenella* infected group showed highest mean oocyst per gram of faces on 7 DPI. Similar findings are recorded by earlier workers Zulpo *et al.* (2007) who reported that *E. tenella* oocyst per gram of faces on 7 DPI is higher than that of *E. acervulina*. However, the present study contradicts with earlier reports of You (2014) who reported that *E. acervulina* infected chickens showed higher oocyst shedding than *E. tenella* and *E. maxima*. The highest number of oocyst per gram of faces in *E. tenella* infected group in the present study could be due to the peak multiplication and more rapid excystation of *E. tenella* sporozoites when compared to *E. acervulina* and mixed *Eimeria* species.

REFERENCES

- Abadi, A., Araya, M. and Shahid, N. 2012. Prevalence and aetiology of poultry coccidiosis and associated risk factors in white leghorn grower chickens at Kombolcha poultry farm, Ethiopia. *J. World's Poult. Res.*, **2**(3): 54-59.
- Al-Quraishy, S., Abdel-Baki, A. and Dkhil, M. 2009. *Eimeria tenella* infection among broiler chicks Gallus domesticus in Riyadh city, Saudi Arabia. *J. King Saud Univ. Sci.*, **21**: 191-193.
- Amer, M.M., Awaad, M.H., Rabab, M., El- Khateeb, N.M., Abu-Elezz, A., Sherein-Said, M.M. and Kutkat, M.A. 2010. Isolation and identification of *Eimeria* from field coccidiosis in chickens. *J. Anim. Sci.*, **6**(10): 1107-1114.
- Arabkhazaeli, F., Nabian, S., Modirsaneii, M., Mansoori, B. and Rahbari, S. 2011. Bio-pathologic characterization of three mixed poultry *Eimeria* spp. isolates. *Iranian J. Parasitol.*, **6**(4): 23-32.
- Asadi, I.H., Asadi, I.M., Youssefi, M.R. and Abouhosseini, T.M. 2015. Growth performance parameters in chicken experimental coccidiosis treated with Diclazuril and

- Clopidol: The need for assessing new anticoccidial resources. *Iranian J. Vet. Med.*, **9**(3): 189-194.
- Awais, M.M., Akhtar, Z., Muhammad, I.F. and Anwar, M. I. 2012: Seasonal prevalence of coccidiosis in industrial broiler chickens in Faisalabad, Punjab, Pakistan. *Trop. Anim. Hlth. Prod.*, **44**: 323-8.
- Bereket, M and Abdu, A. 2014. Epidemiological study on poultry coccidiosis, prevalence, specious identification and post mortem lesion in grower chicken in Kombolcha, North eastern Ethiopia. *J. Vet. Med. Anim. Hlth.*, **7**(1): 1-8.
- Bowman, D. 2003. Parasitology for veterinarians. 8th ed. U.S.A. Saunders. Broiler chicks *Gallus domesticus* in Riyadh city, Saudi Arabia. *J. King Saud.*, **9**(1): 12-19.
- CIRAD 2005. Investigation of poultry disease in Ethiopia. Mission report Franch Agricultural Research for international development (CRAD) 29th June-7th July, 2005, pp. 6-14.
- Conway, D.P. and McKenzie, M.E. 2007. Poultry coccidiosis, diagnostic and testing procedures. 3rd ed. Ames, Iowa. Blackwell publishing, IA, USA. pp. 37-40.
- Danladi, J.I., Augustine, N.O., Mathew, T., Ahmad, M.T., Muhammed, B. and Ibrahim, W.M. 2014. Response of two breeds of broiler chicks to experimental infection with low dose of *E. tenella* sporulated oocysts. *Turk J. Vet. Anim. Sci.*, **38**: 398-404.
- Fagner L. C. 2014. Metabolic alterations in broiler chickens experimentally infected with sporulated oocysts of *Eimeria maxima*. *Braz. J. Vet. Parasitol.*, **23**(3): 309-31.
- Hadipour, M.M., Olyaie, A., Naderi, M., Azad, F. and Nekouie, O. 2011. Prevalence of *Eimeria* species in scavenging native chickens of Shiraz, Iran. *African J. Mic. Res.*, **5**(20): 3296-3299.
- Holdsworth, P.A., Conway, D.P., McKenzie, M.E., Dayton, A.D., Chapman, H.D., Mathis, G.F., Skinner, J.T., Mundt, H.C. and Williams, R.B. 2004. World association for advancement of veterinary parasitology guidelines for evaluating the efficacy of anticoccidial drugs in chickens and turkeys. *J. Vet. Parasitol.*, **121**: 189-212.
- Jatau, D.I., Sulaiman, N.H., Musa, W.I., Awal, A.I., Okubanjo, O.O., Isah, I. and Magaji, Y. 2012. Prevalence of coccidia infection and preponderance *Eimeria* species in free range indigenous and intensively managed exotic chickens during hot- wet season, in Zaria, Nigeria. *Asian J. Poult. Sci.*, **4**: 213.
- Luciana da S. B., Elder, N.P., Augusta, A.S., Vinicius, B.C. and Fagner, L.C. 2014. Experimental Infection with Sporulated Oocysts of *Eimeria maxima* in broiler chicken. *J. Vet. Med.*, **7**: 273.
- McDougald, L.R. 2003. Coccidiosis. In: Saif, M. (ed). Diseases of poultry. Iowa State Press, Blackwell Publishing Company, USA, 11th ed. pp. 974-991.
- McDougald, L.R. and Fitz-Coy, S.H. 2008. Protozoal infection, In: Saif, Y.M. (ed.). Disease of poultry. 12th ed. Blackwell Publishing. Ames, IA, USA. pp. 1068-1080.
- Mersha, C., Tamiru, N. and Samuel, B. 2009. Occurrence of concurrent infectious diseases in broiler chickens is a threat to commercial poultry farms in Central Ethiopia. *Trop. Anim. Hlth. Prod.*, **41**: 1309-1317.
- NMA, 2011. Annual climatically bulletin for the year 2011. National Metrological Agency of Ethiopia.
- Saif, Y., Barnes, A., Glisson, F., McDougald, L. and Swayne, D. 2003. Diseases of poultry 12th ed, Iowa state press, USA.
- Vieira, 2004. Bioestatística Tropicós Avancados, Elsevier, Rio de Janeiro, Brazil, 2nd ed.
- You, M.J. 2014. The comparative analysis of infection pattern and oocyst output in young broiler chicken, *E. tenella*, *E. maxima* and *E. acervulina*. *Vet. World*, **7**(7): 542-547.
- Zander, D.V. 1999. Principles of disease prevention, diagnosis and Control. In: Hofstad, M.S., Calnek, B.W., Helmboldt, C.F., Reid, W. M. and Yoder, J.H. (ed.). Diseases of poultry, 7th ed. USA, Iowa State University Press/Ames, Iowa, pp. 3-48.
- Zulpo, D., Dauton, L., Jaidson, P., Leandro, M., Elaine, L., Marcos, R.O., Ivens, G.G., Selwyn, A.H., Jose da Silva, G.J. and Joao, L.G. 2007. Pathogenicity and histopathological observations of commercial broiler chicks experimentally infected with isolates of *E. tenella*, *E. acervulina* and *E. maxima*. Londrina, *Semina: Ciências Agrarias*, **28**(1): 97-104.