

Cross sectional analysis of positional and numerical variations of mental foramina in dry human mandibles

Urvi H. Dave¹, Sunita Gupta², Rajesh Astik^{3,*}

¹Tutor, ^{2,3}Professor and Head, Dept. of Anatomy, ¹GCS Medical College, Gujarat University, Ahmedabad, Gujarat, ²AMC Met Medical College, Gujarat University, Ahmedabad, Gujarat, ³GMERS Medical College, Hemchandracharya Noth, Gujarat University, Ahmedabad, Gujarat, India

***Corresponding Author: Rajesh Astik**

Email: astikrajesh@yahoo.co.in

Received: 10th September, 2018

Accepted: 15th October, 2018

Abstract

Introduction: During lower jaw surgeries, mental nerve block is given at mental foramen level. However, mental foramen is prone for variations in its location and number, which could lead to iatrogenic injuries to neurovascular structures in this region.

Aim and Objective: The aim of this study is to provide precise information of variations of site and number of mental foramen for helping dental surgeons to avoid injuries to mental nerve and vessels. Hence, the objective of the study is to analyze changes in site and number of mental foramen in the form of accessory foramina osteologically in Gujarat's population.

Materials and Methods: Three hundred dry mandibles of unknown sexes, and bearing all teeth or intact alveolar margin were included in the study. In 37.33% of mandibular sides, mental foramens were found between 2nd premolar and the 1st molar teeth. Numerical variations in the form of accessory foramina were found in 16.66% mandibles, more on the left side, showing statistically significant difference in laterality distribution.

Conclusion: Iatrogenic injuries of mental neurovascular structures could better be avoided with precise idea of variations in site and numbers of mental foramen, which may ease the work of dental surgeon.

Keywords: Dry mandibles, Mental foramen, Anaesthesia, Anatomical variation.

Introduction

Division of inferior alveolar nerve into incisive and mental branches occurs between lower premolar teeth or at the 2nd molar tooth level, which is the usual site of the mental foramen. After origin, mental neurovascular structures ascend in posterior direction to come out via mental foramen to supply skin of lower face. However, site and numbers of mental foramen are not constant, and may vary widely amongst different population groups. If more than one mental foramen found, the smaller foramina are known as accessory mental foramina (AMF).^{1,2} The altered position of mental foramen or presence of accessory mental foramina could result in failed mental nerve block. Mental neurovascular structures are commonly injured during oral surgical procedures such as dental injections, root canal treatment, insertion of dental implants, and extraction of impacted lower teeth, periodontal flap surgery, and treatment of traumatic injuries of oral cavity and can cause sensory damage in the area of its distribution.³

The altered location of mental foramen and frequency of occurrence of AMF were documented, however, it varied amongst different ethnic groups, and fewer literatures available regarding relative topographical situation of AMF to mental foramen. Since detailed anatomical data of site and numerical variations of mental foramen in different population is needed for successful administration of mental nerve block, the objective of the present study is to analyze changes in site and number of mental foramen in the form of accessory foramina osteologically in Gujarat's population.

Materials and Methods

In this cross sectional study we include three hundred dry mandibles of unknown sexes, and bearing all teeth or intact alveolar margin. The source of the study material is anatomy departments of different medical colleges of the Gujarat. The position of mental foramen could not be determined correctly in edentulous mandible, so exclusion criteria were set at mandibles without teeth or eroded alveolar margin. The bones were numbered serially. Topographical situation of mental foramen was noted and classified into six levels (Fig. 1).⁴ The presence of AMF if found, whether on left or right side of the body, anterior/posterior or above/below the mental foramen, was noted (Table 1). The significance of laterality distribution was evaluated by Chi-square test with significance for the analysis was set at the level of $p < 0.05$. Position of AMF was divided into four broad groups (Table 2).

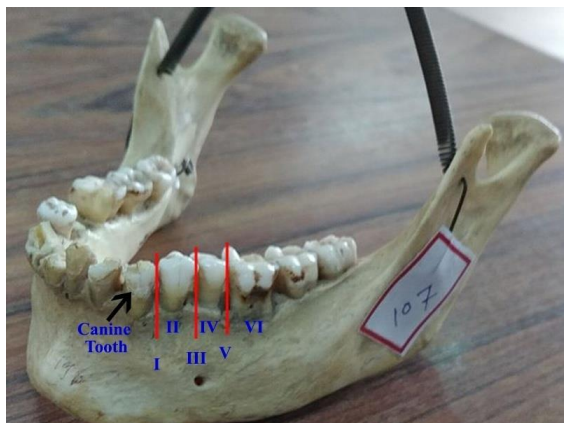


Fig. 1: Position of mental foramen in relation to lower teeth. Level I: Mental foramen lies between canine and 1st premolar; II: at 1st premolar level. III: between 1st and 2nd premolars. IV: at 2nd premolar level. V: between 2nd premolar and 1st molar VI: at 1st molar level

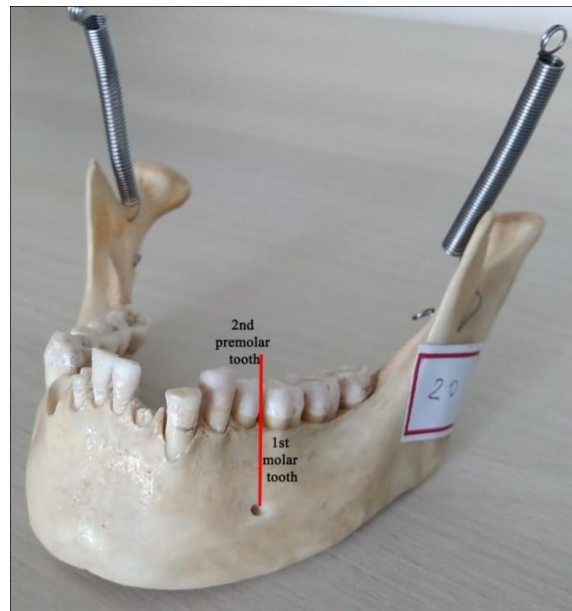


Fig. 2: Mental foramen lies at level V

Result

Out of 600 mandibular sides, 224 mandibular sides (37.33%) had mental foramens at the level V (Fig. 2). Position at the level I was found in 30 mandibular sides (5%); at the level II in 52 mandibular sides (8.66%); at the level III in 176 mandibular sides (29.33%); at the level IV in 106 mandibular sides (17.66%); and at the level VI in 12 mandibular sides studied (2%). Not a single side of the mandibular body where mental foramen was absent.

We found AMFin 50 (16.66%) mandibles studied (Table 1). Amongst them, four mandibles (1.33%) had 2 AMF and one mandible (0.33%) had 3 AMF. We found 6 mental foramina in one mandible (0.33%); out of the six foramina, five smaller foramina were given the name as AMF (Fig. 3). p-value for laterality distribution was 0.039 showing laterality distribution of AMF was significant statistically.

Table 1: Frequency of occurrence of AMF

Accessory Mental Foramina	Number of mandible	(%)
On Left side	42	14%
On Right side	7	2.33%
Bilateral	1	0.33%
Absent	250	83.33%

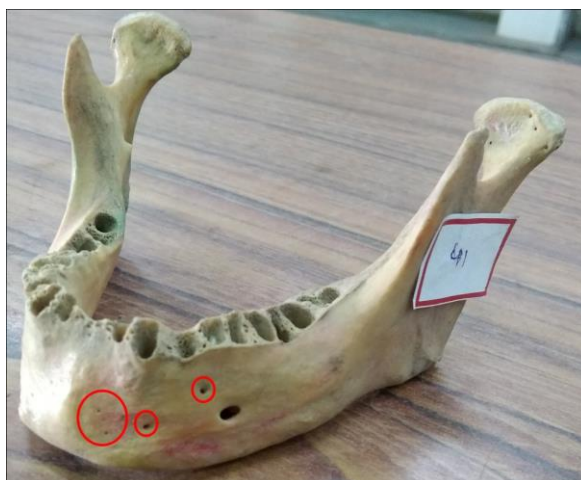

Fig. 3: Five accessory mental foramina (circled)

Table 2: Position of accessory mental foramen as compared to mental foramen

Position of AMF in relation to mental foramen	Number of AMF	%
Antero-inferior(Fig.3)	20	3.33%
Antero- superior (Fig. 4)	14	2.33%
Postero-superior (Fig. 5)	10	1.44%
Postero-inferior(Fig.5)	6	1.00%

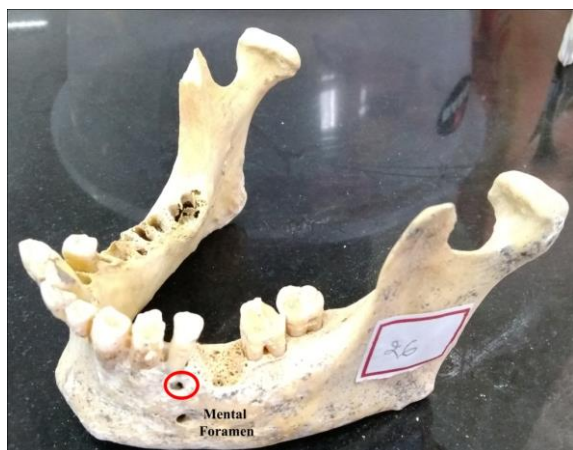

Fig. 4: Accessory mental foramen (circled) found antero-superior to main mental foramen near the canine root

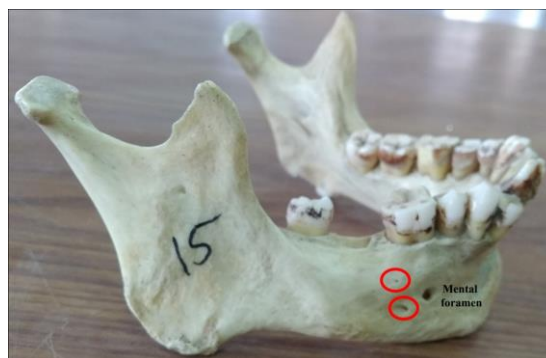

Fig. 5: Two accessory mental foramina (circled) found postero-superior and postero-inferior to main mental foramen

Discussion

Azaz et al. stated that mental foramen lie commonly between premolar teeth; however, it may lie posterior to the 2nd premolar tooth, or rarely at 1st premolar tooth level in different groups of population (Table 3).⁵

Table 3: Variations in position of the mental foramen in different population

S.No	Population	Position					
		I	II	III	IV	V	VI
1	North Indians ⁶	0	2.08	17.71	68.75	11.46	0
2	Asian Indians ⁷	0	5.80	75.36	18.84	0	0
3	North American ⁴	0	3.5	23.00	49.4	24.1	0
4	South Indian ⁸	0	4.4	16.67	52.22	27.78	0
5	Maharashtra, India ⁹	0	2	11	46.5	27.5	2
6	Present study	5	8.66	29.33	17.66	37.33	2

In the present study, out of 300 mandibles, the highest numbers of mental foramina found were at the level V in 37.33% mandibles, followed by at the level III in 29.33%. However, in North Indian population, more mental foramina lie at the level IV.⁶ If local anaesthesia is infiltrated at level IV, nerve block would be not successful, so, level V should be considered as a potential alternative site for anaesthesia. Exact situation of mental foramen and its topographically altered position is crucial in various surgeries performed involving the mandible or else damage to nerves and vessels exiting from the mental foramen leads to paresthesia and bleeding.¹⁰ In embryonic life, mental foramen appears between canine and 1st molar teeth, and later it migrates towards ramus of the mandible. If this posterior migration failed, different positions of mental foramen result.¹¹

Appearance of AMF varies widely in different population (Table 4). Appearance of AMF on the left side is more common than on right side which is similar to the previous studies.^{6,8} Incidence of occurrence of mental foramina is showing significant laterality distribution (Table 1). Number of AMF varied widely in previous studies. Gershenson et al. found 2 AMF in 4 mandibles, 3 AMF in 1 mandible.¹² Katakami et al. reported 2 AMF in 1 mandible in radiological study on mandible.¹³ In the present study, 4 mandibles had 2 AMF, 1 mandible had 3 AMF. We found 5 AMF in one mandible, which is not reported hitherto. The maximum number of AMF found were two in number.^{14,15}

Table 4: Comparison of appearance of AMF

Study	Total mandibles studied	AMF found	
		No. of mandible	(%) Mandibles
Sawyer et al. ¹⁴	705	42	5.9
Gershenson ¹²	525	28	5.1
Katakami ¹³	150	16	10.6
Kasat PA et.al ⁹	100	3	1.5
Present study	300	50	16.66

The most common position of AMF found (3.33%) in this study was antero-inferior to mental foramen. (Table 2). Position of AMF in relation to mental foramen in dry mandible was reported sparsely. Position of accessory mental foramina above mental foramen at any teeth level found to be detrimental as it leads to abnormal paraesthesia or uncontrolled bleeding during tooth extraction or root canal treatment.

Mental nerve after exiting from mental foramen divides into terminal branches and supply skin of lower lip, and mucosa of the lip and adjacent gum. If mental nerve gives branches prior to its exit from mental foramen, or presence of accessory mental nerve which arises from inferior alveolar nerve in mandibular canal, then these nerves come out of additional foramina on the mandibular surface called as AMF. The formation of additional foramina is due to the nerve passing through them, could be reason of occurrence of numerous variations in site and number of mental foramen.¹⁶

Conclusion

The importance of knowing racial variations in appearance of AMF; their preference for distribution on right or left side of the body of the mandible; and superior or inferior to mental foramen is greatly influencing mental nerve blocks during surgeries planned on mandible. Occurrence of multiple accessory mental foramina could be accidental cause of failed mental nerve block and alarming hemorrhage intra-operatively. So, precise information in this study may ease the work of dental surgeons. The mandibles studied were of unknown sex, so position of mental foramen and incidence of AMF could not be analyzed in relation to sex.

Conflict of Interest: None.

References

- Williams PL, Bannister LH, Berry MM (1195) Gray's Anatomy (38thedn) Churchill Livingstone Publications: 576-577.
- Sinnatamby CS: Last's Anatomy: Regional and Applied. 10th Edn; Churchill Livingstone, Edinburgh, 1999;pp 492.
- Tebo HG, Telford IR. An analysis of the relative position of the mental foramina. *Anat Rec* 1950;106:254-255.
- Tebo HG, Telford IR. An analysis of the variations in position of the mental foramen. *Anat Rec* 1950;107(1):61-66.
- Azaz B, Lustmann J. Anatomical configurations in dry mandibles. *Br J Oral Surg* 1973;11(1):1-9.
- Singh R, Srivastav AK. Study of position, shape, size and incidence of mental foramen and accessory mental foramen in

- Indian adult human skulls. *Int J Morphol* 2010;28(4):1141-1146.
- Shankland WE 2nd. The position of mental foramen: in Asian Indians. *J Oral Implantol* 1994;20(2):118-123.
- Udhaya K, Saraladevi KV, Sridhar J. The morphometric analysis of the mental foramen in adult dry human mandibles. *J Clin Diagn Res* 2013;7(8):1547-1551.
- Kasat PA, Muthiyar GG, Bhuiyan PS. A morphological study of mental foramen of the dry adult human mandibles. *Int J Anat Res* 2016;4(3):2552-2560.
- Phillips JL, Weller RN, Kulid JC. The mental foramen: Part I. Size, orientation and positional relationship to the mandibular second premolar. *J Endod* 1990;16(5):221-223.
- Kjaer I: Formation and early prenatal location of the human mental foramen. *Scand J Dent Res* 1989;97(1):1-7.
- Gershenson A, Nathan H, Luchansky E. Mental foramen and mental nerve: changes with age. *Acta Anat (Basel)* 1986;126(1):21-28.
- Katakami K, Mishima A, Shiozaki K, Shimoda S, Hamada Y, Kobayashi K. Characteristics of accessory mental foramina observed on limited cone-beam computed tomography images. *J Endod* 2008;34(12):1441-1445.
- Sawyer DR, Kiely ML, Pyle MA. The frequency of accessory mental foramina in four ethnic groups. *Arch Oral Biol* 1998;43(5):417-420.
- Naitoh M, Hiraiwa Y, Aimiya H, Gotoh K, Arijji E. Accessory mental foramen assessment using cone-beam computed tomography. *Oral Surg Oral Med Oral Pathol Oral Radiol Endod* 2009;107:289-294.
- Hu KS, Yun HS, Hur MS, Kwon HJ, Abe S, Kim HJ. Branching patterns and intraosseous course of the mental nerve. *J Oral Maxillofac Surg* 2007;65(11):2288-2294.

How to cite this article: Dave UH, Gupta S, Astik R. Cross sectional analysis of positional and numerical variations of mental foramina in dry human mandibles. *Indian J Clin Anat Physiol* 2019;6(1):81-84.