

## Incidence of structural chromosomal anomalies in patients of acute myeloid leukemia in North Indians

Rakesh Kumar Verma<sup>1,\*</sup>, Sangharsh Rao<sup>2</sup>, Navneet Kumar<sup>3</sup>, U.S. Singh<sup>4</sup>, Archana Kumar<sup>5</sup>

<sup>1</sup>Associate Professor, <sup>2</sup>Ex-PG Resident, <sup>3</sup>Professor and Head, <sup>4,5</sup>Professor, <sup>1-3</sup>Dept. of Anatomy, <sup>4</sup>Dept. of Pathology, <sup>5</sup>Dept. of Paediatrics, King George's Medical University, Lucknow, Uttar Pradesh, India

**\*Corresponding Author: Rakesh Kumar Verma**

Email: rakesh\_gsvm@yahoo.co.in

Received: 22<sup>nd</sup> November, 2018

Accepted: 10<sup>th</sup> January, 2019

### Abstract

**Introduction:** Acute myeloid leukemia (AML) is a tumor of hematopoietic progenitors caused by acquired oncogenic mutations that impede differentiation, leading to the accumulation of immature myeloid blasts in the marrow. The single most important prognostic factor in AML is cytogenetics, which determine the prognosis and probability of relapse after treatment. Hence the cytogenetic analysis of AML patients plays a great role in prognosis and treatment.

**Materials and Methods:** Karyogram of diagnosed patients of AML was prepared from bone marrow and peripheral blood. This study was conducted in the Cytogenetic Laboratory of the Department of Anatomy, King George's Medical University, UP, Lucknow. Patients were screened in the Department of Pediatrics Medicine and the samples were collected from there.

**Observations and Results:** We observed the frequency of chromosomal aberrations in different age groups and sex. Out of 22 successful cases 12 cases (54.54%) exhibited abnormal karyogram and 10 cases (45.45%) showed normal karyogram. Among total 22 cases, structural chromosomal abnormalities were observed in 11 cases (50%). Translocation was present in 9 cases (40.90%), p-arm abnormality on chromosome 19 (add 19p) was present in 1 case (4.54%) and q-arm abnormality on chromosome 16 (del 16q) was present in 1 case (4.54%).

**Discussion and Conclusion:** Translocation was found to be the most common structural anomaly in AML. We observed translocation t(8;21) in 9.09% cases. Other translocation was t(9;22) which was found in 9.09% cases. t(9;11) was observed in 9.09% cases in our study. t(15;17) was noted in 4.54% case which was also noted by previous authors. In AML t(8;21), t(15;17), inv(16) has good prognosis, intermediate prognosis is seen in abnormal 11q23, while del5q), abnormal 3q, complex cytogenetic had poor prognosis.

**Keywords:** Acute myeloid leukemia (AML), Karyogram, Chromosomal aberrations, Anomalies, Translocation.

### Introduction

Acute myeloid leukemia (AML) is a cancer of the myeloid line of blood cells, characterized by the rapid growth of abnormal myoblast cells that accumulate in the bone marrow and interfere with the production of normal blood cells. AML is characterized by accumulation of cells at the early stages of the differentiation process.<sup>1</sup> AML is a heterogeneous disease, which comprises multiple subtypes.<sup>2,3</sup> The subtypes are classified according to the FAB classification system which is based on types and maturation of myoblast cells. Several risk factors and chromosomal abnormalities have been identified, but the specific cause is not clear. The single most important cause of AML is cytogenetic, or the chromosomal structure of the leukemic cell and also has prognostic value. Certain cytogenetic abnormalities are associated with very good outcomes (e.g. t (15; 17) translocation in acute promyelocytic leukemia). About more than half of AML patients have normal karyogram, they fall into an intermediate risk group. A number of other cytogenetic abnormalities are known to be associated with a poor prognosis and a high risk of relapse after treatment.<sup>4</sup> In AML, t(8;21), t(15;17), inv(16) has good prognosis, intermediate prognosis is seen in abnormal 11q23, all other structural or numerical changes and poor prognosis is seen in 5, -7, del(5q), abnormal 3q, complex cytogenetic.<sup>5,6</sup>

The prognosis of leukemia also depends on ages of the patients. Combination of age, cytogenetic status, and white blood cell count (WBC) is a good prognostic factor. Young age tends to be associated with favorable prognosis, while old age is associated with poor prognosis. As t(8;21), inv(16) and t (15; 17) are indicators of favorable prognosis while, deletion or loss of chromosome 5 or 7 or both is associated with poor prognosis.<sup>7</sup>

About 45-50% of AML patients have no detectable chromosomal abnormalities. In general, these individuals with a normal karyotype in their leukemic cells show an intermediate prognosis.<sup>8,9</sup>

Hence cytogenetic analysis of AML patients plays a great role in diagnosis, explaining prognosis and deciding the treatment.

### Materials and Methods

This study was conducted in the Cytogenetic Laboratory of the Department of Anatomy, King George's Medical University, UP, Lucknow. Patients were screened in the Department of Pediatrics and Department of Medicine and the sample was collected from the Department of Pathology. The study was approved by ethical committee of King George's Medical University, UP, Lucknow. Karyogram was prepared from bone marrow and peripheral blood. The patients included in this study were clinically diagnosed cases (male or female) of any age group and

informed consent was taken from each patient. Patients without consent (lack of consent) were excluded from the study.

**Observation and Results**

We observed the frequency of chromosomal aberrations in different age groups and sex. Total 34 cases were analyzed in which 22 karyograms were obtained successfully. Out of 22 successful cases, 12 cases (54.54%) exhibited abnormal karyogram and 10 cases (45.45%)

showed normal karyogram. Among total 22 cases, structural chromosomal abnormalities were observed in 11 cases (50%) and numerical chromosomal abnormalities were noted in 7 cases i.e. 31.81%. In successfully obtained 22 karyogram, 12 (54.54%) were male and 10 (45.45%) were female. Among 10 female karyogram, 6 karyogram were normal without any chromosomal aberrations and 4 karyogram were abnormal with chromosomal abnormalities (Table 1).

**Table 1: Gender wise distribution of cases with chromosomal abnormalities**

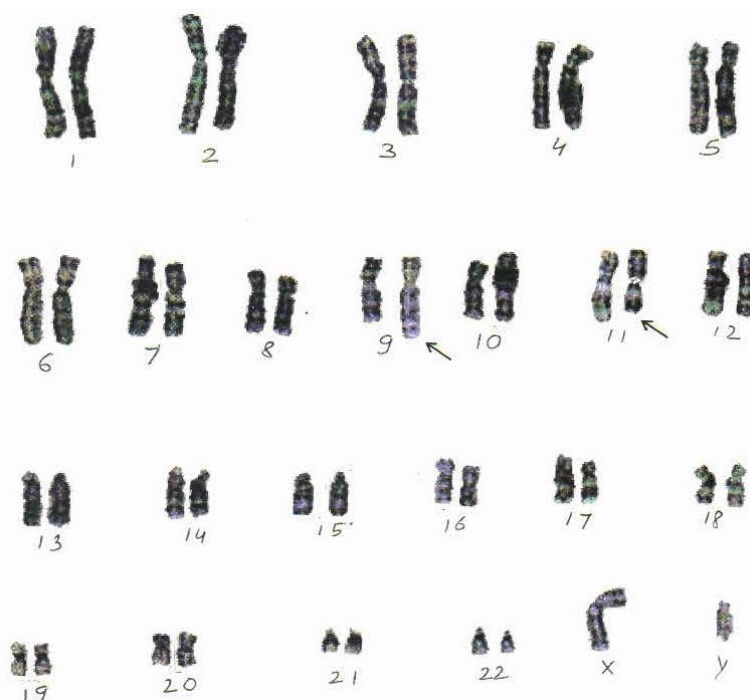
Sex	Number of Cases	Karyogram Obtained	Normal Karyogram	Abnormal Karyogram
Male	22	12	4	8
Female	12	10	6	4
	Total=34	Total =22	Total =10	Total =12

In structural chromosomal abnormalities, translocations was present in 9 cases (40.90%), p-arm abnormality on

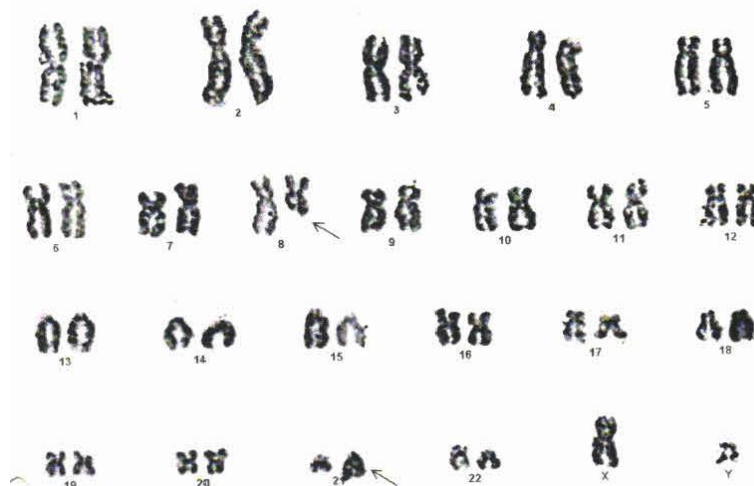chromosome 19 (add 19p) was present in 1 case (4.54%) and q-arm abnormality on chromosome 16 (del 16q) was present in 1 case (4.54%) (Table 2, Fig. 1, 2).

**Table 2: Prevalence of structural chromosomal abnormalities in overall studied karyograms/total cases with abnormal karyograms**

Structural Chromosomal Abnormalities	Number of Patients	Percentage (%) (N=22)
t(9;11)	2	9.09
t(8;21)	2	9.09
t(9;22)	2	9.09
t(15;17)	1	4.54
t(3;9)	1	4.54
t(4;7)	1	4.54
add 19 p+	1	4.54
del 16 q-	1	4.54



**Fig. 1: Karyogram 46XY, t(9;11)**



**Fig. 2: Karyogram 46XX, t(9;21)**

### Discussion

Acute myeloid leukemia is a heterogeneous group of diseases with several discrete syndromes having characteristic clinical, morphological and cytogenetic features. Cytogenetic abnormalities were observed in 54.54% of cases, comparable to large studies from different geographic regions (range of 52- 80% abnormalities) as stated by various researchers.<sup>10,11</sup> Our findings are nearly similar to Enjeti et al. (2004) who reported 61% of abnormal cases in South East Asia region (Singapore).<sup>12</sup>

In the present study, t(9;11) was found in two cases (9.09%) and this finding is in concordance with that of Ten et al. (1992) who described this translocation in 3 patient of Malaysians of aged 5 & 31 year male and 2 year female, and despite it the most common translocation (Table 2, Fig. 1).<sup>13</sup> but Singapore population showed 61% abnormal cytogenetics.<sup>12</sup> Translocation (15;17) is found exclusively in acute promyelocytic leukemia (Park et al., 2008). He described that t(15;17) and trisomy 8 were the most frequent karyotypic abnormalities seen in 52 cases (11%) and 33 cases (7.3%) respectively.<sup>14</sup> In our study these chromosomal aberration were noted in North Indian population i.e t (15;17) in one case (4.54%) and trisomy 8 in two case (9.09%).

t(8;21) is described by many authors in their study viz Movafagh (2011) studied it in 127 adult patient of Iran and found it in 35 patient (27.5%), Moorman et al. (2002) studied 600 patients of aged 16 to 69 year out of which 472 (79%) was successful and observed t(8;21) in 32 cases (5.33%).<sup>15,16</sup> We also observed t(8;21) in 2 (9.09%) cases which is categorized in AML -M2 according to FAB classification (Table 2, Fig. 2). Previous studies have reported the incidence of t(8;21) to be higher in Japanese and Taiwanese population i.e 33.1% and 34% respectively, 14.5% in Singapore, 22% in North American and 15.3% in Australian population.<sup>5,12,13,16-19</sup> We noted the incidence in North Indian population to be 9.09% which is closer to that of Singapore population.

Movafagh et al. (2009) studied 65 patient of Iranian population aged 15 to 72 years and 62 Indian patient of aged 15 to 75 years and observed t(15;17) the most frequent type of translocation, 22 cases (33.8%) in Iranian population and 12 cases (19.3%) in Indian population. which we found it in one case (4.54%) in North Indian population. He also noted t(9;22) in 11 cases (16.9%) in Iranian population and 7 cases (11.3%) in Indian patients which was seen by us in 2 cases (9.09%) but we did not found inv(16)11q23 as described by him.<sup>15</sup>

We observed del 16(q) in one case (4.54%) while Enjeti et al. (2004) reported inv (16) and t(16;16) as uncommon occurrence.<sup>12</sup> This finding does not support as described by Movafagh et al. (2009) who described inv(16) occurring more frequently in Indian i.e. 2 cases out of 62 (3.2%) than Iranian 2 cases (3%) out of 65.<sup>15</sup>

None of the studies was found to the best of our knowledge about add 19(p) which was found in one case (4.54%) in the present study. The present study will be extended by including more number of patients with longer follow- up duration.

### Conclusion

In this study we observed the chromosomal aberrations in different age groups and sex and also frequency of various chromosomal structural anomalies in acute myeloid leukemia in North Indian population. Structural chromosomal abnormality in this study was in 11 cases (50%) out of 22 cases, in which translocation was most frequent and other were less. There are only a few population-based studies on AML subjects available in the literature. It is possible that ethnic and geographic factors (or both) could explain some of the variations from the previous findings by different authors. Large epidemiological studies involving different geographic regions of the world would enable the true nature of environmental and genetic interplay in AML to be completely unfolded. So cytogenetic analysis of AML patients plays a great role in to reveal burden of

chromosomal abnormalities in particular population, prognosis and treatment accordingly.

**Conflict of Interest:** None.

## References

1. Wildonger J and Mann RS. The t (8; 21) translocation converts AML 1 into a constitutive transcriptional repressor. *Development* 2005;132:2263-2272.
2. Burmeister T and Thiel E Molecular genetics in acute and chronic leukemias. *J Cancer Res Clin Oncol* 2001;127:80-90.
3. Bacher U, Kern W, Schnittger S et al. Further correlations of morphology according to FAB and WHO classification to cytogenetics in de novo acute myeloid leukemia: a study on 2,235 patients. *Ann Hematol* 2005;84 (12):785-791.
4. Wheatley K, Burnett A, Goldstone A, Gray R, Hann I, Harrison C, Rees J, Stevens R and Walker H. A simple, robust, validated and highly predictive index for the determination of risk-directed therapy in acute myeloid leukemia derived from the MRC AML 10 trial. United Kingdom Medical Research Council's Adult and Childhood Leukemia Working Parties. *Br J Haematol* 1999;107(1):69-79.
5. Grimwade D, Walker H, Harrison G, Oliver F, Chatters S, Harrison CJ et al. Medical Research Council Adult Leukemia Working Party. The predictive value of hierarchical cytogenetic classification in older adults with acute myeloid leukemia (AML): analysis of 1065 patients entered into the United Kingdom Medical Research Council AssML11 trial. *Blood* 2001;98:1312-1320.
6. Stone RM, O'Donnell MR, Sekeres MA. Acute myeloid leukemia. *Hematol Am Soc Hematol Educ Prog* 2004;98:117.
7. Cripe LD. Adult acute leukemia. *Curr Probl Cancer* 1997;21:1-64.
8. Caligiuri MA, Schichman SA, Strout MP, Mrózek K, Baer MR, Frankel SR, et al. Molecular rearrangement of the ALL-1 gene in acute myeloid leukemia without cytogenetic evidence of 11q23 chromosomal translocations. *Cancer Res* 1994;54:370-373.
9. Mrózek K, Marcucci G, Paschka P, Whitman SP, Bloomfield CD. Clinical relevance of mutations and gene-expression changes in adult acute myeloid leukemia with normal cytogenetics: are we ready for a prognostically prioritized molecular classification? *Blood* 2007;109:431-448.
10. Heim S, Mitelman F (eds). *Cancer Cytogenetics*. Wiley-Liss: New York, 1995;72-73.
11. Tien HF, Wang CH, Lin MT, Lee FY, Liu MC, Chuang SM et al. Correlation of cytogenetic results with immunophenotype, genotype, clinical features and ras mutation in acute myeloid leukemia. A study of 235 Chinese patients in Taiwan. *Cancer Genet Cytogenet* 1995;84:60-68.
12. Enjeti AK, Tien SL, Sivaswaren CR. Cytogenetic abnormalities in de novo acute myeloid leukemia in adults: relation to morphology, age, sex and ethnicity – a single center study from Singapore. *Hematol J* 2004;5:419-425.
13. Ten SK, Khan MK, Khalid H, Lin HP, Ng SC, Cheong SK, Yasmin A and Khuzaiah RR. Abnormalities of chromosome 11Q in three cases of acute myeloid leukemia. *Singapore Med J* 1992;33:164-166.
14. Park TS, Choi JR, Yoon SH, et al. Acute promyelocyticlekemia replacing as secondary acute myelogenousleukemia with translocation t(3;21) (q26;q22) and RUNX1- MDS1-EVIY fusion transcript. *Cancer Genet Cytogenet* 2008;187:61-73.
15. Movafagh A, Hajifathal, A, Isfahani F, Attarian H, Ghadiani M, Rezvani H, Heidari MH, Miri R and Haji Seyed Javadi M. Geographic Heterogeneity of Cytogenetic Characteristics of Acute Myeloid Leukemia in the early detection: A Comparative Study of Iranian and Indian adult Patients. *Iranian J Cancer Prev* 2009;2(2):85-89.
16. Moorman AV, Roman E, Cartwright RA, and Morgan GJ. Leukemia Research Fund Centre for Clinical Epidemiology. *Br J Cancer* 2002;86:60-62.
17. Nakase K, Bradstock K, Sartor M, Gottlieb D, Byth K, Kita K et al. Geographic heterogeneity of cellular characteristics of acute myeloid leukemia: a comparative study of Australian and Japanese adult cases. *Leukemia* 2000;14:163-168.
18. Slovak ML, Kopecky KJ, Cassileth PA, Harrington DH, Theil KS, Mohamed A et al. Karyotypic analysis predicts outcome of premission and postremission therapy in adult acute myeloid leukemia: a Southwest Oncology Group/Eastern Cooperative Oncology Group Study. *Blood* 2000;96:4075-4083.
19. Mauritzson N, Johansson B, Albin M, Billström R, Ahlgren T, Mikoczy Z. et al. A single-center population based consecutive series of 1500 cytogenetically investigated adult hematological malignancies: karyotypic features in relation to morphology, age and gender. *Eur J Haematol* 1999;62:95-102.

**How to cite this article:** Verma RK, Rao S, Kumar N, Singh US, Kumar A. Incidence of structural chromosomal anomalies in patients of acute myeloid leukemia in North Indians. *Indian J Clin Anat Physiol* 2019;6(1):89-92.