

# A Rare Case of Pulmonary Actinomycosis Presented as a Pseudotumor Diagnosed after Pneumonectomy: A Case Report and Literature Review

Pichaya Petborom, M.D.\*, Prasit Upanan, M.D.\*\*

\*Division of Pulmonary and Critical Care Medicine, \*\*Division of Infectious Disease, Department of Medicine, HRH Princess Maha Chakri Sirindhorn Medical Center (MSMC), Faculty of Medicine, Srinakharinwirot University, Nakhon Nayok 26120, Thailand.

## ABSTRACT

Pulmonary actinomycosis is a rare, slowly progressive infectious disease which is difficult to diagnose. The disease can mimic lung malignancy, given its nonspecific clinical and radiological presentations, thus posing a diagnostic dilemma to the physician. Making the diagnosis can be complicated. Surgical procedures such as CT-guided trans-thoracic needle biopsy, bronchoscopic techniques, or even surgical resections may aid the diagnosis based on histopathological examinations and cultures of the lung tissues. Hence, with the frequent suspicion of a malignancy, physicians are usually prompted to resort to surgical diagnostic procedures. The authors report a patient with a rare case of pulmonary actinomycosis which presented as a mass-like lesion in his lung, which was diagnosed after pneumonectomy.

**Keywords:** Pulmonary actinomycosis (Siriraj Med J 2017;69:35-39)

## INTRODUCTION

Actinomycosis is a rare, chronic suppurative infection, which infiltrates mucosa-associated tissues and may occur in any individuals of all ages.<sup>1,2</sup> The peak incidence of the disease is reported to be the 4<sup>th</sup> and 5<sup>th</sup> decade of life, and males are infected more frequently than females.<sup>2</sup> The pulmonary form of actinomycosis constitutes approximately 15-50% of all cases.<sup>3</sup> *Actinomyces* spp., are facultative anaerobic gram-positive, prokaryotic bacteria, belonging to the residential flora of the oropharynx, gastrointestinal tract, and female genital tract.<sup>2,4</sup> *Actinomyces israelii* (*A. israelii*), the main species responsible for the human disease, was isolated in 1891.<sup>5</sup> Pulmonary actinomycosis is difficult to diagnose. The misdiagnosis or delayed diagnosis as lung abscess, tuberculosis or lung cancer is common.<sup>6</sup> The authors report a rare case of pulmonary actinomycosis which presented as a pseudotumor and was diagnosed after pneumonectomy.

## CASE REPORT

A 60-year-old male with underlying diseases of hypertension, old ischemic stroke and dyslipidemia, presented with non-massive hemoptysis for 1 month. He reported low-grade fever, productive cough with whitish sputum and weight loss of 10 kilograms. He experienced mild dyspnea on exertion and had a 15 pack-year history of smoking. There was no history of recurrent infections or other evidence of immunodeficiencies. Any history of drugs or alcohol abuse was denied. On physical examinations, the body temperature was 36.5°C, blood pressure was 142/74 mmHg, pulse rate was 72 beats per minute, and respiratory rate was 20 times per minute. He was mildly pale and had very poor oral hygiene. Other physical examinations were within normal limits. The complete blood count (CBC) showed a hematocrit of 33.7 %, and white blood cell (WBC) count of 13,150 cells per mm<sup>3</sup> with 77.9% neutrophils,

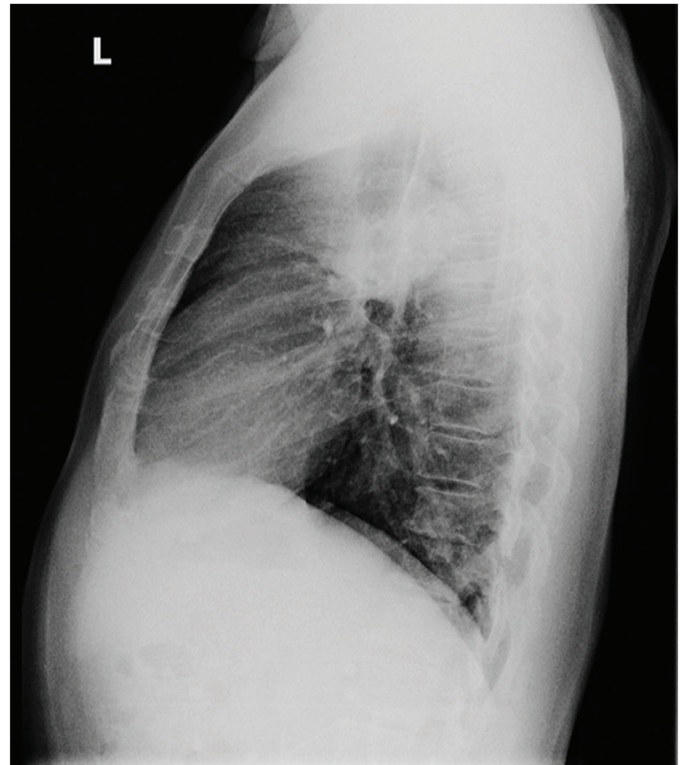
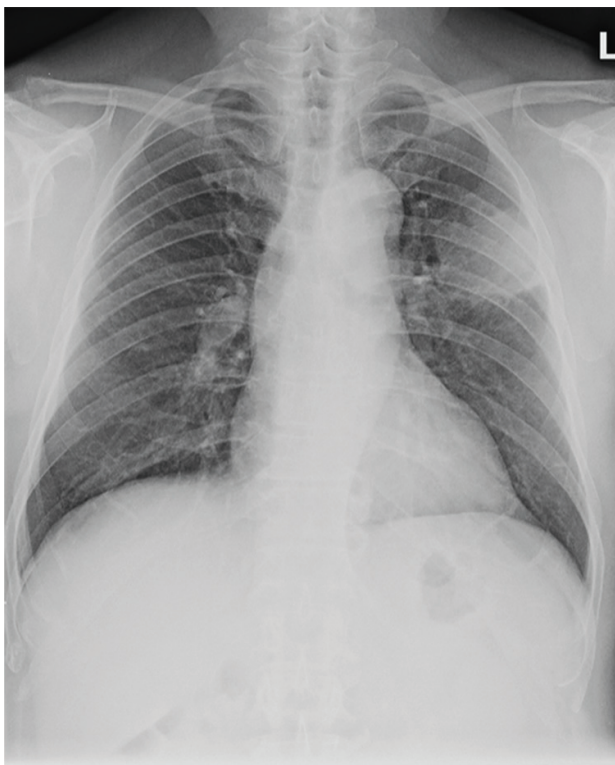
Correspondence to: Pichaya Petborom

E-mail: turn\_turn@hotmail.com

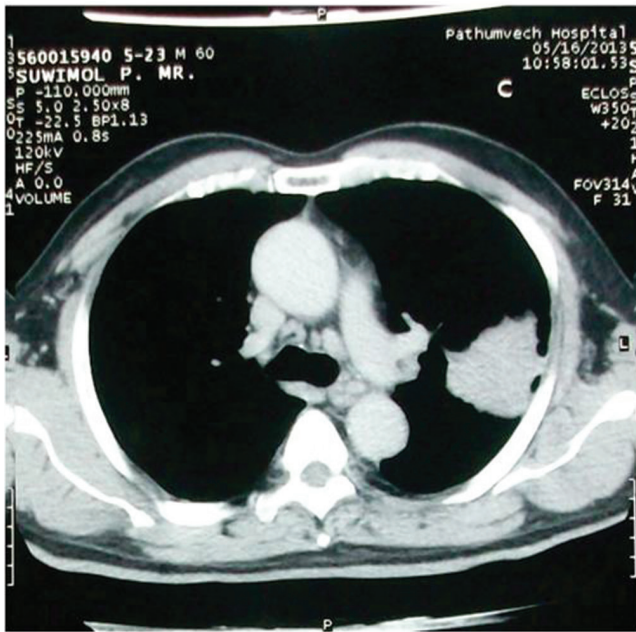
doi:10.14456/smj.2017.7

13.7% lymphocytes and 7.7% monocytes, and platelet count was 294,000 cells per mm<sup>3</sup>. Acid-fast stained sputum smears were negative for 3 days consecutively. A chest radiograph (Fig 1A, B) demonstrated a mass-like opacity of 5 cm in diameter at the left upper lobe. The computed tomography scan (CT) of the chest with intravenous contrast (Fig 2) revealed an irregular-shaped mass of 3.5 x 5.2 cm with spiculated border, detected in the apico-posterior segment of the left upper lobe. Multiple enlarged lymph nodes were found in the peri-aortic, aorto-pulmonary window and precarina regions. Enhancement of the lesion in the post-intravenous contrast study was observed from about 40-50 Hounsfield units (HU) in the non-contrast study to about 60-70 HU in the post-intravenous contrast study. The findings of the CT scans of the chest were highly suggestive of lung cancer. Bronchoscopy was performed. Cytology from the bronchoalveolar lavage and the transbronchial lung biopsy demonstrated chronic inflammations, but the microbiologic studies which included culture for bacteria,

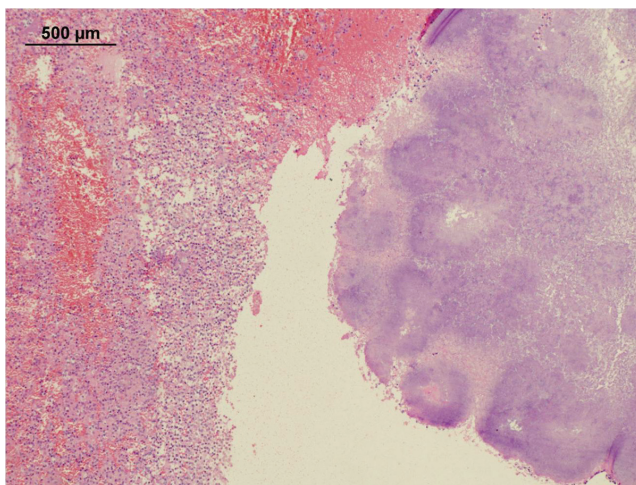
mycobacteria, and fungus were negative. Due to the highly suggestive of lung cancer from CT scans, the patient was referred to the cardio-thoracic surgery department of our hospital for left pneumonectomy. The sections at the middle and lower parts of the upper lobe of the left lung revealed colonies of filamentous or fungus-like branched networks of hyphae organisms in a space which was lined by bronchial epithelium (Fig 3). They were heavily infiltrated by acute and chronic inflammatory cells. The surrounding lung tissue showed fibrosis, atelectasis, and focal hemorrhages, with the infiltrations of acute and chronic inflammatory cells. These organisms were positive for Gomori's methenamine silver (GMS) stain (Fig 4), but negative for acid fast stain and modified acid fast stain. The final diagnosis was pulmonary actinomycosis. Treatment with amoxicillin 3 grams per day was initiated for 6 months. His symptoms were improved, he had weight gain of 12 kilograms and his erythrocyte sedimentation rate (ESR) decreased from 116 millimeters per hour (mm/hr) to 30 mm/hr.




**A** **B**  
**Fig 1. A)** Postero-anterior upright view and **B)** (Lateral view) Chest radiographs demonstrated a mass-like opacity of 5 cm in diameter at the left upper lobe.



**Fig 2.** The axial CT scan of the chest revealed an irregular shaped mass measured 3.5 x 5.2 cm with spiculated border was detected in the apico-posterior segment of left upper lobe.



**Fig 3.** Histologic findings from left pneumonectomy revealed colonies of filamentous or fungus-like branched networks of hyphae organisms in a space which is lined by bronchial epithelium.



**Fig 4.** The organisms were positive for GMS stain.

## DISCUSSION

*Actinomyces* spp., are a group of higher prokaryotic bacteria belonging to the family Actinomycetaceae.<sup>6</sup> The most common form of human actinomycosis is the cervicofacial type, which has the prevalence of 50-60%.<sup>6</sup> It is now a rare infection, particularly in the developed countries. Pulmonary actinomycosis generally results from the aspiration of the oropharyngeal or gastrointestinal secretions into the respiratory tract.<sup>7</sup> Poor oral hygiene, dental caries, and alcoholism can also conduce to the development of the disease.<sup>7</sup> Pulmonary actinomycosis can be found at all ages, nevertheless most series reported a clear peak incidence in the 4<sup>th</sup> and 5<sup>th</sup> decades of life.<sup>6</sup> The incidence of infection is two to four times greater in males, compared to females because of the higher tendency for the poorer oral hygiene and/or a higher incidence of facial trauma.<sup>6,8</sup> Our patient was a 60-year-old man who had a very poor oral hygiene with multiple dental caries that may have contributed to the progression of the disease. Pulmonary actinomycosis is rare, and often misdiagnosed as bronchopneumonia or lung cancer.<sup>9</sup> The misdiagnosis, particularly for malignancies, is distressing for the patient who may end up with a thoracotomy or lung resection for essentially a benign and curable disease.<sup>6</sup> In our patient, he received the definite diagnosis after left pneumonectomy because of the high suspicion for lung cancer from CT scan of the chest. The onset of pulmonary actinomycosis is insidious with the three commonest complaints of cough, increased sputum and chest pain.<sup>10</sup> Our patient had a productive cough with whitish sputum without chest pain for 1 month. Patients have hemoptysis and weight loss about 30 and 50 percent, respectively.<sup>10</sup> Our patient presented with non-massive hemoptysis and had a significant weight loss. Our patient also had low-grade fever, which occurs in about 20% of the patients.<sup>10</sup> Basic laboratory tests reflect the nonspecific inflammatory nature of the disease.<sup>6</sup> Our patient had mild leukocytosis, predominantly polymorphonuclear with normochromic red blood cells anemia that usually occurs in this disease.<sup>6</sup> Plain chest radiograph findings in actinomycosis are non-specific and the spectrum of changes is wide, ranging from a few pulmonary infiltrations to cavitating mass-like lesions involving the pleura, chest wall or even spine vertebrae.<sup>6,11,12</sup> The presence of air bronchogram within the mass-like lesion should suggest the possibility of a non-malignant process, such as actinomycosis.<sup>2</sup> Dujneungkunakorn et al, reported 16 patients with pulmonary actinomycosis in Thailand with mass-like shadowings as the most common radiographic finding (37%).<sup>13</sup> The chest radiograph of our patient demonstrated

a mass-like opacity without any cavity or air bronchogram at the left upper lobe. Chronic segmental air-space consolidations which contain low-attenuation areas with peripheral enhancement and adjacent pleural thickening are typical CT findings of pulmonary actinomycosis.<sup>14,15</sup> In the early stage of infection, the disease manifests as a small, poorly defined, peripheral pulmonary nodule with or without interlobular septal thickening.<sup>15</sup> The pulmonary nodule indolently increases, to the extent, to manifest as an air-space consolidation or a mass with the slow progression of the infection.<sup>15</sup> Further progression of the infection may involve the pleura and chest wall, and the associated pleural effusions tend to be small-to-moderate in size, rather than massive effusions.<sup>2,15</sup> The CT scan of a chest in our patient revealed an irregular shaped mass with spiculated border in the left upper lobe with enhancement in the post-intravenous contrast study, and there were multiple mediastinal lymphadenopathies, so lung cancer was suspected. Despite not generally used as the diagnostic tool for the pulmonary actinomycosis, the fiberoptic bronchoscopy is a useful investigation for excluding the lung malignancy.<sup>6</sup> Bronchoscopy was performed in our patient and histopathology demonstrated only chronic inflammations. Currently, the percutaneous biopsy with fine needle aspiration or core biopsy, with ultrasound or CT guidance, is now routinely done before the thoracotomy.<sup>6,16</sup> Since the clinical and gross intra-operative pictures of the pulmonary actinomycosis, can be imperceptible from that of carcinoma, a minimally invasive approach, such as video-assisted thoracic surgery (VATS), as well as a limited pulmonary resections and a frozen sections, to decide the subsequent interventions is recommended.<sup>17</sup> Unfortunately, our patient proceeded to the pneumonectomy before any minimally invasive attempts. Due to the non-aerobic nature of the *Actinomyces* spp., they are not usually recovered from expectorated sputum or bronchoscopy aspirates.<sup>2</sup> In our patient, there was no culture observed from the fluid collected from the bronchoalveolar lavage which might result from non-anaerobic bacterial cultures of the specimens. Nevertheless, *Actinomyces* spp., can occasionally be obtained incidentally from the sputum of the patients with carcinoma, because the organism can colonize necrotic tissue.<sup>2</sup> The diagnosis of pulmonary actinomycosis requires a combination of several factors, including a positive culture with demonstrations of sulfur granules in the purulent matter

from the infected tissue, in correlation with the clinical and radiological features, and the response to the antibiotic treatment.<sup>6</sup> The appearance of radiationally arranged sulfur granules is the pathological hallmark of this disease.<sup>17</sup> However, these granules could be found in many other diseases such as nocardiosis or chromomycosis as well.<sup>17</sup> Untreated, pulmonary actinomycosis is ultimately fatal, whereas early treatment can prevent late complications and result in cure rates of over 90%.<sup>2</sup> The recommended treatment is the use of high-dose intravenous penicillin of 18-24 million units per day over 2-6 weeks time span and then followed by oral therapy with penicillin V or amoxicillin for another 6-12 months.<sup>6</sup> Tetracycline is the alternative option especially for those with penicillin-allergies.<sup>6</sup> Our patient had a definite diagnosis after the pneumonectomy and received oral amoxicillin for 6 months. His symptoms improved and the hemoptysis disappeared after the treatment. Even though surgical drainage of any abscesses and empyemas, as well as excision of the sinus tracts are often helpful, appropriate antibiotic coverage should still be administered as soon as the operations are done to prevent any possible complications or spreading of the disease.<sup>2</sup>

## CONCLUSION

Learning from a very rare case of a pulmonary actinomycosis presented as a pseudo-tumor and diagnosed by post-pneumonectomy, pulmonary actinomycosis, despite being uncommon, is a very devastating disease. The diagnosis can be very challenging, despite the highly suggestive clinical presentations, as it can be easily confused with other chronic suppurative lower respiratory tract diseases or even malignancies. Keeping the pulmonary actinomycosis in mind, all of the related specimens should be collected especially the tissue pathologies and the anaerobic bacterial cultures of the specimens which are the cornerstone for diagnosing the disease. Being a treatable disease, early and precise diagnosis of the pulmonary actinomycosis is vital. Pulmonary actinomycosis can be medically treated with good prognosis, due to the high sensitivities to multiple common antibiotics.

## ACKNOWLEDGMENTS

Department of Pathology HRH Princess Maha Chakri Sirindhorn Medical Center (MSMC), Faculty of Medicine, Srinakharinwirot University, Nakhon Nayok, Thailand.

**REFERENCES**

1. Lerner PI. Actinomyces and Arachnia species. In: Mandell GL, Douglas RG, Bennett JE, eds. Principles and practice of infectious diseases. New York, Churchill Livingstone, 1991. p.1932-42.
2. Yildiz O and Doganay M. Actinomycoses and Nocardia pulmonary infections. *Curr Opin Pulm Med* 2006;12:228-34.
3. Ferreira Dde F, Amado J, Neves S, Taveira N, Carvalho A, Nogueira R. Treatment of pulmonary actinomycosis with levofloxacin. *J Bras Pneumol* 2008;34(4):245-8.
4. Dalhoff K, Wallner S, Finck C, Gatermann S, Wiessmann KJ. Endobronchial actinomycosis. *Eur Respir J* 1994;7:1189-91.
5. Lerner PI. Actinomyces and arachnia. In: Wonsiewicz MJ, ed. Infectious Diseases. Philadelphia, W.B. Saunders Co., 1992. p.1626-32.
6. Mabeza GF, Macfarlane J. Pulmonary actinomycosis. *Eur Respir J* 2003;21(3):545-51.
7. Santos JW, Nascimento DZ, Guerra VA, Vassoler RM, Simon TT, Machado FP, et al. Pulmonary Actinomycosis: An old disease that is still diagnosed late. *Clin Pulm Med* 2008;15(3): 173-6.
8. Bennhoff DF. Actinomycosis: diagnosis and therapeutic considerations and a review of 32 cases. *Laryngoscope* 1984;94:1198-217.
9. Ferreira HP, Araujo CA, Cavalcanti JF, Miranda RL, Ramalho Rde A. Pulmonary actinomycosis as a pseudotumor: A rare presentation. *J Bras Pneumol* 2011;37(5):689-93.
10. Smego RA, Foglia G. Actinomycosis. *Clin Infect Dis* 1998;26:1255-63.
11. Webb WR, Sagel SS. Actinomycosis involving the chest wall: CT findings. *AJR* 1982;139:1007-9.
12. Flynn MW, Felson B. The roentgen manifestations of thoracic actinomycosis. *AJR* 1970;11:707-16.
13. Dujneungkunakorn T, Riantawan P, Tungsagunwattana S. Pulmonary actinomycosis: a study of 16 cases from central chest hospital. *J Med Assoc Thai* 1999;82(6):531-5.
14. Cheon JE, Im JG, Kim MY, Lee JS, Choi GM, Yeon KM. Thoracic actinomycosis: CT findings. *Radiology* 1998;209: 229-33.
15. Kim TS, Han J, Koh WJ, Choi JC, Chung MJ, Lee JH, Shim SS, Chong S. Thoracic Actinomycosis: CT features with histopathologic correlation. *AJR* 2006;186:225-31.
16. Hsu WH, Chiang CD, Chen CY. Ultrasound-guided fine needle aspiration biopsy in the diagnosis of chronic pulmonary infection. *Respiration* 1997;64:319-25.
17. Lin MS, Lin WL, Luh SP, Tsao TC, WU TC. Pulmonary actinomycosis: a case undergoing resection through video-assisted thoracic surgery(VATS). *J Zhejiang UnivSci B* 2007;8(10):721-4.