

Hirschsprung's Disease: Review Article

Akkrapol Mungnirandr, M.D.

Department of Surgery, Faculty of Medicine Siriraj Hospital, Mahidol University, Bangkok 10700, Thailand

ABSTRACT

Congenital megacolon is one of the most common diseases in pediatric surgical practice. Although this is a common disease, the results of treatment varies between each surgeon and institute. Some patients have severe post-operative complications which cause disable and eventually death. Better understanding in the disease in every aspect will improve treatment outcomes and decrease post-operative complications. In the last decade, new knowledge about the disease has been found. The author reviews the disease in the aspect of pathophysiology, diagnosis, and treatment.

Keywords: Congenital megacolon; Hirschsprung's disease review (Siriraj Med J 2017;69: 223-227)

INTRODUCTION

Hirschsprung's disease is an ancient disease. The ancient Hindu Sushruta book described Badda Gudodaram; the disease in childhood that caused distal colonic obstruction without any visible cause of obstruction. The patient had feculent vomiting and distended abdomen.¹ The name Hirschsprung's came from Dr. Harald Hirschsprung, who first described 2 children who died from intestinal ulcer, small rectum, and large colon in 1887.²

Pathogenesis

The cause of the disease is the arrest of migration and differentiation of enteric neural crest-derived cells (ENCCs) from foregut to hindgut during 4th -7th after gestation.³⁻⁷ However, there is some transmesenteric migration of ENCCs reported.⁸ Many transcription factors had roles for ENCCs migration and differentiation such as SOX10, PHOX2B and ZWB2 and endothelin. Absence or malfunction of these factors will cause arrest of migration or differentiation of ENCCs.^{9,10}

Clinical manifestation

Majority of patients manifest clinical symptoms during infancy. The common clinical manifestations are

delayed passage of meconium within 24 hours, abdominal distention, and vomiting.^{11,12} Burst of stool after per rectal examination is the typical finding. History of constipation with frequent rectal irrigation and foul smell faeces can be found in the older children.^{11,13} Delayed passage of meconium may be found in preterm infants due to immature gastrointestinal motility function.¹⁴

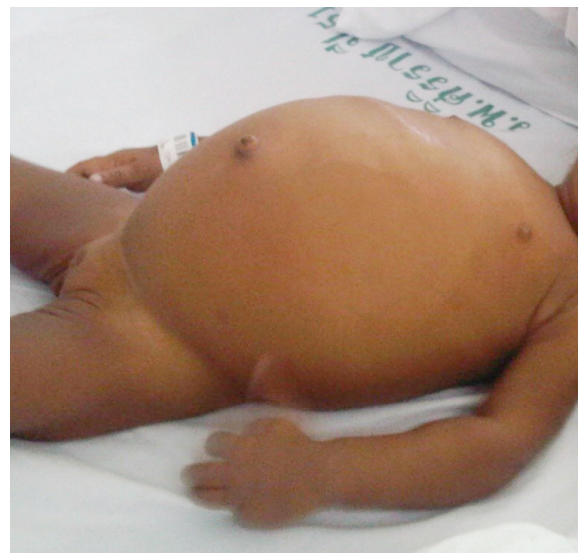

Fig 1. Hirschsprung's disease with abdominal distention

Correspondence to: Akkrapol Mungnirandr

E-mail: siakkmn@yahoo.com

Received 15 February 2017 Revised 16 March 2017 Accepted 21 March 2017

doi:10.14456/smj.2017.45

Enterocolitis is associated with Hirschsprung's disease in 6-50 percent¹⁵ and is rarely associated with other diseases. The clinical manifestations include fever, diarrhea, foul smell faeces, abdominal distention, vomiting, lethargy and shock. This condition causes mortality 1-10 % in newborn hirschsprung's disease.¹⁶ The definite cause of enterocolitis is unknown, but 2 possible hypotheses were proposed; 1. Partial obstruction of rectum or sigmoid colon causes fecal retention and enterocolitis and 2. Defective gut environment of the patients with Hirschsprung's disease such as decreased IgA and mucin production and decreased number of Lactobacillus in gut lumen.¹⁶⁻¹⁸

Investigation

Anorectal manometry is useful especially in the older child to differentiate Hirschsprung's disease from the other causes of constipation. The sensitivity and specificity were 88.4 and 94.2 % respectively.¹⁹ However, anorectal manometry has some technical difficulty such as small size of neonatal rectal canal, mobility during measurement, and appropriate balloon size compared to rectum.

Barium enema is commonly used for diagnosis of Hirschsprung's disease. The most important finding for diagnosis of Hirschsprung's disease is transitional Zone²⁰ Fig 3. Retention of barium after 24 hours is also commonly seen. Sensitivity and specificity of Barium enema were 73 and 90 % respectively

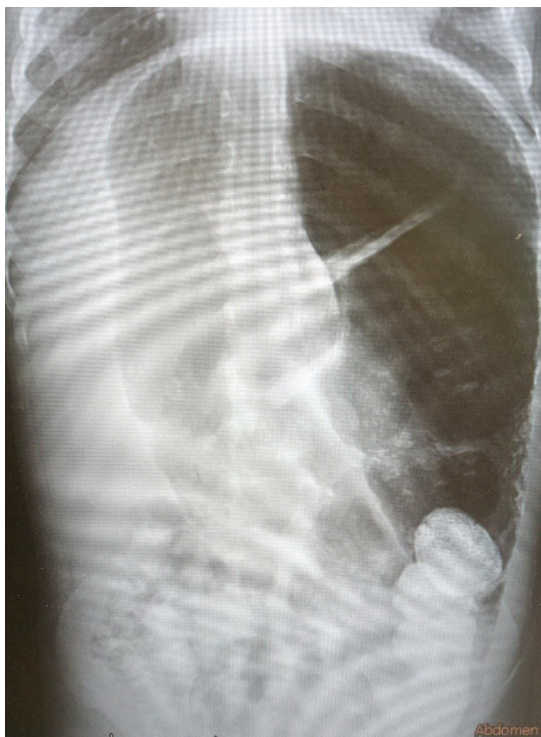


Fig 2. Abdominal radiograph of Hirschsprung's disease

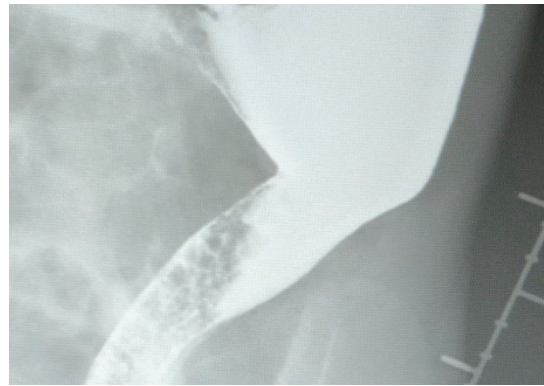


Fig 3. Transitional zone during barium enema

Gold standard for diagnosis of Hirschsprung's disease is full-thickness rectal biopsy. Diagnostic pathological findings are absence of submucosal and myenteric ganglion cells with hypertrophied nerve trunk. Rectal suction biopsy collects only mucosa at level 2-3 cm. above dentate line without general anesthesia. The sensitivity and specificity of rectal suction biopsy are 96.84 and 99.42 respectively.²¹ Inadequate tissue may occur in an older child due to thick mucosa.

Management

In patient with enterocolitis, treatment consists of broad spectrum antibiotic and rectal irrigation. Rectal washout with saline (10-20 ml/Kg) using a large bore soft tube should be initiated immediately and repeated anywhere from 2-4 times per day until proper decompression as determined by clinical examination.¹⁷

Treatment of Hirschsprung's disease is resection of aganglionic segment as much as possible without injuring anal sphincter. Colostomy should be considered in patients with very large size colon, colonic perforation, malnutrition enterocolitis refractory to rectal irrigation, and in infants who first present with enterocolitis.²² Many techniques were proposed with different results between each surgeon. Swenson's procedure aims to cut the aganglionic bowel out as much as possible. The lower margin of colon resection is about 1-2 cm. above dentate line to avoid anal sphincter injury Fig 4. Duhamel's operation combines normal bowel and aganglionic bowel. The aganglionic bowel was used as absorption part whereas the normal bowel moves the faecal content Fig 5. Soave's procedure aims to reduce sphincter injury by using technique of mucosal resection. The outer serosa is still intact with anal sphincter Fig 6. Transanal endorectal procedure also leaves serosa intact, but the procedure begins at the anus and majority do not require abdominal incision Fig 7. Illustration of each technique is shown

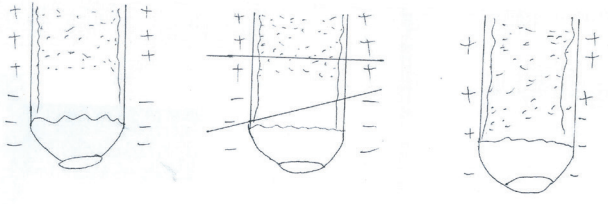


Fig 4. Swenson's Procedure

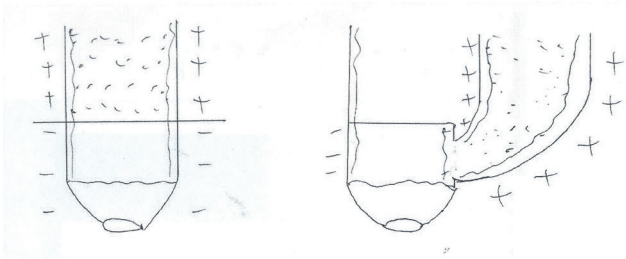


Fig 5. Duhamel's procedure

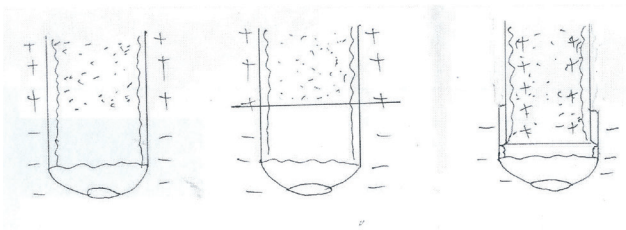


Fig 6. Soave's procedure

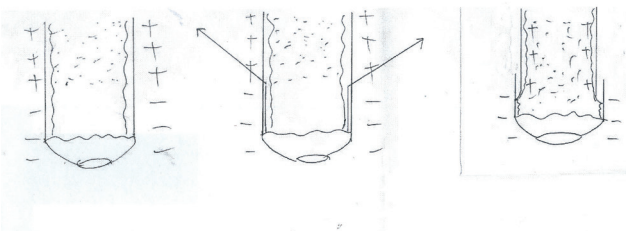


Fig 7. Transanal endorectal procedure

To facilitate field exposure; anal and perianal area, the author uses self- retaining retractor (Lonestar[®]) and finds that it is easier to do operation with less sphincter distention or injury than using Army-Navy retractor. The author prefers to operate in infants because of shallow pelvic cavity, smaller colon size, and more easy operation due to absence of enterocolitis. In the older child, it may be necessary to do rectal irrigation to reduce colonic size before operation. Assessment of colonic size suitable for operation can be evaluated by per rectal examination and abdominal radiograph.

Recent meta-analysis and systematic review showed that transanal endorectal pull-through was superior to transabdominal pull-through in operative time, hospital stay postoperative incontinence and constipation.^{23,24}

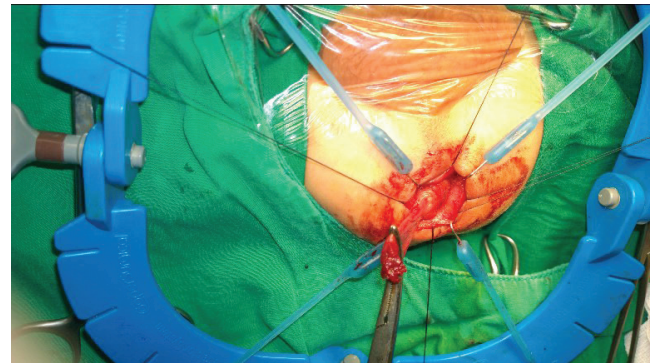


Fig 8. Lonestar[®] application to anal and perianal field

In a patient with total colonic aganglionosis, the typical clinical presentation may not present. Only two-thirds can be diagnosed during neonatal period.²⁵ Entire microcolon is found on barium enema film.

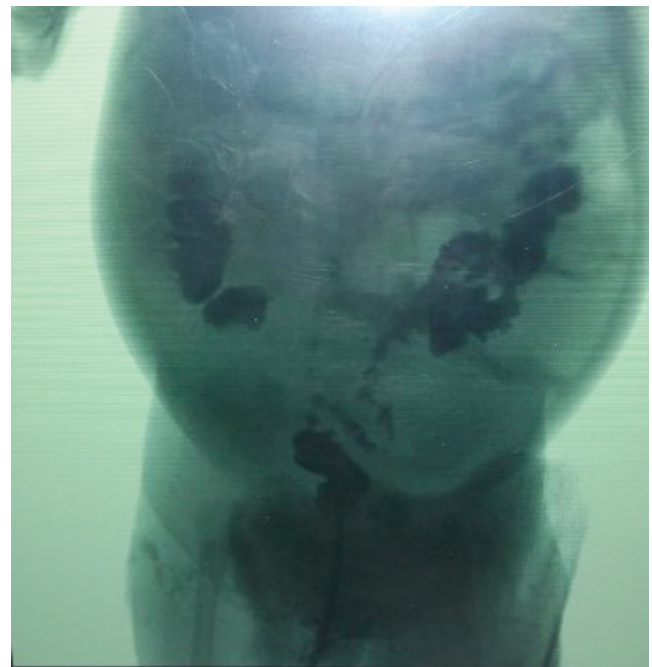


Fig 9. Abdominal radiography of a total colonic aganglionosis patient

Surgical technique for treatment of total colonic aganglionosis is shown below

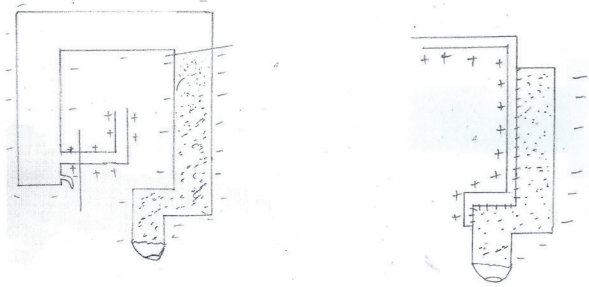


Fig 10. Martin's procedure

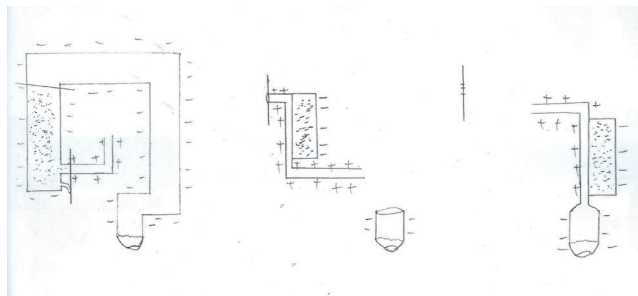


Fig 11. Kimura's procedure

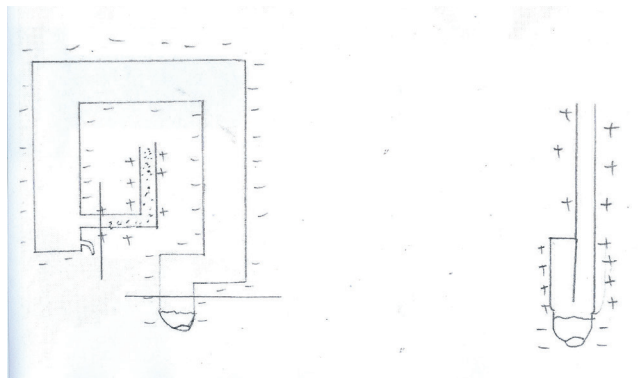


Fig 12. J-pouch procedure

Post-operative complications include gut obstruction, incontinence, and enterocolitis with the incidence 2-22.9%, 1.6-22.4%, and 0-36.4% respectively.²⁶⁻³¹ The symptoms of gut obstruction include nausea, abdominal distention, and constipation. The causes of gut obstruction include mechanical obstruction, absence of ganglion cell at the anastomotic site, motility disorder of proximal bowel, and internal sphincter achalasia.³² Mechanical obstruction caused by anastomotic stricture can be treated conservatively by anal dilatation. Refractory anastomotic stricture, presence of aganglionic bowel at anastomotic site, or presence of abnormal motility bowel should be treated by surgical resection. Botox injection can treat internal sphincter achalasia with good results.³² History of vigorous traction

of anal sphincter during surgery and absence of dentate line are important for incontinence status. Surgical repair of anal sphincter should be done in a patient with major sphincter anal injury. Medicine, behavioural and diet modification are adjunct to treat incontinence symptom. Enterocolitis can be ameliorated by scheduled rectal irrigation and topical isosorbide dinitrate.^{33,34} Parental education is important for early diagnosis and treatment of this serious condition. Treatment of enterocolitis has been discussed earlier.

CONCLUSION

Hirschsprung's disease is a congenital disease. Early diagnosis and treatment should be done to reduce life threatening complications such as enterocolitis. Many surgical methods were proposed as the treatment of this disease. However, all of these methods still had complications. Proper treatment of the complications and parental education will decrease severity of complications and improve quality of a patient's life.

REFERENCES

1. Raveenthiran V. Knowledge of ancient Hindu surgeons on Hirschsprung disease: evidence from Sushruta Samhita of circa 1200-600 BC. *J Pediatr Surg* 2011;46(11):2204-8.
2. Classic Articles in Colonic and Rectal Surgery. Constipation in the newborn as a result of dilation and hypertrophy of the colon: Harald Hirschsprung. *Jahrbuch fur Kinderheilkunde*, 1888. *Dis Colon Rectum* 1981;24(5):408-10.
3. Wallace AS, Burns AJ. Development of the enteric nervous system, smooth muscle and interstitial cells of Cajal in the human gastrointestinal tract. *Cell Tissue Res* 2005;319:16.
4. Druckenbrod NR, Epstein ML. The pattern of neural crest advance in the cecum and colon. *Dev Biol* 2005;287:9.
5. Breau MA, Dahmani A, Broders-Bondon F, Thiery JP, Dufour S. Beta 1 integrins are required for the invasion of the caecum and proximal hindgut by enteric neural crest cells. *Development* 2009;136(16):2791-801.
6. Simpson MJ LK, Hughes BD, Newgreen DF. Cell proliferation drives neural crest cell invasion of the intestine. *Dev Biol* 2007;302:16.
7. Stanchina L, Baral V, Robert F, Pingault V, Lemort N, Pachnis V, Goossens M, Bondurand N. Interactions between Sox10, Edn3 and Ednrb during enteric nervous system and melanocyte development. *Dev Biol* 2006;295:18.
8. Nishiyama C, Uesakat T, Manabe T, Yonekura Y, Nagasawa T, Newgreen DF, et al. Transmesenteric neural crest cells are the principal source of the colonic enteric nervous system. *Nat Neurosci* 2012;15:8.
9. Carrasquillo M MA, Puffenberger EG, Kashuk CS, Nouri N, Chakravarti A. Genome-wide association study and mouse model identify interaction between RET and EDNRB pathways in Hirschsprung disease. *Nat Genet* 2002;32:8.

10. Laranjeira C, Pachnis V. Enteric nervous system development: Recent progress and future challenges. *Auton Neurosci* 2009;151(1):61-9.
11. Khan AR, Vujanic GM, Huddart S. The constipated child: how likely is Hirschsprung's disease? *Pediatr Surg Int* 2003;19(6):439-42.
12. Monajemzadeh M, Kalantari M, Yaghmai B, Shekarchi R, Mahjoub F, Mehdizadeh M. Hirschsprung's Disease: a Clinical and Pathologic Study in Iranian Constipated Children. *Iran J Pediatr* 2011;21(3):362-6.
13. Lewis NA, Levitt MA, Zallen GS, Zafar MS, Iacono KL, Rossman JE, et al. Diagnosing Hirschsprung's disease: increasing the odds of a positive rectal biopsy result. *J Pediatr Surg* 2003;38(3):412-6.
14. Wang PA, Huang FY. Time of the first defaecation and urination in very low birth weight infants. *Eur J Pediatr* 1994;153(4):279-83.
15. Austin KM. The pathogenesis of Hirschsprung's disease-associated enterocolitis. *Semin Pediatr Surg* 2012;21(4):319-27.
16. Gosain A. Established and emerging concepts in Hirschsprung's-associated enterocolitis. *Pediatr Surg Int* 2016;32(4):313-20.
17. Demehri FR, Halaweish IF, Coran AG, Teitelbaum DH. Hirschsprung-associated enterocolitis: pathogenesis, treatment and prevention. *Pediatr Surg Int* 2013;29(9):873-81.
18. Imamura A, Puri P, O'Briain DS, Reen DJ. Mucosal immune defence mechanisms in enterocolitis complicating Hirschsprung's disease. *Gut* 1992;33(6):801-6.
19. Takawira C, D'Agostini S, Shenouda S, Persad R, Sergi C. Laboratory procedures update on Hirschsprung disease. *J Pediatr Gastroenterol Nutr* 2015;60(5):598-605.
20. Alehossein M, Roohi A, Pourgholami M, Mollaeian M, Salamati P. Diagnostic accuracy of radiologic scoring system for evaluation of suspicious hirschsprung disease in children. *Iran J Radiol* 2015;12(2):e12451.
21. Friedmacher F, Puri P. Rectal suction biopsy for the diagnosis of Hirschsprung's disease: a systematic review of diagnostic accuracy and complications. *Pediatr Surg Int* 2015;31(9):821-30.
22. Frykman PK, Short SS. Hirschsprung-associated enterocolitis: prevention and therapy. *Semin Pediatr Surg* 2012;21(4):328-35.
23. Chen Y, Nah SA, Laksmi NK, Ong CC, Chua JH, Jacobsen A, et al. Transanal endorectal pull-through versus transabdominal approach for Hirschsprung's disease: a systematic review and meta-analysis. *J Pediatr Surg* 2013;48(3):642-51.
24. Gosemann JH, Friedmacher F, Ure B, Lacher M. Open versus transanal pull-through for Hirschsprung disease: a systematic review of long-term outcome. *Eur J Pediatr Surg* 2013;23(2):94-102.
25. Menezes M, Pini Prato A, Jasonni V, Puri P. Long-term clinical outcome in patients with total colonic aganglionosis: a 31-year review. *J Pediatr Surg* 2008;43(9):1696-9.
26. Adiguzel U, Agengin K, Kiristioglu I, Dogruyol H. Transanal endorectal pull-through for Hirschsprung's disease: experience with 50 patients. *Ir J Med Sci* 2017;186(2):433-437.
27. Temple SSA, Langer JC. Is daily dilatation by parents necessary after surgery for Hirschsprung disease and anorectal malformations? *J Pediatr Surg* 2012;47:3.
28. Holschneider AM. Hirschsprung's disease. Stuttgart: Hippokrates Verlag GmbH; 1982.
29. Niramis R, Watanattitan S, Anuntkosol M, Buranakijcharoen V, Rattanasuwan T, Tongsin A, et al. Quality of life of patients with Hirschsprung's disease at 5 - 20 years post pull-through operations. *Eur J Pediatr Surg* 2008;18(1):38-43.
30. Bourdelat D, Vrsansky P, Pages R, Duhamel B. Duhamel operation 40 years after: a multicentric study. *Eur J Pediatr Surg* 1997;7(2):70-6.
31. Zimmer J, Tomuschat C, Puri P. Long-term results of transanal pull-through for Hirschsprung's disease: a meta-analysis. *Pediatr Surg Int* 2016;32(8):743-9.
32. Langer JC. Persistent obstructive symptoms after surgery for Hirschsprung's disease: development of a diagnostic and therapeutic algorithm. *J Pediatr Surg* 2004;39(10):1458-62.
33. Marty TL, Seo T, Sullivan JJ, Matlak ME, Black RE, Johnson DG. Rectal irrigations for the prevention of postoperative enterocolitis in Hirschsprung's disease. *J Pediatr Surg* 1995;30(5):652-4.
34. Tiryaki T, Demirbag S, Atayurt H, Cetinkursun S. Topical nitric oxide treatment after pull through operations for Hirschsprung disease. *J Pediatr Gastroenterol Nutr* 2005;40(3):390-2.