

Selective Management for Gastrointestinal Hemorrhage caused by Choledochoduodenal Fistula

Pawan Chansaenroj, M.D.^{*,**}, Stephanie Wood, M.D.^{*}, Stanley J Rogers, M.D.^{*}, John P Cello, M.D.^{***}

^{*}Department of Surgery, University of California, San Francisco, California, USA, ^{**}Department of Surgery, Somdech Phra Pinklao (Royal Thai Naval) Hospital, Thailand, ^{***}Division of Gastroenterology, Department of Medicine, University of California, San Francisco, California, USA.

ABSTRACT

Background: To report a patient of choledochoduodenal fistulae (CDF) who presented with melena and review a specific treatment for CDF.

Methods: This study was designed as a retrospective chart review using patient's clinical data, imaging, endoscopic report, treatment review, and literature review for treatment options.

Results: A 74-year-old female presented with diffuse, non-tender abdominal pain and associated melena for one week. Physical examination showed mildly icteric sclera and mild epigastric tenderness on deep palpation. Initial diagnoses included cholangitis with anemia and acute kidney injury. Computed tomography of the abdomen revealed dilated common bile duct (CBD) with a likely 1 cm stone at the distal common bile duct. The patient was given intravenous antibiotic and proper fluid administration. An ERCP was performed noting a fistula from the bile duct to the 2nd part of the duodenum with stone impaction. Sphincterotomy was performed from papilla to fistula. Balloon extraction of 1 cm stone from the CBD was done.

Conclusion: The clinical presentation of CDF is generally quite nonspecific. In this case report, we present a presentation of a patient with gastrointestinal hemorrhage as an example of the presentation of CDF associated with a CBD stone. This study also discussed recent data concerning proposed treatment of CDF.

Keywords: Choledochoduodenal fistula; choledochoenteric fistula; gastrointestinal hemorrhage (Siriraj Med J 2017;69: 97-101)

INTRODUCTION

Choledochoduodenal fistulae (CDF), abnormal connections of common bile duct (CBD) to the duodenum are uncommon complications of biliary stone disease or duodenal peptic ulcerations. Studies have reported the incidence of internal biliary fistulae to be from 0.9 - 5.3%.¹⁻⁵ Prior reports showed the most common type of biliary enteric fistulae to be cholecystoduodenal fistulae. The widespread use of endoscopic cholangio-pancreaticography (ERCP) around the world has led to the reporting of many more CDF. In recent studies, the incidence of CDF is greater than that of cholecystoduodenal fistulae.

CDF is mostly commonly caused by cholelithiasis (90%). Other less common etiologies are malignancy, peptic ulceration and iatrogenic. The clinical presentation of patients with CDF is usually nonspecific associated with epigastric or right upper quadrant abdominal pain, jaundice, or fever. Some patients are incidentally found with this condition by imaging or intervention without any symptom. Based upon our research, there have been no reports of gastrointestinal bleeding caused by a CDF.

Herein, we report a patient who presented with melena and obstructive jaundice. Upper GI endoscopic finding demonstrated hemorrhage from a choledocho-duodenal fistula without peptic ulcer. Novel treatments of CDF are reviewed in this study.

Correspondence to: Pawan Chansaenroj

E-mail: pawan.chansaenroj@ucsf.edu

Received 13/1/2017 Revised 9/3/2017 Accepted 9/3/2017

doi:10.14456/smj.2017.19

CASE REPORT

A 74-year-old female presented with diffuse, non-tender abdominal pain and associated melena for one week. She had end-stage renal disease on hemodialysis, diabetes mellitus and hypertension without the history of NSAID or alcohol consumption. Her vital signs were stable and she was afebrile. Physical examination showed mildly icteric sclera and mild epigastric tenderness on deep palpation. Laboratory investigation showed Hct 20%, WBC 13,700/mm³, PMN's 87.6%, plt 230,000 /mm³, BUN 68 mg/dl Creatinine 5 mg/dl. Liver function test noted the following: AST 131 IU/l, ALT 35 IU/l, total bilirubin 1.9 mg/dl, direct bilirubin 1 mg/dl, alkaline phosphatase 1,508 IU/l and GGT 1,491 U/l. Coagulation parameters were normal. Initial diagnoses included cholangitis with anemia and acute kidney injury. Computed tomography of the abdomen revealed the following: 1)

Dilated common bile duct (CBD) with a likely 1 cm stone at the distal common bile duct 2) Severe anasarca, ascites and small bilateral pleural effusions and 3) Liver cirrhosis. The patient was given intravenous antibiotic (Ertapenem) and proper fluid administration. Her ascites was felt to be related to a combination of nephrotic syndrome and heart failure from sepsis.

An ERCP was performed noting a fistula from the bile duct to the 2nd part of the duodenum with stone impaction. There was some limited bleeding from the area of the CDF. (Fig 1) Sphincterotomy was performed from papilla to fistula. Balloon extraction of 1 cm stone from the CBD was done. Cholangiogram showed mild dilatation of CBD and common hepatic duct. (Fig 2) There was no peptic ulceration in the area or duodenitis. After the procedure, this patient recovered and was discharged in the following week.

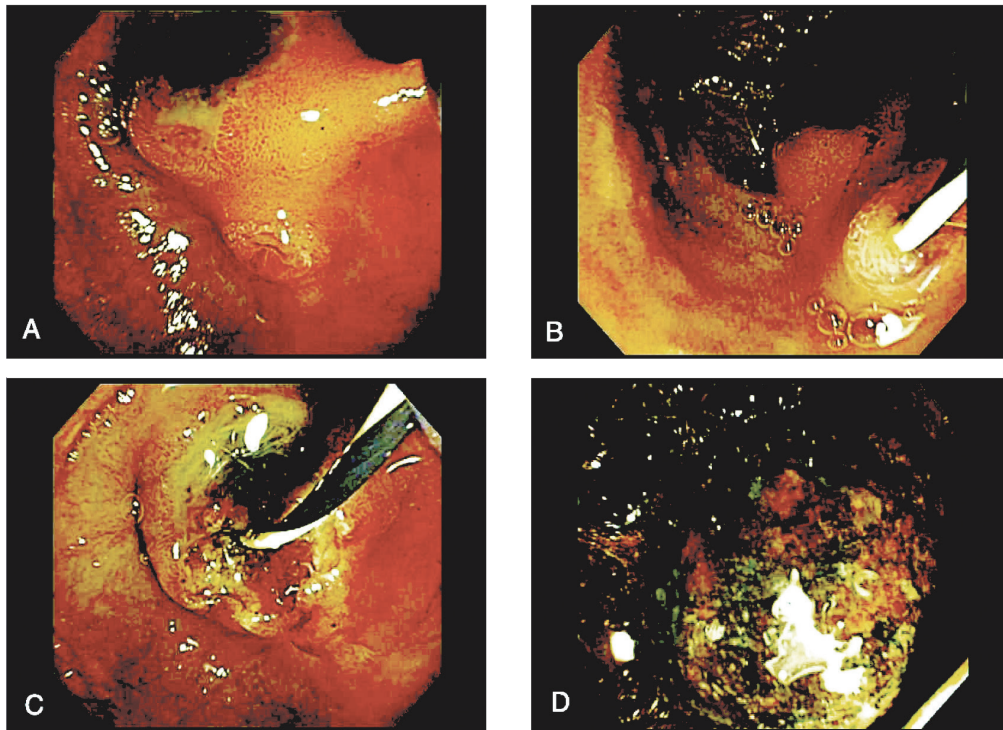


Fig 1. A) Papilla with CDF impacted with CBD stone B) After cannulation via papilla with guide wire C) Following endoscopic sphincterotomy going from the papilla to CDF D) Stone extracted from bile duct following sphincterotomy.




Fig 2. Cholangiogram showed dilated common bile duct and intrahepatic ducts

DISCUSSION

CDF are uncommonly diagnosed. The incidence has been increasing after worldwide use of duodenoscopy for endoscopic retrograde cholangiopancreatography.

The clinical manifestations of CDF are often non-specific. Patients usually present with symptoms of cholangitis (abdominal pain, fever, and jaundice) or others GI symptoms such as nausea/vomiting, anorexia, abdominal distension, etc.⁴ Presentations usually depend on etiology of CDF. If CDF is caused by a gallstone,

patients often present with clinical signs of obstructive jaundice or cholangitis. Patients with CDF related to a duodenal ulcer, usually present with ulcer symptoms or with gastrointestinal bleeding.⁶ Patients with neoplasms causing CDF usually present with anorexia or obstructive symptoms.⁷ Wu et al.⁵ reported review of CDF studies in China from 1983-2014. Seven hundred twenty-eight cases of CDF, from 48 studies, most of them presented with epigastric pain (80.91%), and more than half of the patients are expected to experience jaundice (54.26%) and fever (50.69%). None of them present with gastrointestinal bleeding. There are relatively few case reports of CDF patients who presented with melena.^{5,8} All of them had CDF from duodenal ulcer.

Most of CDF are caused by cholelithiasis, followed in frequency by malignancy and peptic ulcer disease.³⁻⁵ CDF could also be the sequel of some procedure e.g., post bile duct stent placement⁹⁻¹¹, laparoscopic cholecystectomy with bile duct injury¹², bile duct exploration¹³, etc. One study reported a CDF following a TACE procedure.¹⁴ Unusual causes of CDF include tuberculosis^{15,16} or post liver transplantation.¹⁷

There are many classifications of CDF. (Fig 3) The Ikeda classification¹⁸ includes 2 types of CDF. Type 1 (distal type) is a CDF which presented on the longitudinal fold of the papilla. Type 2 (proximal type) is a CDF which presented on the posterior wall of the duodenal

bulb. Gong's classification⁴ notes 3 distinct types of CDF. Type A is a CDF which opening presented greater than 2 cm from papilla. Type B is a CDF which opening presented within 2 cm from papilla. And type C is a CDF which opening presented on the papillary fold (peripapillary CDF).

Treatment options for choledochoduodenal fistulae are challenging. In symptomatic patients, treatment of CDF is mandatory with the treatment options related to etiology, presentation, and location of the fistula.

Most CDF caused by cholelithiasis present with symptoms or signs of cholangitis. Many studies suggest that if the fistula is adjacent to papilla, an endoscopic sphincterotomy (EST) is the best option for treatment.^{1,3,5} Shao et al.²¹ reported the comparison of endoscopic papillary balloon dilatation (EPBD) with conventional EST for peripapillary CDF with bile duct stones. This study showed patients who performed EPBD had the significantly lower percentage of bleeding, but the same in pancreatitis compare with EST.

If CDF size is more than 1 cm or CDF presented greater than 2 cm from the papilla, treatment options are more controversial. Some studies suggested doing bypass operation (eg.cholechojejunostomy) when the CBD diameter is more than 2 cm.^{4,22} Treatment of asymptomatic CDF is more controversial. Because CDF will allow reflux of debris into the common duct, ascending cholangitis may occur.^{24,25} Li et al.²² reported that CDF size larger than 1 cm increased the risk of ascending cholangitis and thus proposed the need for surgical treatment. On the other hand, Ohtsuka et al.²⁶ suggested that perform sphincterotomy in asymptomatic fistulae may increase the risk of cholangitis without benefit. All patients who have CDF causing from cholelithiasis, should however undergo cholecystectomy to prevent the recurrent of common bile duct stone.

With malignancy associated obstructive jaundice, drainage procedure should be done. For example, Jayakrisma et al.²⁷ presented a case of CDF patient who could not be pass stent via papilla, that could be inserted stent via CDF.

We illustrate proposed guidelines for the treatment for CDF according to aforementioned review. (Fig 4)

CONCLUSION

The clinical presentation of CDF is generally quite nonspecific. In this case report, we present a presentation of a patient with gastrointestinal hemorrhage as an example of the presentation of CDF associated with a CBD stone. This study also discussed recent data concerning proposed treatment of CDF.

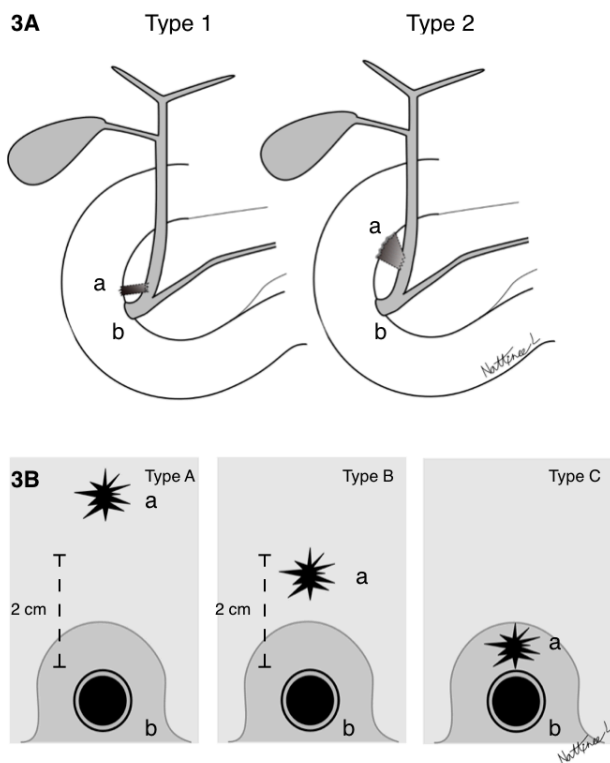


Fig 3. Classification of CDF. **3A)** Ikeda's classification Type 1 and Type 2. **3B)** Gong's classification Type A,B, and C. a: CDF, b: papilla.

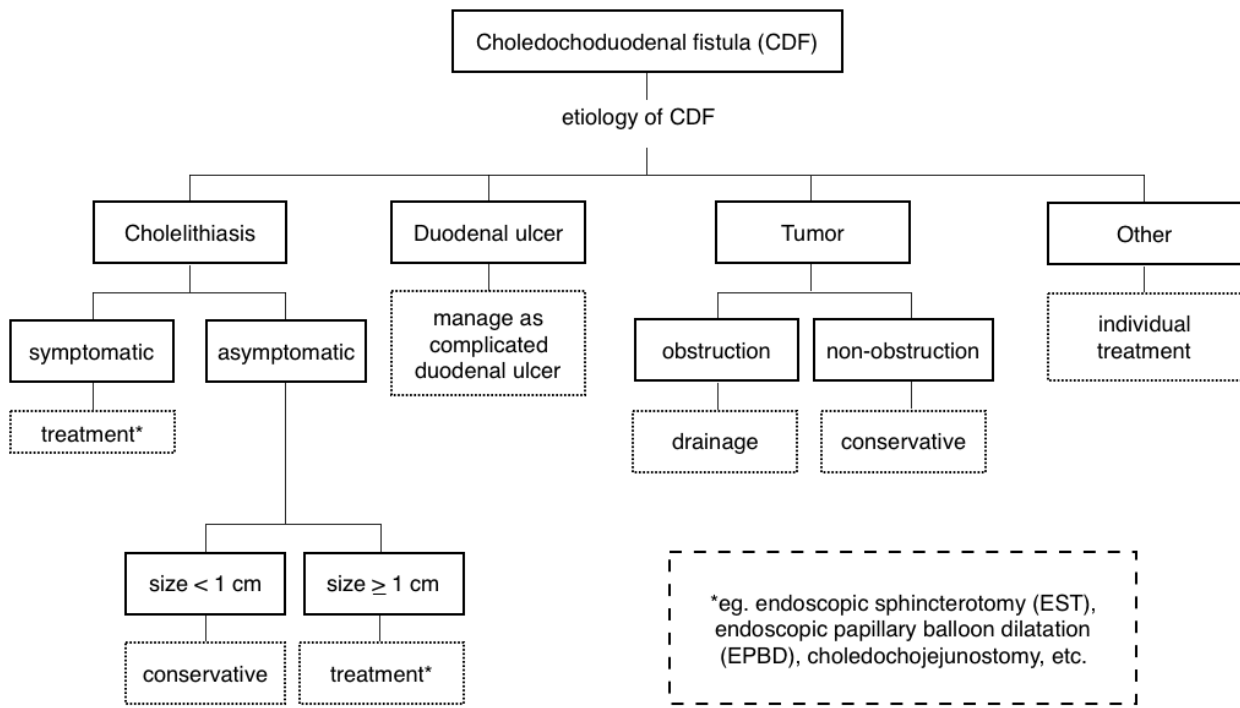


Fig 4. Guideline for treatment CDF

ACKNOWLEDGMENTS

The authors thank Nattinee Leelakanok, M.D. Faculty of Medicine, Chulalongkorn University and King Chulalongkorn Memorial Hospital, Thai Red Cross Society, for her assistance in illustration.

REFERENCES

- Zwemer FL, Coffin-Kwart VE, Conway MJ. Biliary enteric fistulas. Management of 47 cases in native Americans. *Am J Surg* 1979;138(2):301-4.
- Glenn F, Reed C, Grafe WR. Biliary enteric fistula. *Surg Gynecol Obstet* 1981;153(4):527-31.
- Yamashita H, Chijiwa K, Ogawa Y, Kuroki S, Tanaka M. The internal biliary fistula--reappraisal of incidence, type, diagnosis and management of 33 consecutive cases. *HPB Surg* 1997;10(3): 143-7.
- Zong KC, You HB, Gong JP, Tu B. Diagnosis and management of choledochoduodenal fistula. *Am Surg* 2011;77(3):348-50.
- WuMB, Zhang WF, Zhang YL, MuD, GongJP. Choledochoduodenal fistula in Mainland China: a review of epidemiology, etiology, diagnosis and management. *Ann Surg Treat Res* 2015;89(5):240-6.
- Constant E, Turcotte JG. Choledochoduodenal fistula: the natural history and management of an unusual complication of peptic ulcer disease. *Ann Surg* 1968;167(2):220-8.
- Imaeda K, Katagiri K, Ando T, Tokunaga H, Miyamoto T, Ide M, et al. Multiple parapapillary choledochoduodenal fistulas with ampullary carcinoma. *Hepatogastroenterology* 1998;45(24): 2097-100.
- Hutchings VZ, Puestow CB, Wheller JR. Choledochoduodenal fistula complicating duodenal ulcer; a report of five cases and review of the literature. *AMA Arch Surg* 1956;73(4):598-605.
- Lee TH, Park SH, Kim SP, Lee SH, Lee CK, Chung IK, et al. Spontaneous choledochoduodenal fistula after metallic biliary stent placement in a patient with ampulla of Vater carcinoma. *Gut Liver* 2009;3(4):360-3.
- Williamson JB, Draganov PV. Choledochoduodenal fistula after biliary metallic stent placement for pancreatic cancer. *Dig Endosc* 2014;26(2):292.
- Masuda D, Ogura T, Imoto A, Onda S, Sano T, Takagi W, et al. Choledochoduodenal Fistula after the Placement of a Partially Covered Metal Stent for Unresectable Pancreatic Cancer. *Intern Med* 2016;55(12):1591-7.
- Yilmaz S, Akici M, Okur N, Turel S, Ersen O, Sahin E. Spontaneous postoperative choledochoduodenal fistula due to bile duct injury following laparoscopic cholecystectomy. *Int J Surg Case Rep* 2016;25:199-202.
- Ghahremani GG, Crampton AR, Bernstein JR, Caprini JA. Iatrogenic biliary tract complications: radiologic features and clinical significance. *Radiographics* 1991;11(3):441-56.
- Prachayakul V, Aswakul P. Spontaneous hepaticoduodenal and choledochoduodenal fistula mimicking duodenal ulcer perforation, a very rare complication of transarterial chemoembolization. *Case Rep Gastroenterol* 2015;9(1):68-73.
- Chaudhary A, Bhan A, Malik N, Dilawari JB, Khanna SK. Choledocho-duodenal fistula due to tuberculosis. *Indian J Gastroenterol* 1989;8(4):293-4.
- Miyamoto S, Furuse J, Maru Y, Tajiri H, Muto M, Yoshino M. Duodenal tuberculosis with a choledocho-duodenal fistula. *J Gastroenterol Hepatol* 2001;16(2):235-8.

17. Werner CR, Lauer UM, Berg CP, Kaiser S, Ludescher B, Luz O, et al. Choledochoduodenal fistula after liver transplantation. *Liver Transpl* 2007;13(11):1608-10.
18. Ikeda S, Okada Y. Classification of choledochoduodenal fistula diagnosed by duodenal fiberoscopy and its etiological significance. *Gastroenterology* 1975;69(1):130-7.
19. Jaballah S, Sabri Y, Karim S. Choledochoduodenal fistula due to duodenal peptic ulcer. *Dig Dis Sci* 2001;46(11):2475-9.
20. Povoski S, Shamma'a J. Fistula involving portal vein and duodenum at the site of a duodenal ulcer in a patient after previous extrahepatic bile duct resection and brachytherapy. *Dig Surg* 2003;20(1):53-5.
21. Shao D, Chen JP. Comparison of endoscopic papillary balloon dilatation with conventional endoscopic sphincterotomy for peripapillary choledochoduodenal fistula with bile duct stones. *Int J Clin Exp Med* 2015;8(5):8025-8.
22. Li ZH, Ding J, Ye Y, Cai L, Liu X, Liu J, et al. New strategy to prevent ascending cholangitis in larger choledochoduodenal fistula. *ANZ J Surg* 2006;76(9):796-800.
23. Neumann H, Nagel A, Bernatik T, Wickles N, Neurath MF, Raithel M. Endoscopic closure of large, spontaneous, choledochoduodenal fistula by using an over-the-scope clip. *Gastrointest Endosc* 2011;74(1):200-2.
24. Choi D, Lim HK, Kim MJ, Kim SJ, Kim SH, Lee WJ, et al. Liver abscess after percutaneous radiofrequency ablation for hepatocellular carcinomas: frequency and risk factors. *AJR Am J Roentgenol* 2005;184(6):1860-7.
25. Duman L, Savas C, Aktas AR, Akcam M. Choledochoduodenal fistula: An unusual cause of recurrent cholangitis in children. *J Indian Assoc Pediatr Surg*. 2014 Jul;19(3):172-4.
26. Ohtsuka T, Tanaka M, Inoue K, Nabae T, Takahata S, Yokohata K, et al. Is peripapillary choledochoduodenal fistula an indication for endoscopic sphincterotomy? *Gastrointest Endosc* 2001;53(3):313-7.
27. Chintanaboina J, Mathew A, Moyer MT. Taking an Alternate Route Home: Stenting of Choledochoduodenal Fistula. *ACG Case Rep J* 2015;2(2):104-6.