

Management of Central Venous Catheter-Related Thrombosis When Causes Superior Vena Cava Syndrome in a Case with Metastatic Breast Cancer: A Case Report

Mohammad Esmail Hejazi¹, Sepideh Tahsini Tekantapeh²✉ and Forugh Ghasemi³

¹Tuberculosis and Lung Disease Research Center, Internal Medicine Department of Imam Reza Hospital, Associated professor in pulmonology, Tabriz University of Medical Science, Tabriz, Islamic Republic of Iran

²Tuberculosis and Lung Disease Research Center, Internal Medicine Department of Imam Reza Hospital, internal medicine resident, Tabriz University of Medical Science, Tabriz, Islamic Republic of Iran

³Internal Medicine Department of Imam Reza Hospital, internal medicine resident, Tabriz University of Medical Science, Tabriz, Islamic Republic of Iran

✉ Corresponding author's E-mail: tahsinis@tbzmed.ac.ir

ABSTRACT: Today there is an increase in the use of central venous catheters in clinical practice. One of the dangerous complications of central venous catheters is symptomatic or asymptomatic thrombosis which sometimes causes superior vena cava syndrome. One of the most common causes of superior vena cava syndrome is malignant mass compression effect, also sometimes happens because of post thrombotic syndrome of central venous catheters. A 65 year-old woman was admitted to Imam Reza Hospital, Tabriz, Iran with superior vena cava syndrome. CT-Angiography demonstrated a massive filling defect in distal of superior vena cava adjacent to central venous catheters in favor of central venous catheters thrombosis. Central venous catheter-related thrombosis was successfully treated with therapeutic anticoagulation and catheter removal. As a conclusion, when central venous catheter-related thrombosis causes superior vena cava syndrome, despite the lack of consensus, therapeutic anticoagulation along with catheter removal are introduced as a successful way in central venous catheter-related thrombosis management. Based on the existing data found in previous studies about patients with central venous catheters, it can be claimed that a strong association exists between central venous catheter-related thrombosis presentation as a superior vena cava syndrome and malignancies. In patients with central venous catheter-related thrombosis who are presented with superior vena cava syndrome, successful clinical improvement is obtained by therapeutic anticoagulation along with catheter removal.

Keywords: Anticoagulation, Catheter removal, Central venous catheter, Post thrombotic syndrome, Thrombosis

CASE REPORT
Pii: S2322-47891700004-7
Received 06 Feb. 2017
Accepted 01 Mar. 2017

INTRODUCTION

The use of Central Venous Catheters (CVC) increase every day in order to facilitate chemotherapies and parenteral nutrition (Monreal and Davant, 2001). CVCs are used in solid cancers and hematologic disorders. CVC complications include its tip thrombosis and central venous Catheter-Related Thrombosis (CRT) as a result of long-term use (Bona, 1999 and Venturini et al., 2012). Relation between thrombosis occurrence and malignancies is well-known (Watson et al., 2015). Port-A-Cath (PAC)-related thrombosis is common in children with malignancies that causes post thrombotic syndromes such as Superior Vena Cava (SVC) syndrome (Albisetti et al., 2013). Severity of SVC syndrome symptoms depends on severity of stenosis caused by clot or thrombosis (Danjoux et al., 2015). CRT

is asymptomatic and it's reported only in 2-4% of patients with CVCs (Lagro et al., 2000). CRT happens in 41% of patients with CVC and only 33% of these CRTs are symptomatic. Most CRTs occur within the first 30 days after catheter insertion. 15-30% of CRTs can cause post thrombotic syndrome and 11% lead to Pulmonary Thromboembolism (PTE) which half of them are symptomatic (Kuter, 2004). Thrombophilic disorders, factor V Leiden mutation, thrombogenic material of catheter, large catheter diameter and left sided placement could increase CRT incidence risk (Linenberger, 2006). CRT clinical presentation as a classic SVC syndrome includes arms and face swelling, stridor, blurred vision, dyspnea, dizziness, positional headache, retro-orbital pain, dysphasia and chest pain. SVC syndrome is usually diagnosed in the setting of malignancy (60-85%).

CASE REPORT

The patient was a 65 year-old woman who had suffered from metastatic breast cancer as well as massive metastases in lumbar spine for 8 years. Chemotherapies were performed through CVC and the last course was administered two weeks before admission. The patient was admitted because of face inflation, neck and upper limbs swelling and flushing, sudden dyspnea in function class IV, palpitation, respiratory distress, tachypnea and hypoxemia (O₂ sat= %85). Face swelling and dyspnea were deteriorated and stabilized while lying down and sitting up

respectively. Massive filling defect in distal of SVC was seen in CT- Angiography (Figure 1). Due to decreased congestion and overload in SVC syndrome, diuretic therapy was started. Corticosteroids were prescribed to decrease airway edema and improve respiratory distress. In order to treat thrombosis, anti-coagulation therapy with Heparin within the therapeutic dose (80 units/kg bolus, followed by 18 units/kg per hour) was started and the CVC was removed (Figure 2). SVC syndrome signs and symptoms were improved after 10 days and the patient was discharged.

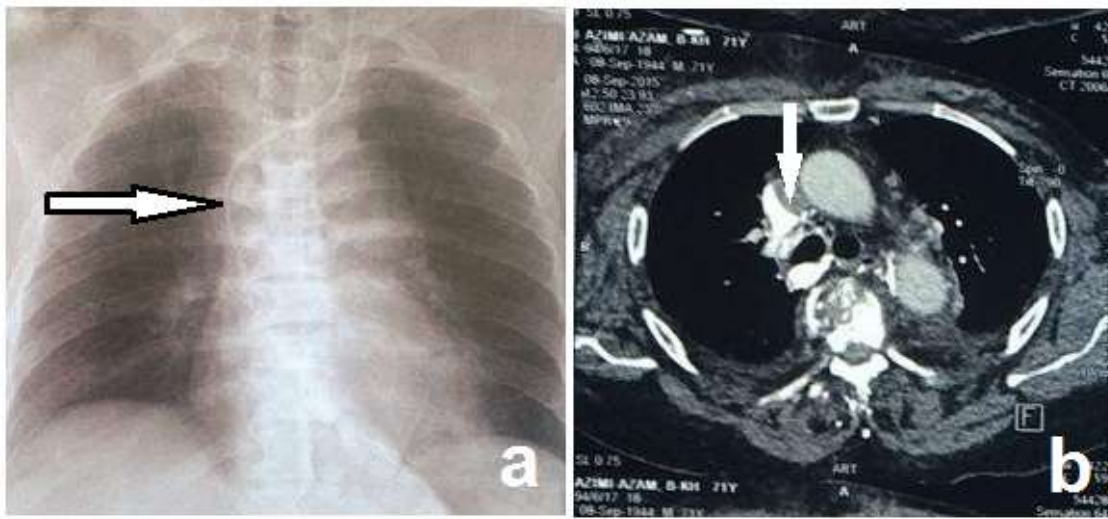


Figure 1. a) CVC is seen in chest-X-ray that was inserted from left side. b) A crescent filling defect in SVC was seen in CT- Angiography adjacent to CVC in favor of CRT.

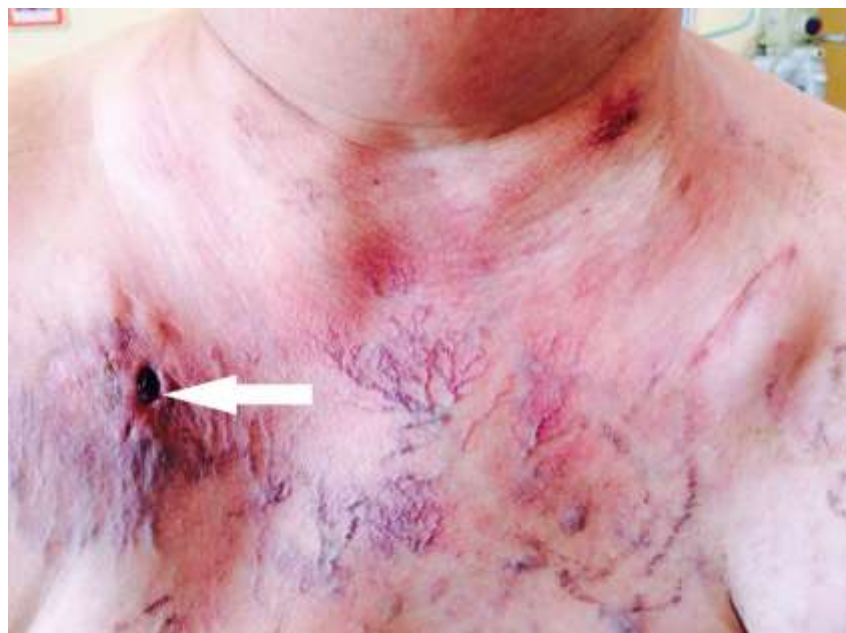

Figure 2. CVC exit site in CRT treatment in addition to anticoagulation in a 65 year old woman with breast cancer.

RESULTS AND DISCUSSION

Several treatments have been introduced for SVC syndrome depending on the underlying disease. In the case of patients with malignancy, anti-coagulation, thrombolytic drugs and endovascular treatments should be considered in CVC induced SVC syndrome. Therapeutic anticoagulation and catheter removal can help clot thrombolysis (Linenberger, 2006). Prophylactic anticoagulation for CVC is not recommended (Debourdeau et al., 2013; Giordano et al., 2015). However, Giordano et al. (2015) recommended thrombo-prophylaxis with Low Molecular Weight Heparin (LMWH) in patients with Acute Lymphoblastic Leukemia (ALL) and lymphomas who were treated with prednisolone, E. coli-asparaginase, and patients with a positive history of inherited thrombophilia, in thoracic or mediastinal mass. Lagro et al. (2000) findings demonstrated no effect of prophylactic nadroparin on CRT incidence in bone marrow transplant recipients. There is no consensus about priority of catheter removal or thrombolytic drugs and anticoagulation in CRT management. Anticoagulation with LMWH for 3 months was recommended for symptomatic CRT (Debourdeau et al., 2013). Based on the existing data found in previous studies about patients with CVC, there is strong evidence between CRT presentations as a SVC Syndrome in malignancies. In patients with CRT who are presented with SVC Syndrome, successful clinical improvement with therapeutic anticoagulation along with catheter removal will be obtained.

Competing interests

The authors have stated explicitly that there are no conflicts of interest in connection with this article.

Authors' contribution

MEH contributed in the design of the study and presenting this case report, STT and FG wrote the paper and collected patient data. All authors have read and approved the manuscript.

REFERENCES

- Albisetti M, Kellenberger CJ, Bergsträsser E, Niggli F, Kroiss S, Rizzi M, et al. (2013). Port-a-cath-related thrombosis and postthrombotic syndrome in pediatric oncology patients. *The Journal of Pediatrics*, 163(5): 1340-1346.
- Bona RD (1999). Thrombotic complications of central venous catheters in cancer patients. *Seminars in Thrombosis and Hemostasis*, 25(2):147-155.
- Danjoux C, Tsao M, Barnes E and Chow E (2015). Superior vena cava syndrome. *Journal of Pain Management*, 8(4): 283.
- Debourdeau P, Farge D, Beckers M, Baglin C, Bauersachs RM, Brenner B, et al. (2013). International clinical practice guidelines for the treatment and prophylaxis of thrombosis associated with central venous catheters in patients with cancer. *Journal of Thrombosis and Haemostasis*, 11(1): 71-80.
- Giordano P, Saracco P, Grassi M, Luciani M, Banov L, Carraro F, et al. (2015). Recommendations for the use of long-term central venous catheter (CVC) in children with hematological disorders: management of CVC-related occlusion and CVC-related thrombosis. On behalf of the coagulation defects working group and the supportive therapy working group of the Italian Association of Pediatric Hematology and Oncology (AIEOP). *Annals of Hematology*, 94(11): 1765-1776.
- Kuter DJ (2004). Thrombotic complications of central venous catheters in cancer patients. *Oncologist*, 9(2):207-216.
- Lagro SW, Verdonck LF, BorelRinkes IH and Dekker AW (2000). No effect of nadroparin prophylaxis in the prevention of central venous catheter (CVC)-associated thrombosis in bone marrow transplant recipients. *Bone Marrow Transplant*, 26(10): 1103-1106.
- Linenberger ML (2006). Catheter-related thrombosis: risks, diagnosis, and management. *Journal of the National Comprehensive Cancer Network*, 4(9): 889-901.
- Monreal M and Davant E (2001). Thrombotic complications of central venous catheters in cancer patients. *ActaHaematologica*, 106(1-2): 69-72.
- Venturini E, Becuzzi L and Magni L (2012). Catheter-induced thrombosis of the superior vena cava. *Case Reports in Vascular Medicine*, 2012, 469619.
- Watson HG, Keeling DM, Laffan M, Tait RC and Makris M (2015). Guideline on aspects of cancer-related venous thrombosis. *British journal of haematology*, 170(5):640-648.