



## Therapeutic uterine artery embolization in a life-threatening postpartum hemorrhage: a case report

Leila Pourali (MD)<sup>1</sup>, Sedigheh Ayati (MD)\*<sup>1</sup>, Masoud Pezeshkirad (MD)<sup>2</sup>, Mansooreh Sadat Golmohammadi (MD)<sup>1</sup>

<sup>1</sup>Department of Obstetrics and Gynecology, Women's Health Research Center, School of Medicine, Mashhad University of Medical Sciences, Mashhad, Iran.

<sup>2</sup>Department of Radiology, Faculty of Medicine, Mashhad University of Medical Sciences, Mashhad, Iran.

### ARTICLE INFO

### ABSTRACT

#### Article type

Case report

#### Article history

Received: 17 Jan 2017

Revised: 5 Feb 2017

Accepted: 12 Feb 2017

#### Keywords

Angiography

Postpartum hemorrhage

Uterine artery embolization

Postpartum hemorrhage (PPH) is one of the most common complications of delivery and is a major cause of maternal morbidity and mortality. The aim of this report is to introduce a case of therapeutic uterine artery embolization (UAE) in a life-threatening postpartum hemorrhage.

A 26-year old G3P3 woman with severe postpartum hemorrhage after 50 days of delivery referred to the emergency unit of an academic hospital of Mashhad University of Medical Sciences, Iran with third episode of vaginal bleeding. Gynecological examination and sonography were completely normal. Hypovolemic shock that was managed by fluid and blood replacement-therapy with uterotonic medical agents including oxytocin infusion (40 unit/lit), injection of 0.2 mg methyl-ergonovin and 1000 µg rectal misoprostol. Uterine artery embolization was planned due to unremitting severe hemorrhage. Embolization resulted in successful control of hemorrhage and the patient was discharged. At 6 months follow-up, no adverse events pertinent to embolization were noted. Therefore, UAE is suggested as a useful method for controlling intractable bleeding due to postpartum hemorrhage.

Please cite this paper as:

Pourali A, Ayati S, Pezeshkirad M, Golmohammadi MS. Therapeutic uterine artery embolization in a life-threatening postpartum hemorrhage: a case report. *Rev Clin Med.* 2017;4(3):140-142.

### Introduction

Postpartum hemorrhage (PPH) is one of the most common complications of delivery. It is one of the most important causes of maternal morbidity and mortality. PPH may occur early within the first 24 hour of delivery or late between 24 h and 12 weeks after delivery. PPH is defined when hemorrhage is greater than 500 cc after normal vaginal delivery and more than 1000 cc after cesarean delivery (1). The frequency of PPH and atonic PPH rose from 1.5% and 1% in 1999 to 4.1% and 3.4% in 2009, respectively. The risk of PPH due to pla-

cental adhesive disorder was much higher (2).

The cause of PPH must be identified and controlled rapidly because it is a life-threatening situation. In the case of failure of conservative treatment, the surgeon should perform a surgical or endovascular treatment for the control of this critical state. Late PPH occurs in 1-3 % of deliveries. The most common risk factors of this pathology are endometritis, retained of placental fragments, subinvolution of placental site, and vascular abnormalities such as arterial aneurysm, pseudoan-

\*Corresponding author: Sedigheh Ayati.

Department of Obstetrics and Gynecology, Womens Health Research Center, School of Medicine, Mashhad University of Medical Sciences, Mashhad, Iran.

E-mail: ayatis@mums.ac.ir

Tel: 09151153768

This is an Open Access article distributed under the terms of the Creative Commons Attribution License (<http://creativecommons.org/licenses/by/3.0>), which permits unrestricted use, distribution, and reproduction in any medium, provided the original work is properly cited.

eurysm, and arteriovenous malformations (3).

It is believed that uterine artery embolization (UAE) is a useful method for the management of PPH. The success rate of embolization is 83-96% and complication rate is about 6-9% (4).

Anatomic variation of the uterine vasculature seems to be a common cause of embolization failure. Moreover, hemostatic disorder and primiparity are the risk factors for failure of UAE for PPH. In the case of failure of UAE, hysterectomy should be considered. Also, UAE is a useful therapeutic option after failure of conservative management for 30 min (5).

We report a case of therapeutic UAE in a life-threatening PPH.

### Case report

A 26 year old G3P3 woman (3 previous Cesarean section (C/S)) with severe PPH after 50 days of delivery referred to emergency unit of an academic hospital of Mashhad University of Medical Sciences, Iran in 2014. The first episode of vaginal bleeding occurred 3 weeks after elective cesarean because of previous C/S that she had been admitted to another hospital. Gynecological examination and sonography were completely normal. She was conservatively managed (hydration with infusion of normal saline and oxytocin) and discharged after control of vaginal bleeding.

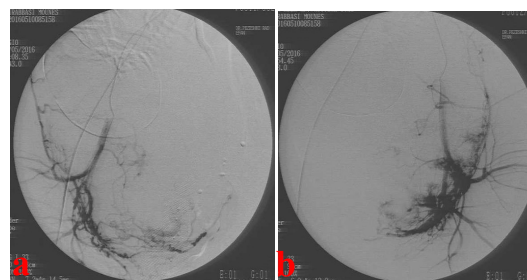
The second episode of severe and massive bleeding occurred 2 weeks after the first episode. So, she was admitted to another hospital and again she was conservatively treated. Uterotonic agents and 3 units of packed red blood cells (RBC) were transfused. Ultrasonography was normal.

The third episode of severe hemorrhage occurred 50 days after cesarean. She referred to emergency unit of Ghaem Hospital, an academic hospital of Mashhad University of Medical Sciences. The average blood loss was estimated about 3 to 4 liters. She was admitted in hypovolemic shock state. She was very pale, confused and sweaty. Initial evaluation of vital sign revealed blood pressure of 90/60 mmHg, pulse rate of 115 beats/min and respiratory rate of 40 beats/min. In bimanual vaginal examination, the uterus was mildly enlarged (about 10 weeks of gestation). Cervical os was open (two fingers dilated) and there was blood clot in cervical canal. The abdominal examination was normal.

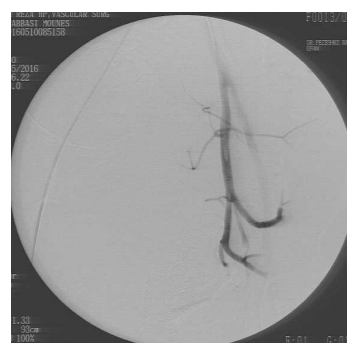At presentation, the hematocrit was 23.7%, hemoglobin was 7.1 g/dl and platelet count was 237000/ $\mu$ l. Hypovolemic shock was managed by fluid replacement (2 liters of ringer lactate solution) and uterotonic medical agents such as oxytocin infusion (40 unit/lit), injection of 0.2 mg methyl-ergonovin and 1000  $\mu$ g rectal misopros-

tol. She received 4 units of packed RBC as well. Then, she was assessed again by trans-abdominal ultrasonography for retained placenta tissue that revealed no residual tissue.

She referred to the interventional radiology department and informed consent was taken. After sterile preparation of the groin, the patient underwent bilateral femoral artery catheterization with sedation and local anesthesia. The basic arterial anatomies and pathologic pin point was demonstrated and then treatment was planned. Angiography revealed engorgement and tortuosity and blush in left uterine artery. At first, polyvinyl alcohol (PVA), a permanent embolic material, was used, then Gelfoam was used for complete left uterine artery embolization. Complete embolization of the uterine arteries was confirmed on angiography via femoral artery. It showed elimination of the aneurism (Fig 1,2).



**Figure 1 (a,b).** Digital angiography of right and left iliac arteries before embolization; it shows abnormal vasculature.



**Figure 2.** Digital angiography of left iliac artery after artery embolization showed elimination of vascular abnormality.

After UAE, vaginal examination was performed by gynecologists to confirm control of bleeding. She was discharged 3 days after UAE procedure. At 6 months follow-up, she had regular menstruation without any symptoms of severe vaginal bleeding.

## Discussion

We believe that selective UAE is an effective and safe method to control late onset PPH. It should be considered as the first choice of treatment when interventional radiologists are available. Traditionally, ligation of internal iliac had been performed for severe hemorrhage wherein the success rate was 66 %. It was not a suitable method to occlude collateral circulation of pelvis (6).

Angiographic findings in PPH patients reported by Hong and colleagues showed hyperemia with engorged, tortuous uterine artery, extravasation of contrast media, and hypervascular placental site that were similar to our angiographic findings. They also reported that angiography is the standard method for recognition of vascular abnormalities and may help to definitive treatment by embolization (7).

Vedantham et al. reported common complications such as fever, pelvic infection, groin hematoma, ischemic attack for lower organs after UAE (8). Fortunately, our patient did not have any of the above complications.

In the study of Tropeano et al., following uterine artery embolization, the patient had amenorrhea, while it did not happen in our patient that it may be due to lower age of our patient and also suitable technique of angiography and embolization (9). In the study performed in 2011 during 4 years, 9 cases of UAE were evaluated for treatment of PPH and normal menstruation was occurred during several weeks for all cases (similar to the current case) (10).

The angiographic results of our study were similar to the study of Hong et al. (6). In the present case, there was no need for repeating UAE because bleeding rate was decreased and then hemorrhage was stopped. According to the study performed in 2012 evaluating the predictive

factors of UAE failure during 10 years, the risk factors predicting UAE failure were the presence of anatomic malformations in uterine artery, coagulation disorders and primiparity (5). None of these factors were reported for our case.

## Conclusion

UAE is a useful method for controlling intractable bleeding due to postpartum hemorrhage.

## Conflict of Interest

The authors declare no conflict of interest.

## References

1. Cunningham FG, Leveno KJ, Bloom SL, et al. Williams Obstetrics. 24th ed. Mc Graw Hill. 2014.
2. Radon C, Divers M. Increasing trends in atonic postpartum haemorrhage in Ireland: an 11-year population-based cohort study. *BJOG*. 2012;119:1149-1150.
3. Marnela K, Sonographic diagnosis of postpartum pseudoaneurysms of the uterine artery: a report of 2 cases. *J Clin Ultrasound*. 2010;38:205-208.
4. Society of Obstetricians and Gynaecologists of Canada. SOGC clinical practice guidelines. Uterine fibroid embolization (UFE). Number 150, October 2004. *Int J Gynaecol Obstet*. 2005;89:305-318.
5. Bros S, Chabrot P, Kastler A, et al. Recurrent bleeding within 24 hours after uterine artery embolization for severe postpartum hemorrhage: are there predictive factors? *Cardiovasc Intervent Radiol*. 2012;35:508-514.
6. Carrillo TC. Uterine Artery Embolization in the Management of Symptomatic Uterine Fibroids: An Overview of Complications and Follow-up. *Semin Intervent Radiol*. 2008;25:378-386.
7. Hong TM, Tseng HS, Lee RC, et al. Uterine artery embolization: an effective treatment for intractable obstetric haemorrhage. *Clin Radiol*. 2004;59:96-101.
8. Vedantham S, Goodwin SC, McLucas B, et al. Uterine artery embolization: an underused method of controlling pelvic hemorrhage. *Am J Obstet Gynecol*. 1997;176:938-948.
9. Tropeano G, Permanent amenorrhea associated with endometrial atrophy after uterine artery embolization for symptomatic uterine fibroids. *Fertil Steril*. 2003;79:132-135.
10. Horng HC, Hu WM, Tseng HS, et al. Uterine arterial embolization in the management of severe post-partum hemorrhage: a successful rescue method to avoid peripartum hysterectomy. *J Chin Med Assoc*. 2011;74:255-258.