



# Prognostic value of magnetic resonance spectroscopy in patients with diffuse axonal injury: a systematic literature review

Ali Shamsa (MD)

Department of Neurosurgery, Ghaem Hospital, School of Medicine, Mashhad University of Medical Sciences, Mashhad, Iran.

### ARTICLE INFO

#### Article type

Systematic review article

#### Article history

Received: 22 Jun 2015

Revised: 6 Jul 2015

Accepted: 28 Jul 2015

#### Keywords

Brain metabolite

Diffuse axonal injury

Prognosis

Traumatic brain injury

### ABSTRACT

**Introduction:** Magnetic resonance spectroscopy (MRS) is an imaging technique that provides spectroscopic information about changes in biological markers. Studies suggest that MRS can be helpful in determining the prognosis of patients with diffuse axonal injury (DAI).

**Methods:** The PubMed and Scopus databases were systematically searched in June 2015 using following search strategy: ("Magnetic resonance spectroscopy" OR MRS OR "MR spectroscopy") AND [("Diffuse axonal injury" OR DAI] AND Prognosis) to find relevant articles in which the prognostic value of MRS had been investigated in patients with traumatic DAI. All relevant information was extracted from the identified articles and used to synthesize the data for the purpose of this study.

**Result:** In total, 19 articles were found in PubMed and 151 in Scopus. Of these, eight documents were selected for further data extraction following the application of the inclusion/exclusion criteria. The total number of patients who participated in the research studies described in the selected documents was 197. All of the selected documents showed that MRS can be used to quantitatively assess metabolite changes in patients with DAI.

**Discussion:** The results of the studies indicate that MRS imaging as a sensitive method can quantitatively determine even small variations in metabolites. Any changes in the metabolite level of the brain after traumatic injury may be a useful predictor of a patient's outcome; therefore, if the sensitivity of MRS is proven, this method can have prognostic value when employed with patients with DAI.

**Conclusion:** Based on the results of this systematic review, MRS is a sensitive tool that is helpful in determining the prognosis of patients with DAI.

Please cite this paper as:

Shamsa A. Prognostic value of magnetic resonance spectroscopy in patients with diffuse axonal injury: a systematic literature review. *Rev Clin Med.* 2017;4(1):1-6.

## Introduction

Traumatic brain injury (TBI) is one of the leading causes of death and disability, and it is a significant global health problem. Diffuse axonal injury (DAI) is one of the most common causes of deterioration in patients with TBI, and it occurs in approximately half of patients who experience head injuries. Traffic accidents are the leading cause of DAI (1). DAI is a brain pathology that may cause prolonged traumatic coma. This injury usually oc-

curs following TBI, and extensive axonal damage is due to the disorganization of cellular structures and axonal edema in different areas of the brain (2-5). In conventional imaging, there is a weak relationship between the prognosis of patients and primary lesion. This can be due to DAI in the surrounding areas or areas beyond the original injury as well as microscopic axonal injuries (6,7). DAI is a major cause of disability that extends over a long

**\*Corresponding author:** Ali Shamsa.

Department of Neurosurgery, Ghaem Hospital, School of Medicine, Mashhad University of Medical Science, Mashhad, Iran.

**E-mail:** dr\_shamsa2006@yahoo.com

**Tel:** 09121714550

This is an Open Access article distributed under the terms of the Creative Commons Attribution License (<http://creativecommons.org/licenses/by/3.0>), which permits unrestricted use, distribution, and reproduction in any medium, provided the original work is properly cited.

time period. Although the exact prevalence of brain injuries vary by region, the incidence of mild TBI is about 100 to 600 cases per 100,000 people (8).

The prognosis of a disease may vary according to the severity, location of lesion and access to medical services. However, severe axonal damage often leads to coma and may not have a favorable outcome (8-10). Because computerized tomography (CT) scans and other macroscopic imaging techniques cannot properly identify the microscopic processes associated with DAI, it can be problematic to diagnose it. To date, none of the diagnostic methods that have been historically applied have been able to accurately predict the prognosis of patients with diffuse axonal brain lesions. According to the results of various studies, the level of brain metabolites is directly associated with the severity and prognosis of patients (11). Clinical findings suggest that measuring brain metabolites using magnetic resonance spectroscopy (MRS) can represent one possible way of predicting the prognosis of the pathological disease (11).

Nuclear magnetic resonance (NMR) spectroscopy, which is generally known as MRS, is a sensitive, accurate and non-invasive method by which changes in brain metabolites can be evaluated after a trauma (12). MRS is an imaging technique that provides spectroscopic information about the changes in biological markers as well as other metabolites during the activation of organs. Studies have found that neurobiochemical findings can help to evaluate the prognosis of patients with DAI (11). Therefore, the aim of this study was to systematically review the prognostic value of MRS imaging in diffuse brain lesions through the evaluation of existing studies in this area.

## Methods

### Search methods

The PubMed and Scopus databases were systematically searched using the following search criteria: "Magnetic resonance spectroscopy" and "Diffuse axonal injury" in the title, keywords, and abstract of papers in which the prognostic value of MRS as a practical and non-invasive imaging technique had been evaluated in traumatic DAI. For this purpose, the following search strings were applied to find relevant documents in PubMed: (["Magnetic resonance spectroscopy" OR MRS OR MR spectroscopy] AND ["Diffuse axonal injury" OR DAI] AND Prognosis). To identify articles in the Scopus database, the search that was performed in the PubMed search was replicated, but a customized search strategy was applied. For this purpose, "magnetic resonance spectroscopy" was searched in the Scopus, and then "diffuse axonal injury" was searched within the results. Afterward, the

articles extracted from both databases were limited to those documents that were written in the English language and were conducted on a human sample. The database search was performed on June 2015. To further reduce the possibility of data loss, after systematically searching the databases, Google Scholar and the Google search engine was also searched for the described key terms. The reference list of all the articles that were identified during the initial search were also manually screened to find any other potentially relevant documents.

### Study selection and inclusion/exclusion criteria

To ensure all relevant studies were included, all identified studies were assessed, regardless of the date of publication. However, to avoid data loss, reduce the incidence of undesirable errors, and minimize the risk of the extracted data being misinterpreted during the subsequent data synthesis process, only articles that were written in the English language were included in this study. By customizing the search method, articles with various types of clinical design including case-controls, cross-sectionals, clinical trials, comparative studies, and prospective cohort studies were included in this literature review for further data processing. However, conference papers, abstracts, editorials, review articles, and meta-analysis were excluded from further evaluation. Following a review of the title, keywords, and abstract of the selected articles, publications that contained duplicate data and those that were deemed to have subject and language irrelevancy were also excluded during the first step of article selection, as too were articles that did not contain the full text. In addition, articles that involved in vitro studies or research on animals were also excluded. Similarly, articles in which the MRS had been used to clinically evaluate metabolites in pathological changes other than DAI were also excluded. As such, the inclusion criteria for article selection in this review study were English-language articles in which the prognostic value of MRS had been investigated in patients with DAI.

### Data synthesis

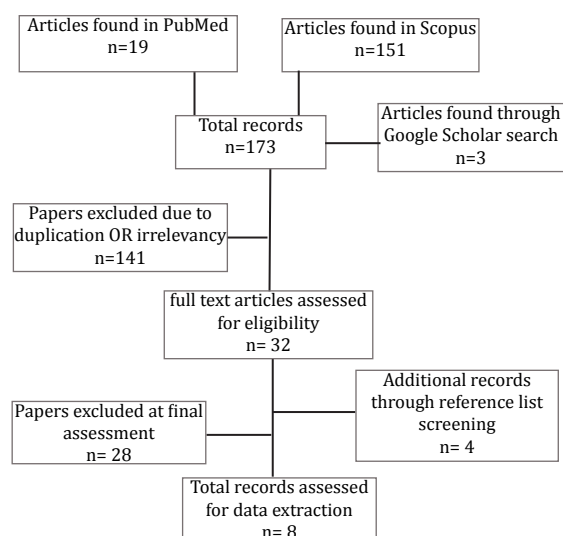
General information, including the name of the first author, country of origin, date of publication, and type of study design, as well as the number of subjects in the studied population, were extracted and recorded. Other available information including demographic data of studied population, the method of assessment, and the main findings were collected based on the main purpose of the study. Data were extracted and analyzed according to the results of studies that reported the efficacy and

prognostic value of MRS in DAI. All data processing, including the processes of article selection and data extraction, were performed independently by two reviewers according to the recommended standard protocol of the PRISMA checklist 2009 (13). Any discrepancies in terms of the application of the inclusion and exclusion criteria during the processes of data extraction were resolved between the authors prior to any further data synthesis.

## Results

### Study search results

A total of 19 relevant articles were found in PubMed and 151 in Scopus. Following a full review of the article abstracts, 93 irrelevant articles were excluded in the first step. Additionally, 23 documents were excluded due to language irrelevancy. Twenty-five documents that contained duplicated data were then excluded during the processes of article selection. Almost 18 articles in which the MRS imaging had been used for the diagnosis of hepatic disease or other pathological changes were also excluded from further assessment. Furthermore, nine studies that had been performed on animals were omitted. Four additional relevant documents were found through manual reference list screening of the previously selected documents. Three papers were also found and included following a search of Google Scholar and the Google search engine. Four of these papers were excluded because the full text of the published paper was not available. Finally, after a very strict process of article selection and a comprehensive review of the selected articles, only eight relevant articles, all of which met all of the defined inclusion/exclusion criteria, were used for subsequent data analysis. The step-by-step process involved in the literature search and study selection is presented in Figure 1.



**Figure 1.** Flowchart of the literature search strategy used in this study for the selection of relevant document.

### General characteristics of the included articles

The total number of participants enrolled in the studies described in the selected literature, in which the prognostic value of MRS as an accurate and non-invasive imaging technique had been evaluated in patients with DAI, was 197. Moreover, 55 healthy participants had been enrolled in some studies as a control group. The number of patients enrolled in the studies described in the selected literature varied from 8 to 60. According to the extracted data, patients of both genders had participated in the studies described in the selected literature. Unfortunately, because the gender ratio had not been reported in two studies, data could not be analyzed according to the gender of the subjects. However, in those articles that fully described the demographic data of the studied population, 86 patients were male, and 63 were female. The age of patients enrolled in the selected documents varied from one-year-old children to 65-year-old patients. Of the studies that were included in this literature review, one was a prospective cohort, two were cross-sectional, and 1 was a comparative study. In addition, there were 1 retrospective and 3 evaluation studies among the selected documents. The most recent article was published in 2013, while the oldest was published in 2002. The general characteristics of the included studies are presented in Table 1 in chronological order of the date they were published.

### Study results

The results of this review indicated that MRS is a suitable imaging technique that can accurately detect even small degrees of metabolite variation in clinical practice, especially in brain pathological assessments. All of the articles included in this study found that MRS can quantitatively detect changes in major brain metabolites such as N-acetyl aspartate (NAA), total choline (Cho), and total creatine (Cre), as well as myo-inositol (mI), glutamine, glutamate, and cerebrospinal fluid fractions in patients with DAI. Therefore, the results of this study suggest that MRS can be considered to represent a reliable imaging method for the assessment of axonal injuries. The main clinical outcomes and method of assessment are summarized in Table 2.

There were a number of limitations associated with this study. These included unreported data, particularly demographic information related to gender ratio, and a lack of studies, which may render the results insignificant or induce a lower percentage of MRS accuracy.

## Discussion

Diffuse axonal injury, which is histopathologically determined by observation of axonal edema, is a

**Table 1.** General overview of the articles.

NO	Author Year Reference	Country	Study Design*	Study Population®	Gender Ratio	Number of Patients
1	Kirov II 2013 (14)	USA	PSC	mTBI	21/5	26
2	Babikian 2010 (15)	USA	CSS	TBI	8/2	10
3	Govind 2010 (16)	USA	ES	TBI	25/4	29
4	Gasparovic 2009 (17)	USA	RS	mTBI	4/6	10
5	Holshouser 2005 (12)	USA	ES	TBI	-	40
6	Yoon 2005 (18)	Korea	CS	TBI	-	8
7	Uzan 2003 (19)	Turkey	ES	VS	9/5	14
8	De Stefano 2002 (20)	Italy	CSS	MS	19/41	60

\* CSS: Cross-sectional study, CS: Comparative study, ES: Evaluation study, PCS: Prospective cohort study, RS: Retrospective study, ® Mild traumatic brain injury (mTBI), MS: Multiple sclerosis, VS: Vegetative state

**Table 2.** Detailed information of included documents.

NO	Author Year Reference	Assessment ®	Variables *	Main findings
1	Kirov II 2013 (14)	MRI, multivoxel proton MRS, pathological analysis	NAA, Cho, Cr, ml	DAI is quantifiable with
2	Babikian 2010 (15)	MRI, proton MRS, NST	NAA, Cr	proton MRS imaging
3	Govind 2010 (16)	MRI, MRS, NST	NAA, Cho, Cr, GCS	MRS provides non-invasive quantifiable metabolite measures
4	Gasparovic 2009 (17)	Single-voxel MRS, NST	NAA, Cr, Glu, Gln	MRS provides valuable quantitative information in the diagnosis of mTBI
5	Holshouser 2005 (12)	MRS, SWI, HL	NAA, Cr, Cho, Lac, GCS	H-MRS is more sensitive than other methods in predicting metabolite alterations.
6	Yoon 2005 (18)	MRS, FIM	NAA, Cho, Cr, ml	Proton MRSI more accurately detected metabolite changes of DAI in brain tissue that appeared normal on imaging.
7	Uzan 2003 (19)	MRI and MRS	NAA, Cr	MRS has the potential to be used for detecting DAI
8	De Stefano 2002 (20)	MRS, SWI, MTr	NAA, Cr	MRS determines the degree of severity in neuronal and axonal injury

\* Cho: Choline, Cr: Creatine, Gln: Glutamine, Glu: Glutamate, GCS: Glasgow coma scale, ml: myo-inositol, NAA: N-acetylaspartate. ® FIM: Functional independence measure, Hemorrhagic lesions, MRI: Magnetic resonance imaging, MRS: Magnetic resonance spectroscopy, MTr: Magnetization transfer ratio, NST: neuropsychological test, HL: SWI: Susceptibility-weighted imaging.

subset of brain damage that is caused by trauma (21,22). This damage occurs in almost half of the cases of brain damage caused by severe trauma, which is the main cause of vegetative state in these patients (23). Conventional imaging methods, such as CT scan and magnetic resonance imaging (MRI), have limited diagnostic capabilities. MRS is a non-invasive and sensitive method by which post-traumatic brain metabolite changes can be evaluated. Research indicates that MRS may be a helpful technique for evaluating the prognosis of patients with DAI by measuring brain metabolites, such as Creatine and Choline, as a marker of metabolic energy and the health of cell membranes respectively (12). Many studies have evaluated the prognostic value of MRS in acute brain injury and coma and have assessed the metabolite levels in different brain regions (24). The results indicate that significant changes can be observed in brain metabolites after neuronal damage (3,25,26). The evaluation of the brain metabolite levels, such as NAA, Chol, Cr and lactate (Lac), in the normal brain, the internal capsule, and the cerebral peduncle using MRS imaging in patients with mild TBI has found that the level of these metabolites significantly changes in patients with DAI (5,27,28).

Studies have also shown that MRS can be efficiently used to evaluate other pathologies such as malignancies. Findings show that tumor tissues can be accurately distinguished from benign lesions (29). Studies suggested that MRS spectrum can be used to predict pathology and tumor metastasis. In addition, research has found that, in addition to its diagnostic value, proton MRS is a valuable imaging method that can predict patients' length of survival. Therefore, MRS is an efficient imaging method that provides biochemical information about the tissue as well as relevant prognostic information that may be valuable for the prediction of the pathological consequences of a lesion. It has recently been suggested that proton MRS may represent a useful and practical method for evaluating prognosis in neonatal encephalopathy (31,32). Therefore, the sensitivity and specificity of MRS have led researchers to consider this technique as a reference method that has valuable prognostic importance in terms of predicting the consequence of a pathology.

The results of studies indicate that MRS imaging can be an appropriate tool to determine the prognosis of patients with DAI. In addition, findings show that the use of metabolite indexes, such as NAA/chol ratio, can accurately determine the severity of DAI. The findings also reveal that NAA is directly associated with the severity of the injury and the prognosis of patients. Specifically, lower levels of this metabolite are suggestive of severe

injury and poor prognosis.

## Conclusion

The findings of this systematic review reveal that the level of brain metabolites, such as NAA, chol, and cr, can be accurately assessed using MRS imaging as a means of evaluating the severity of DAI. According to the conclusions of the studies that were examined as part of this literature review, MRS is a sensitive, accurate, and non-invasive imaging method that can have a prognostic value in patients with severe TBI and DAI.

## Acknowledgment

I would like to thank professor Dr. Mohammad Reza Ehsaii for his assistance in all the research techniques used in this article. I also like to show my gratitude to Dr. Yahya Jand for sharing his experience in the field of epidemiology during the course of this research.

## Conflict of Interest

The authors declare no conflict of interest.

## References

1. Wolf JA, Stys PK, Lusardi T, et al. Traumatic axonal injury induces calcium influx modulated by tetrodotoxin-sensitive sodium channels. *J Neurosci*. 2001;21:1923-1930.
2. Adams JH, Graham DI, Murray LS, et al. Diffuse axonal injury due to nonmissile head injury in humans: an analysis of 45 cases. *Ann Neurol*. 1982;12:557-563.
3. Adams JH, Doyle D, Ford I, et al. Diffuse axonal injury in head injury: definition, diagnosis and grading. *Histopathology*. 1989;15:49-59.
4. Meythaler JM, Peduzzi JD, Eleftheriou E, et al. Current concepts: diffuse axonal injury-associated traumatic brain injury. *Arch Phys Med Rehabil*. 2001;82:1461-1471.
5. Povlishock JT, Christman CW. The pathobiology of traumatically induced axonal injury in animals and humans: a review of current thoughts. *J Neurotrauma*. 1995;12:555-564.
6. Garnett MR, Blamire AM, Rajagopalan B, et al. Evidence for cellular damage in normal-appearing white matter correlates with injury severity in patients following traumatic brain injury: A magnetic resonance spectroscopy study. *Brain*. 2000;123:1403-1709.
7. Garnett MR, Blamire AM, Corkill RG, et al. Early proton magnetic resonance spectroscopy in normal-appearing brain correlates with outcome in patients following traumatic brain injury. *Brain*. 2000;123:2046-2054.
8. Zink BJ. Traumatic brain injury outcome: concepts for emergency care. *Ann Emerg Med*. 2001;37:318-332.
9. Maas AI, Stocchetti N, Bullock R. Moderate and severe traumatic brain injury in adults. *Lancet Neurol*. 2008;7:728-741.
10. Armin SS, Colohan AR, Zhang JH. Traumatic subarachnoid hemorrhage: our current understanding and its evolution over the past half century. *Neurol Res*. 2006;28:445-452.
11. Holshouser BA, Tong KA, Ashwal S. Proton MR spectroscopic imaging depicts diffuse axonal injury in children with traumatic brain injury. *AJNR Am J Neuroradiol*. 2005;26:1276-1285.
12. Yeo RA, Phillips JP, Jung RE, et al. Magnetic resonance spectroscopy detects brain injury and predicts cognitive functioning in children with brain injuries. *J Neurotrauma*. 2006;23:1427-1435.
13. Liberati A, Altman DG, Tetzlaff J, et al. The PRISMA statement for reporting systematic reviews and meta-analyses of studies that evaluate health care interventions: explanation and elaboration. *Annals Intern Med*. 2009;151:W65-W94.

14. Kirov II, Tal A, Babb JS, et al . Diffuse axonal injury in mild traumatic brain injury: a 3D multivoxel proton MR spectroscopy study. *J Neurol*. 2013;260:242-252.
15. Babikian T, Marion SD, Copeland S, et al. Metabolic levels in the corpus callosum and their structural and behavioral correlates after moderate to severe pediatric TBI. *J Neurotrauma*. 2010;27:473-481.
16. Govind V, Gold S, Kaliannan K, et al. Whole-brain proton MR spectroscopic imaging of mild-to-moderate traumatic brain injury and correlation with neuropsychological deficits. *J Neurotrauma*. 2010;27:483-496.
17. Gasparovic C, Yeo R, Mannell M, et al. Neurometabolite concentrations in gray and white matter in mild traumatic brain injury: an 1H-magnetic resonance spectroscopy study. *J Neurotrauma*. 2009;26:1635-1643.
18. Yoon SJ, Lee JH, Kim ST, et al. Evaluation of traumatic brain injured patients in correlation with functional status by localized 1H-MR spectroscopy. *Clin Rehabil*. 2005;19:209-215.
19. Uzan M, Albayram S, Dashti SG, et al. Thalamic proton magnetic resonance spectroscopy in vegetative state induced by traumatic brain injury. *J Neurol Neurosurg Psychiatry*. 2003;74:33-38.
20. De Stefano N, Narayanan S, Francis SJ, et al. Diffuse axonal and tissue injury in patients with multiple sclerosis with low cerebral lesion load and no disability. *Arch Neurol*. 2002;59:1565-1571.
21. Heath DL, Vink R. Impact acceleration-induced severe diffuse axonal injury in rats: characterization of phosphate metabolism and neurologic outcome. *J Neurotrauma*. 1995;12:1027-1034.
22. Kirov II, Tal A, Babb JS, et al. Proton MR spectroscopy correlates diffuse axonal abnormalities with post-concussive symptoms in mild traumatic brain injury. *J Neurotrauma*. 2013;30:1200-1204.
23. Marmarou A, Foda MA, van den Brink W, et al. A new model of diffuse brain injury in rats. Part I: Pathophysiology and biomechanics. *J Neurosurg*. 1994;80:291-300.
24. Conzen M, Ebel H, Swart E, et al. Long-term neuropsychological outcome after severe head injury with good recovery. *Brain Inj*. 1992;6:45-52.
25. Sinson G, Bagley LJ, Cecil KM, et al. Magnetization transfer imaging and proton MR spectroscopy in the evaluation of axonal injury: correlation with clinical outcome after traumatic brain injury. *AJNR Am J Neuroradiol*. 2001;22:143-151.
26. Cummings JL. Frontal-subcortical circuits and human behavior. *Arch Neurol*. 1993;50:873-880.
27. Bayly PV, Cohen TS, Leister EP, et al. Deformation of the human brain induced by mild acceleration. *J Neurotrauma*. 2005;22:845-856.
28. Hardman JM, Manoukian A. Pathology of head trauma. *Neuroimaging Clin N Am*. 2002;12:175-187.
29. Mountford CE, Somorjai RL, Malycha P, et al. Diagnosis and prognosis of breast cancer by magnetic resonance spectroscopy of fine-needle aspirates analysed using a statistical classification strategy. *Br J Surg*. 2001;88:1234-1240.
30. Majós C, Bruna J, Julià-Sapé M, et al. Proton MR spectroscopy provides relevant prognostic information in high-grade astrocytomas. *AJNR Am J Neuroradiol*. 2011;32:74-80.
31. Shanmugalingam S, Thornton JS, Iwata O, et al. Comparative prognostic utilities of early quantitative magnetic resonance imaging spin-spin relaxometry and proton magnetic resonance spectroscopy in neonatal encephalopathy. *Pediatrics*. 2006;118:1467-1477.
32. da Silva LF, Höefel Filho JR, Anés M , et al. Prognostic value of 1H-MRS in neonatal encephalopathy. *Pediatr Neurol*. 2006;34:360-366.