

# Ita. J. Sports Reh. Po.

Italian Journal of  
Sports Rehabilitation and Posturology




*Open Access Journal - ISSN 2385-1988 [online] - IBSN 007-111-19-55*



4





R. Flowers

**Sacral Stress Fracture in an Adolescent Dancer**

Ita J Sports Reh Po 2015 ; 2; 4 ; 420 - 428; doi : 10.17385/ItaJSRP.015.3013

ISSN 2385-1988 [online] - IBSN 007-111-19-55

420

# Ita. J. Sports Reh. Po.

Italian Journal of  
Sports Rehabilitation and Posturology

## Sacral Stress Fracture in an Adolescent Dancer

**Authors: Robert Flowers D.O.**

*Atlantic Health System Osteopathic Primary Care Sports Medicine Fellowship. NJ -USA*

### Abstract

*Sacral stress fractures are a fairly uncommon injury that if gone undiagnosed can cause significant morbidity. The incidence is not well known and is thought to be underreported, due to vague symptoms that can mimic other more common injuries, such as muscle strains and sciatica. The following case outlines an adolescent female with a less common presentation of a sacral stress fracture and a slow progressive return to activity. This article will also present a brief review of the literature focusing on the pathophysiology, presenting symptoms, diagnosis, treatment, and expected length of recovery for sacral stress fractures. Although this injury is uncommon, it often presents with common symptoms, and the clinician should not overlook it as a possible diagnosis.*

### Introduction

Stress fractures are a relatively common injury in the athletic population. The incidence has been estimated at 0.7-15% for all injuries sustained by athletes. This number varies, however, depending on the type of athlete. Among athletes playing collegiate level team sports the incidence can range from 1-8%, military recruits from 1-31% and the highest incidence has been



R. Flowers

**Sacral Stress Fracture in an Adolescent Dancer**

Ita J Sports Reh Po 2015 ; 2; 4 ; 420 - 428; doi : 10.17385/ItaJSRP.015.3013

ISSN 2385-1988 [online] - IBSN 007-111-19-55

421

seen in runners ranging from 13-52%.<sup>1</sup> Females are also at a higher risk of sustaining stress fractures compared to males, both in military recruits and the athletic population.<sup>2</sup> While lower extremity stress fractures are the most common and well documented, the same cannot be said for sacral stress fractures. Although it is known that they are less common, the incidence is not well known and likely underreported.

The purpose of this paper is to present a case of an adolescent female that was diagnosed with a sacral stress fracture. The paper will also briefly review the pathophysiology of stress fractures and the presentation, diagnostic workup, and treatment of sacral stress fractures. While sacral stress fractures can be divided into insufficiency or fatigue fractures, the former being seen in osteoporotic patients, this paper will only discuss fatigue fractures because that is what is seen in the athletic population.

### Case Description

A 14-year-old female initially presented with the complaint of right hip/groin pain. The patient is an avid dancer practicing multiple different techniques and styles, 3 days a week with each session lasting 2-3 hours. She has a Past Medical History significant only for well-controlled asthma. There is no Past Surgical History, no Allergies and no contributory Family History. The patient is a non-smoker/non-drinker, has regular menses since 13 years of age, a normal diet, exercises regularly, and who grew about 2 inches in the past year. She had sustained a right hamstring injury 4-5 months prior that was improving with physical therapy. Two months prior, she sustained a minor injury after doing a jumping split that was thought to be a right groin/adductor strain. The patient had negative x-rays at the time and continued with physical therapy. She was able to return to light dancing, but still was having some low-grade symptoms that prompted her to present to the office. The discomfort was worse with extremes of hip motion, particularly flexion and extension. The pain was not well localized; described as deep in the right groin, no back pain, no pain at rest, and no radiation. Physical exam showed good range of motion, but slight discomfort in the groin with full hip extension and some slight discomfort in the hamstring with hip flexion and full knee extension. Otherwise the exam was unremarkable. The working diagnosis at the time was hip flexor/adductor strain with a history of a resolving hamstring strain. Physical therapy was pursued, she was started on anti-inflammatories, and she was instructed to continue dancing as tolerated and to follow up in 4 weeks.

The patient presented six weeks later for follow up. She had been doing physical therapy and was restricting her dancing. There had only been some subtle improvements in her pain. It was still located in the right groin without radiation, some mild discomfort in the hamstring, both not well localized and was worse with dancing, particularly jumping splits. Rest and anti-inflammatories helped minimally. Physical exam at this point was unremarkable. There was no pain with lumbar range of motion or palpation and no pain with hip range of motion or palpation. This included active, passive and resisted motion, as well as FABERE's testing and straight leg raises. It was





R. Flowers

**Sacral Stress Fracture in an Adolescent Dancer**

Ita J Sports Reh Po 2015 ; 2 ; 4 ; 420 - 428 ; doi : 10.17385/ItaJSRP.015.3013

ISSN 2385-1988 [online] - IBSN 007-111-19-55

unsure why her pain was persisting for so long, so a pelvic MRI was ordered to rule out a possible pelvic stress fracture and to assess the soft tissue structures.

The pelvic MRI without contrast showed a linear fracture of the anterolateral right sacrum extending into the articular surface, with preserved sacral joints. There were no other bony abnormalities and no muscle/tendon abnormalities. (Figure 1,A,B,C)

422

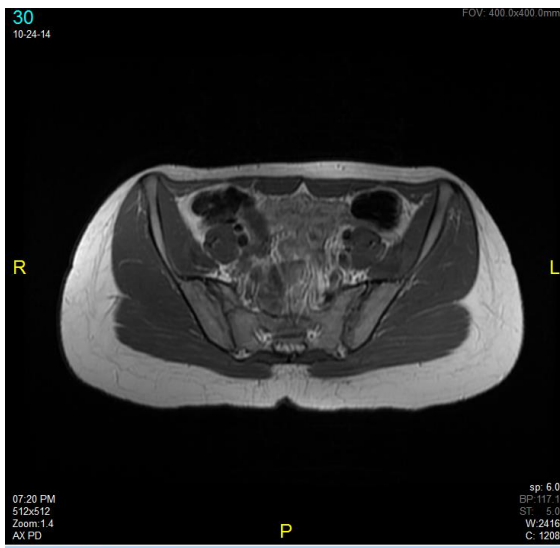

Figure 1 A

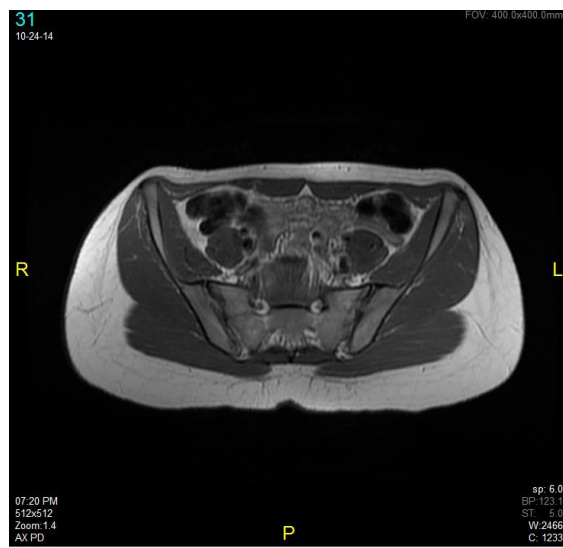

Figure 1 B

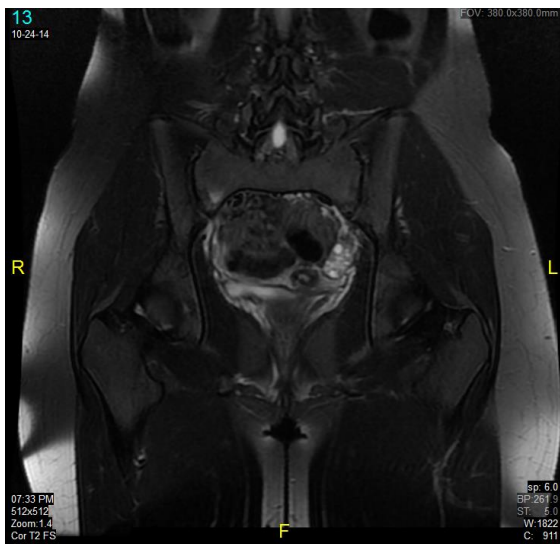



Figure 1 C

**Figures A-B:** are sequential T1 axial images demonstrating the linear fracture line through the lateral right sacrum. **Figure C:** is a T2 coronal image showing an area of hyperintense signal on the right lateral, anterior sacrum.



R. Flowers

**Sacral Stress Fracture in an Adolescent Dancer**

Ita J Sports Reh Po 2015 ; 2; 4 ; 420 - 428; doi : 10.17385/ItaJSRP.015.3013

ISSN 2385-1988 [online] - IBSN 007-111-19-55

423

The patient followed up two weeks after the MRI. Her symptoms showed no significant change and she still complained of low-grade vague pain in the right groin and hamstring areas. The pain was described as a deep ache and worse with dancing. The patient denied back pain, paresthesias or weakness and no radiation. The pain improved with rest and she was taking anti-inflammatories sporadically, which helped mildly.

She had also stopped her usual dancing schedule and was only doing some mild exercises at home. Physical exam was again unremarkable with no lumbar or pelvic tenderness to palpation and no pain with the various ranges of motion. She was instructed to refrain from any physical activity until her follow up in 4 weeks. It was decided to continue her in physical therapy to focus on light stretching and core strengthening to prepare her for a gradual return to activity.

The patient followed up four weeks later for re-evaluation. She was not dancing and was slowly improving, but suffered an exacerbation after carrying a friend on her back. After which she noticed pain in the right sacroiliac region. For the following two days she did aggressive ice massage and there was some improvement. She had continued physical therapy and intermittent use of NSAIDs. However, there continued to be right lower back pain worse with activity, lumbar extension in particular. The pain was still dull, mild and without radiation or neurologic symptoms. Physical exam showed some tenderness of the right lower lumbar paraspinals and sacroiliac joint with palpation. Range of motion was maintained, but there was mild pain with extension and soreness with right side bending. There was no spinous process tenderness, negative straight leg raise and negative FABERE. There was also no pain with hip range of motion or palpation. Due to the patient's exacerbation and increased localization of symptoms, she was instructed to continue to refrain from dancing and physical activity, including any heavy lifting. She was encouraged to continue with icing as needed and anti-inflammatories. A follow-up appointment was suggested for 4 weeks to hopefully begin gradual return to activity at that time.

The patient was seen again in the office eight weeks later. She stated that she had been pain free for 24 hours. She had ceased physical therapy and had been going to dance class to familiarize herself with the routines, but was not participating in them. However, she had been doing some dancing at home – it was very light and she was avoiding any splits. Her physical exam was unremarkable except for some mild tenderness to palpation of the right lateral sacrum. There was no pain with lumbar range of motion, hip range of motion or FABERE. The plan was to slowly advance the patient's activity. It was decided to progress her back into dancing, only one hour per class and to avoid any position that caused discomfort.

The patient followed up four weeks later showing much improvement. She was attending class only two days a week for one hour and had no pain for the past three weeks. She participated in regular techniques, but was still avoiding high impact and jump splits. There was no pain with lumbar extension or static splits. The patient was also no longer taking any pain medication. Physical exam was significant only for some mild tenderness of the right posterior superior iliac spine and no tenderness of the lateral sacrum or sacroiliac joint. There was no pain with lumbar or hip range of motion, straight leg raising or FABERE test, and it was decided to continue gradual increase in dancing. The patient was instructed to go to class for her usual three day a week



R. Flowers

**Sacral Stress Fracture in an Adolescent Dancer**

Ita J Sports Reh Po 2015 ; 2; 4 ; 420 - 428; doi : 10.17385/ItaJSRP.015.3013  
ISSN 2385-1988 [online] - IBSN 007-111-19-55

routine for 1.5 hours each session. If she remained pain free after one week, she was to increase each class session by 30 minutes until she resumed full activity. The patient was told to follow up as needed and has not since returned to the office.

424

## Discussion

Stress fractures are a relatively common injury in athletes, particularly athletes who undergo repetitive forces. It is these repetitive forces, or loads, that cause bone to remodel, following Wolff's Law. The more pressure put on a bone will cause it to remodel in an attempt to adapt to the increased load. This remodeling is lead by a balance between osteoclasts and osteoblasts. During periods of intense, repetitive exercise, bone formation lags behind bone resorption. If the bone is not given enough time to rest, the osteoblasts will not lay down a sufficient amount of bone, leading to a weakened bone matrix and increased susceptibility to fracture.<sup>3</sup>

Since stress fractures are typically due to chronic repetitive forces, the injury can be looked at or classified as a spectrum. This spectrum can range from asymptomatic stress reaction or bone edema, to symptomatic stress reactions, to non-displaced fractures, displaced fractures and to non-unions. Another classification system is to look at the fractures as either high or low risk, which is based on the fracture site and the likelihood to progress to displaced fractures or non-unions. Examples of low risk fractures include: second through fourth metatarsal shafts, posteromedial tibial shaft, proximal humerus or humeral shaft, inferior side of the femoral neck, ribs, sacrum, pubic rami. Examples of high risk fractures include: lumbar pars interarticularis, femoral head, superior side femoral neck, patella, anterior cortex of tibial shaft, medial malleolus, talus, navicular, proximal fifth and fourth metatarsal, base of the second metatarsal and great toe sesamoids.<sup>1</sup> Although sacral stress fractures can be considered low risk, the severity of the fracture and the location within the sacrum should be taken into account. There is no specific classification system for sacral stress fractures, but Denis et al. has classified traumatic sacral fractures into three zones. Zone 1 involves the lateral part of the sacrum, the sacral ala. These injuries usually do not have any neurological involvement, but occasionally can damage a lumbar nerve root. Zone 2 involves the sacral foramina, and frequently involves the sciatic nerve causing unilateral radiculopathies. Zone 3 involves the sacral body and central canal leading to bilateral neurologic symptoms such saddle anesthesia and loss of sphincter tone. Fortunately, zone 1 fractures are the most common and are what will likely be seen in young athletes with stress injuries.<sup>4,5</sup>

Patients with sacral stress fractures typically present with similar complaints of low back pain, sacral/sacroiliac pain and buttock pain +/- radiation. A literature search by Kahanov et al. in 2011 showed that 57 of the 60 cases of sacral stress fractures presented with low back pain and diffuse buttock pain.<sup>6</sup> The pain is usually exacerbated with weight-bearing activities like walking and usually improves with rest. However, patients can also present with groin pain, hip pain, lateral thigh pain, or pelvic pain. Physical exam findings can include tenderness with palpation of the sacrum, a positive hop test, FABERE test, Gaenslen's test and squish test.<sup>4,5</sup> All of which will elicit pain in the sacroiliac region. Even though these symptoms seem to be well localized they are by



R. Flowers

**Sacral Stress Fracture in an Adolescent Dancer**

Ita J Sports Reh Po 2015 ; 2; 4 ; 420 - 428; doi : 10.17385/ItaJSRP.015.3013


ISSN 2385-1988 [online] - IBSN 007-111-19-55

no means specific to this injury, which can lead to a wide differential. It is easy to see why sacral stress fractures can go under-reported. Our case is a perfect example of this.

Our patient initially presented with groin and hamstring pain. It wasn't until after an MRI and an exacerbation that she began developing sacroiliac pain. Could her presenting symptoms have all been associated with a sacral stress fracture or did she initially have a muscle strain that lead to weakness and increased forces to the sacrum? It is the rarity of this injury, yet the common symptoms, that can make the diagnosis easily missed. When a sacral stress fracture is suspected, the diagnostic workup should follow that of most stress fractures. The history and physical examination should guide the diagnosis and imaging studies should be used to help with confirmation. Plain AP and lateral radiographs of the pelvis, sacrum and lumbar spine should be obtained first. They have a low sensitivity, but are specific if positive.

Periosteal elevation, cortical thickening, sclerosis and a true fracture line are examples of a positive finding.<sup>1</sup> If x-rays are negative, but there is still high clinical suspicion, more imaging studies should be performed. Computer tomography (CT), bone scintigraphy and magnetic resonance imaging (MRI) are all viable options, each with their own pros and cons. MRI, however, is more sensitive and considered by many to be the gold standard test of diagnosis stress fractures. Once the diagnosis of a stress fracture is made, the more difficult question may be why did it occur. Most commonly it is due to repetitive forces being put on a particular bone. The forces become excessive when there is a mechanical dysfunction, such as muscles weakness or improper technique. However, systemic causes for secondary osteoporosis may need to be considered and investigated using laboratory studies. An initial workup can include the following: CBC, CMP (which includes Calcium, albumin, alkaline phosphatase and liver functions), phosphorus, 25-(OH) Vitamin D, TSH, ESR, CRP and parathyroid hormone (PTH).<sup>4</sup> Female athletes should also have particular attention focused on their history in order to help recognize the presence of the female athlete triad.

The treatment of sacral stress fractures is also similar to other low risk stress fractures. It essentially involves pain control, cessation of activity with a gradual return, and usually some rehab to help regain strength and confidence. Pain control can be obtained from a wide spectrum of option ranging from ice, to over the counter medication, to prescription narcotics. It has been theorized that non-steroidal anti-inflammatory drugs (NSAIDS) may have a negative effect on bone healing, however, this has not been substantiated in the literature. There are several studies supporting this theory and several others disproving it. Currently there is a lack of evidence either way and there is even conflicting results within similar study designs.<sup>7,8,9</sup> It appears that pain control options should remain at the discretion of the treating doctor using his or her best judgment. Limitation of physical activity is the mainstay of treatment and is mainly driven by pain and Wolff's law. Patients should be instructed to weight-bear as tolerated. Too much stress will not allow the bone to heal and completely nonweight - bearing decreases the load on the bones causing decreased bone remodeling. If there is pain with normal ambulation, crutches may be necessary. Activity should gradually increase as tolerated with pain being a guide. Supplementation with calcium and Vitamin D is also a viable treatment option. Even in patients without Vitamin D deficiency on laboratory findings may benefit from supplementation.



R. Flowers

**Sacral Stress Fracture in an Adolescent Dancer**

Ita J Sports Reh Po 2015 ; 2; 4 ; 420 - 428; doi : 10.17385/ItaJSRP.015.3013  
ISSN 2385-1988 [online] - IBSN 007-111-19-55


426

A study on female Naval recruits showed that patients with a 25 (OH) Vitamin D concentration >40 ng/mL had half the incidence of tibial and fibular stress fractures compared to patients with a concentration <20 ng/mL.<sup>10</sup> Return to full activity can take from 4 weeks up to 2 years based on a review of sacral fracture case reports<sup>6</sup>. Our patient took 7 months from the time of initial presentation. Return to full activity is difficult to predict and should be looked at on a case-by-case basis.

### Conclusion

Sacral stress fractures can be a challenging injury to recognize because of the nonspecific symptoms. It is something that should be in the differential diagnosis of sports medicine physicians for patients who present with low back pain, especially in those who are not improving with conventional management. A thorough history and physical exam should be performed on all patients presenting with a possible sacral stress fracture and an MRI pursued in those with high suspicion. Conventional management is the treatment of choice, however patients should be educated that this is a potentially serious injury that could take several weeks or months to completely resolve.





R. Flowers

**Sacral Stress Fracture in an Adolescent Dancer**

Ita J Sports Reh Po 2015 ; 2; 4 ; 420 - 428; doi : 10.17385/ItaJSRP.015.3013  
ISSN 2385-1988 [online] - IBSN 007-111-19-55

## References

427

1. DeWeber, K. Eiff, P. Grayzel, J. Feb 19, 2015. Overview of Stress Fractures. Uptodate. [http://www.uptodate.com/contents/overview-of-stress-fractures?source=search\\_result&search=stress+fractures&selectedTitle=1%7E105#H57](http://www.uptodate.com/contents/overview-of-stress-fractures?source=search_result&search=stress+fractures&selectedTitle=1%7E105#H57)
2. Wentz, L. Liu, P. Haymes, E. Ilich, J. Females have a greater incidence of stress fractures than males in both military and athletic populations: a systemic review. *Mil Med.* 2011 Apr;176(4):420-30
3. Warden, S. Burr, D. Brukner, P. Stress Fractures: pathophysiology, epidemiology and risk factors. *Current Osteoporosis Rep.* 2006 Sep; 4(3): 103-109.
4. Valentina, L. Cristina, B.Valerio, S. The management of sacral stress fractures: current concepts. *Clin Cases Miner Bone Metab.* 2011 Sep-Dec; 8(3): 19–23.
5. Denis, F.Davis,S.Comfort, T. Sacral fractures: an important problem. Retrospective analysis of 236 cases.*ClinOrthopRelat Res.* 1988 Feb;227:67-81
6. Leamor, K. Lindsey, E. Thurman, A. Joshua, T. Brad, Y. Sacral Stress Fracture in a distance Runner. *The Journal of the American Osteopathic Association*, October 2011, Vol. 111, 585-591.
7. Jeffcoach, D. et al. Nonsteroidal anti-inflammatory drugs' impact on nonunion and infection rates in long-bone fractures. *Journal of Trauma and Acute Care Surgery*: March 2014 - Volume 76 - Issue 3 - p 779–783.
8. Kurmis, A. Kurmis, T. O'Brien, J. Dalén, T. The Effect of Nonsteroidal Anti-Inflammatory Drug Administration on Acute Phase Fracture-Healing: A Review. *J Bone Joint Surg Am*, 2012 May 02; 94 (9): 815 - 823.
9. Pountos, I. et al. Do Nonsteroidal Anti-Inflammatory Drugs Affect Bone Healing? A Critical Analysis.*ScientificWorldJournal.* 2012; 2012: 606404.
10. Burgi, A. Gorham, E. Garland, C. Mohr, S. Garland, F. Zeng, K. Thompson, K. Lappe, J. High serum 25-hydroxyvitamin D is associated with a low incidence of stress fractures. *Journal of Bone and Mineral Research.*Volume 26, Issue 10, pages 2371–2377, October 2011.



R. Flowers

**Sacral Stress Fracture in an Adolescent Dancer**

Ita J Sports Reh Po 2015 ; 2; 4 ; 420 - 428; doi : 10.17385/ItaJSRP.015.3013

ISSN 2385-1988 [online] - IBSN 007-111-19-55

428





# Ita. J. Sports Reh. Po.

Italian Journal of  
Sports Rehabilitation and Posturology

