



PEDIATRIC UROLOGY CASE REPORTS

ISSN 2148-2969

<http://www.pediatricurologycasereports.com>

Long-term indwelling double-J stent and multiple encrusted stones in the ureter and bladder: A case report on Holmium laser treatment

Mehmet Hanifi Okur, Selcuk Otcu

Department of Pediatric Surgery, Dicle University, School of Medicine, Diyarbakir, Turkey

ABSTRACT

Double-J (D-J) stents are widely used in a variety of urological interventions. Forgotten D-J stents may lead to complications, such as migration, fragmentation and encrustation. We report the case of a forgotten stent, concomitant with ureteral and bladder stones. The forgotten D-J stent was placed four years prior to our intervention, during treatment for multiple right renal stones. Holmium laser lithotripsy was used to disrupt encrustations on a ureteral orifice and the ureteral stent. The percutaneous suprapubic cystostomy was removed without breaking the stent. The patient was discharged without further complications.

Key Words: Double-J (D-J) stents; forgotten stent; encrustation; stone; Holmium laser lithotripsy.

Copyright © 2018 [pediatricurologycasereports.com](http://www.pediatricurologycasereports.com)

Corresponding Author: Dr. Mehmet Hanifi Okur.
Department of Pediatric Surgery, Dicle University,
School of Medicine, Diyarbakir, Turkey.

E mail: m.hanifi-okur@hotmail.com

ORCID ID: <https://orcid.org/0000-0002-6720-1515>

Received 2018-10-09, Accepted 2018-10-21

Publication Date 2018-11-01

Introduction

Although Double-J (D-J) stents are widely used in a variety of urological interventions, their removal can sometimes be overlooked. Poor adaptation and the patient's sociocultural development are important aspects of this problem. Forgotten and encrusted D-J stents can result in costly removal processes [1], with complications that range from urinary tract infections, stone formation, migration and fragmentation and stent encrustation to loss of renal function [2,3]. Although various

endourological and open surgical methods have been reported for the management of forgotten D-J stents, there is no standardized approach for their removal in adults and children [4].

We report on a case of a forgotten D-J ureteral stent that had been placed during a percutaneous nephrolithotomy, four years prior to our intervention. The patient was a 14-year-old male who presented with flank pain and hematuria.

Case report

A 14-year-old male presented to our polyclinic with side pain and hematuria. Four years earlier, he had undergone a percutaneous nephrolithotomy for multiple right renal calculi and the insertion of a D-J stent at our hospital. The patient's physical examination

revealed right side pain and lower abdominal tenderness. Urine analysis showed purulence, hematuria and turbidity. A detailed interview revealed that the patient had not returned for his previous outpatient appointments and that he had forgotten about the placement of the D-J stent. Ultrasonography showed proximal and distal ureteral encrustation, multiple stones in the bladder and hydronephrosis on the patient's right side. In addition, kidney, ureteric and bladder (KUB) radiographs revealed several ureteral and vesical calculi integrated with the D-J stent [Fig. 1].

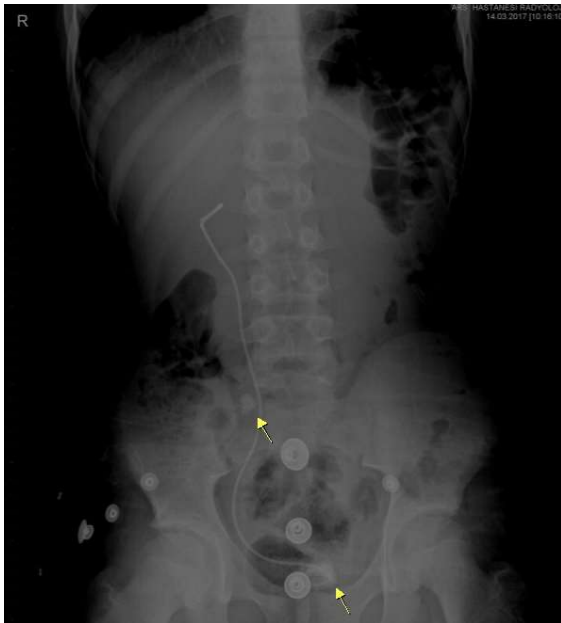


Fig. 1. Renal, ureteric and bladder (KUB) radiograph view of the stone burden and encrusted double-J stent.

Endourological procedures were planned for the patient's treatment. The patient was placed in a lithotomy position under general anesthesia. A cystoscopy revealed that the stent's bladder section was completely encrusted. Holmium laser lithotripsy (StoneLight Holmium Laser System, AMS Inc., Minnetonka, MN, USA) was used to disrupt the encrustation on the ureteral orifice

and the ureteral stent. Care was taken not to disintegrate the stent in the bladder during the Holmium laser (HoL) lithotripsy and the other endourological procedures. The percutaneous suprapubic cystostomy was removed without breaking the stent [Fig. 2].



Fig. 2. Appearance of the encrusted double-J stent and all stones.

After the procedure, the patient's symptoms disappeared, and, after follow-up, no more stones were detected.

Discussion

Over the last decade, new materials and technological developments have made D-J stents an essential part of many urological procedures, including treatments for retroperitoneal tumors and fibrosis, ureteral strictures, ureteropelvic junction obstructions, urolithiasis and iatrogenic ureter injuries as well as renal transplantation [1-5]. In most cases, the use of D-J stents is uncomplicated.

However, in the short term, ureteric stents may cause side effects, such as lower abdominal pain, dysuria, fever, urinary frequency, tenesmus, hematuria and nocturia [6]. Additionally, D-J stents that are left in place for a long time due to doctor and/or patient neglect can lead to serious complications, including stone formation, migration, fragmentation and crusting [2]. Stent fragmentation is associated with polymer degradation and polyethylene and polyurethane hardening, while stent encrustation is often related to alkaline urine and urinary tract infections [7]. The management of forgotten D-J stents is a challenge for doctors because removal is time consuming, complex, risky and expensive [4]. Hao et al. [8] studied the use of D-J stents in 2685 cases for the treatment of various nephrouretic problems. They reported that keeping these stents in place for less than 28 days was safe for both endoscopic and open procedures. However, when the stents were left in place for more than two months, crusting occurred. The risk of stent crusting is higher in patients with urinary stone diseases [7]. Spirnak and Resnick reported on a series of five patients with ureteral stents that calcified two weeks after placement [9]. In recent literature reports, D-J stents have been forgotten for up to 12 years, and, in most cases, the stents spontaneously disintegrated [10].

In the preoperative imaging and evaluation of forgotten D-J stents, ultrasonography, KUB and computed tomography are generally sufficient [11]. To remove complicated stents, one or a combination of medical, lithotripsy and endourological techniques and open surgery may be required. Oral Acetohydroxamic acid have been used to dissolve struvite and carbonate apatite calcifications on ureteral stents [12]. Lupu et

al. [13] preferred shock wave lithotripsy as a noninvasive method to remove calcified ureteric stents. Holmium: yttrium aluminum garnet laser have been successfully used in the treatment of urological diseases since 1990 [14]. Tsai et al. [11] reported on a case where a D-J stent was removed by cystolithotripsy and ureterorenoscopic lithotripsy with an HoL. They proposed that HoL offered an adequate alternative to safely and effectively manage forgotten D-J stents with severe crusting [11]. In the present case, an HoL was used to release the ureteral part of the D-J stent from the encrustation and stone formation, and, later, the stent was safely removed. Appropriate stent length and placement, early cystoscopy removal or replacement of ureteral stents, and prophylactic antibiotic treatment can minimize complications, such as migration, calcification and fragmentation. In this case, the stent was forgotten because the patient did not return for regular clinical examinations. Therefore, it is important to raise patient awareness of potential stent complications and to keep written records of such patients.

Compliance with ethical statements

Conflicts of Interest: None.

Financial disclosure: None.

Consent: All photos were taken with parental consent.

References

- [1] Polat H, Yücel MÖ, Utangaç MM, Benlioğlu C, Gök A, Çift A, et al. Management of Forgotten Ureteral Stents: Relationship Between Indwelling Time and Required Treatment Approaches. *Balkan Med J.* 2017;34(4):301-307.
- [2] Bostancı Y, Özden E, Atac F, Yakupoğlu YK, Yılmaz AF, Sarıkaya S. Single session removal of forgotten encrusted ureteral

- stents: combined endourological approach. *Urol Res.* 2012;40(5):523-29.
- [3] Kulkarni AA, Paras Kothari, Gupta A, Dikshit V. Forgotten DJ stents with calculi in a double moiety re-implant: A case report. *Pediatr Urol Case Rep.* 2017; 4(1):253-55.
- [4] Adanur S, Ozkaya F. Challenges in treatment and diagnosis of forgotten/encrusted double-J ureteral stents: the largest single-center experience. *Ren Fail.* 2016;38(6):920-26.
- [5] Beiko DT, Knudsen BE, Denstedt JD. Advances in ureteral stent design. *J Endourol.* 2003;17(4):195-99.
- [6] Vega Vega A, García Alonso D, García Alonso CJ. Characterization of urinary tract symptoms and quality of life in patients with double-pig-tailed ureteral stents]. *Actas Urol Esp.* 2007;31(7):738-42.
- [7] Chen CK, Li CC, Ke HL, Chou YH, Huang CH, Shih MC. Double J stent forgotten for 7 years: a case report. *Kaohsiung J Med Sci.* 2003;19(2):84-87.
- [8] Hao P, Li W, Song C, Yan J, Song B, Li I. Clinical evaluation of double pigtail stent in patients with upper urinary tract diseases: report of 2685 cases. *J Endourol.* 2008;22(1): 65-70.
- [9] Spirnak JP, Resnick MI. Stone formation as a complication of indwelling ureteral stents: a report of 5 cases. *J Urol.* 1985;134(2):349-51.
- [10] Niranjana A, Agarwal N, Agarwal V, Srivastava A. Enigma of forgotten double J stent. *Saudi J Kidney Dis Transpl.* 2010;21(1):157-9
- [11] Tsai CC, Shen JT, Huang SP, Chang SF, Tsai LJ, Wu WJ, et al. Use of a Holmium laser to treat a forgotten double-J stent with whole stent encrustations: a case report. *Kaohsiung J Med Sci.* 2009;25(10):567-71.
- [12] Burns JR, Gauthier JF. Prevention of urinary catheter encrustations by acetohydroxamic acid. *J Urol.* 1984;132(3):455-56.
- [13] Lupu AN, Fuchs GJ, Chaussy CG. Calcification of ureteral stent treated by extracorporeal shock wave lithotripsy. *J Urol.* 1986;136(6):1297-98.
- [14] Watterson JD, Girvan AR, Cook AJ, Beiko DT, Nott L, Auge BK, et al. Safety and efficacy of holmium: YAG laser lithotripsy in patients with bleeding diatheses. *J Urol.* 2002;168(2):442-5.

Access this article online

<http://pediatricurologycasereports.com>

Quick Response Code

