

**PEDIATRIC UROLOGY CASE REPORTS**

ISSN 2148-2969

<http://www.pediatricurologycasereports.com>**Diagnostic challenge of adrenal cyst in an adolescent girl: A case report and overview of the literature****Serpil Sancar, Esra Ozcakir, Arzu Sizgen, Mete Kaya***Department of Pediatric Surgery, University of Health Sciences, Bursa Yuksek Ihtisas Training and Research Hospital, Bursa, Turkey***ABSTRACT**

Cystic lesions of adrenal gland are rare and usually asymptomatic in children. Cysts usually have been found incidentally by imaging studies during an investigation of other abdominal causes. Differential diagnosis of adrenal cysts from other cystic disease may not be possible by imaging studies. Although the management of adrenal cysts is a controversial subject, surgical treatment is still important for both diagnosis and treatment. In this case report, we will discuss the surgical approach of a case with adrenal cyst detected incidentally.

Key Words: Adrenal cyst; retroperitoneal mass; benign tumor.

Copyright © 2018 pediatricurologycasereports.com

Corresponding Author:

Dr. Serpil Sancar

Pediatric Surgery, University of Health Sciences, Bursa Yuksek Ihtisas Training and Research Hospital, Bursa, Turkey

E mail: sancar.serpil@gmail.com

ORCID ID: <https://orcid.org/0000-0001-5464-8695>

Accepted for publication: 21 July 2018

Introduction

Cystic lesions of the adrenal gland are rare, often manifested by nonspecific clinical and radiological findings, and are therefore, not well recognized. The adrenal cysts are generally nonfunctioning and benign. On the other hand, it has been reported malign adrenal cyst in the literature [1,2]. The pathogenesis of the adrenal cysts is not clear, and a lot of hypotheses have been putted forward [2]. In this case report, we aimed to present a case of

the adrenal cyst which not diagnosed definitely preoperatively.

Case report

A 13-year-old girl was referred to our clinic after visualization of an abdominal cystic mass in echocardiography, which was ordered to investigate chest pain. On physical examination, there was slightly tenderness by deep palpation on her left upper quadrant. Imaging studies including abdominal ultrasonography (US) and magnetic resonance imaging (MRI) were obtained. A uniformly contoured anechoic cyst sized 7x5 cm on the left upper quadrant of abdomen was revealed in US.

The cyst was adjacent to the spleen and the upper pole of left kidney, and was considered as giant exophytic renal cortical cyst. Whether

the cyst is originated from the adrenal gland, the pancreas or the kidney could not differentiated by imaging studies [Fig. 1a-c].

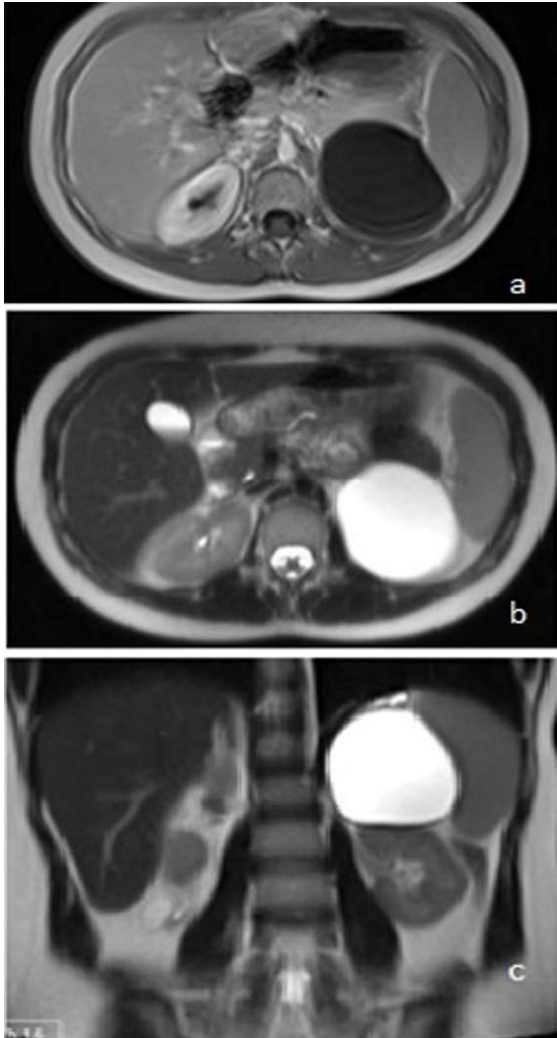


Fig. 1. Magnetic resonance imaging had a cystic lesion with a T1 AS hypointense (a) and T2 AS hyperintense (b, c) signal at about 7 cm in the upper pole of the left kidney.

Tumor markers, hormone panel and biochemical tests were in normal range. The hemagglutination test is negative for *Echinococcus*.

At that time, we decided for surgical removal of the retroperitoneal cystic mass. The patient was given preoperative antibiotic (cefazolin 100mg/kg/dose), and operated under general

anesthesia. A right upper transverse incision was made, and retroperitoneal cystic mass palpated. The left total fascia incised and splenic flexure of the colon were mobilized, and entered to the retroperitoneal space. A round cystic mass which originated from the left adrenal gland, approximately 7 cm in diameter was visualized. Normal adrenal tissue was seen in the rest of the left lateral adrenal horn. Cyst and adjacent adrenal tissue were resected [Fig. 2]. No pathologic lymph node was detected. Abdomen was closed with layers, no drain was placed. The patient discharged on the 3rd day after surgery without any event.

Histopathologically, a specimen which cystic nature 6x5x4 cm in diameter and adjacent a yellowish tissue 3x2x0.2 cm observed macroscopically. Microscopically, the cyst wall was composed of flat, thin endothelial cell and residual adrenal tissue was observed [Fig. 3a]. Immunohistochemical study revealed that endothelial cells showed positive staining with CD31 and P240 [Fig. 3b]. Histopathological diagnosis was vascular endothelial cyst. The patient remained well without any complaints or redurrence during 3 years of follow up.

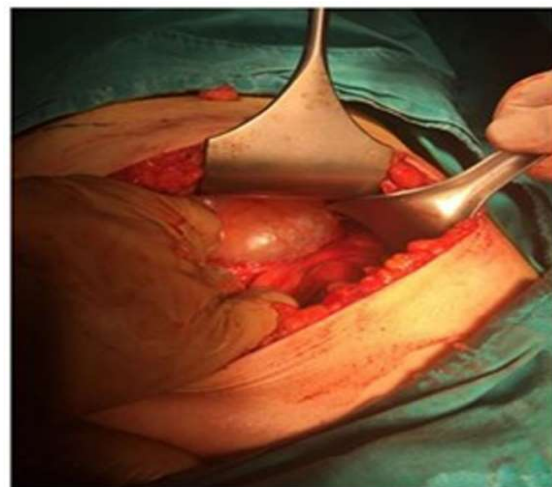


Fig. 2. Operative appearance of adrenal cystic mass.

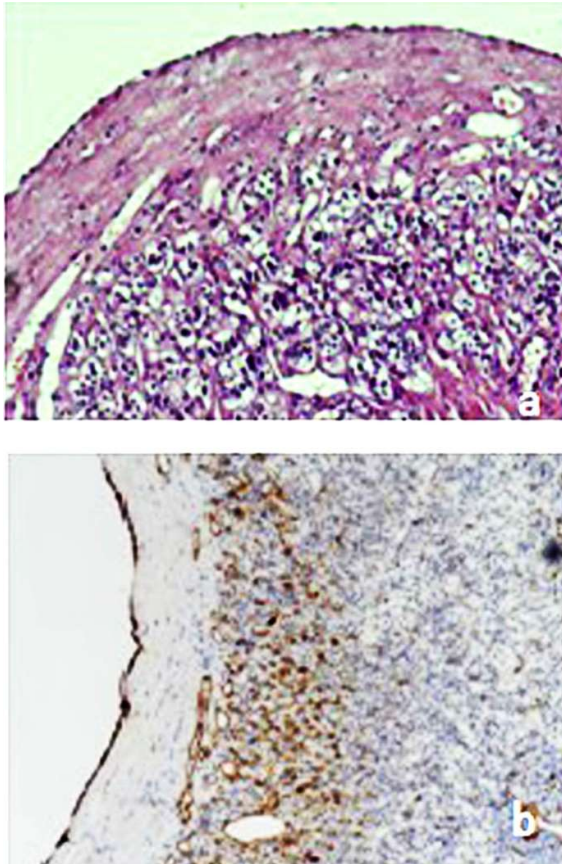


Fig. 3. a. Histopathologic photographs show that the cyst wall was composed of flat, thin endothelial cell and residual adrenal tissue was observed in the cyst wall (Hematoxylin and eosin, X200). b. Endothelial cells on immunohistochemical staining (CD 31 and P240, X200).

Discussion

Adrenal cysts represent as rare clinical entities that observed in 0.06-0.18% of the population in autopsy series [3,4,5]. Incidence of adrenal cysts in adrenal disease was 5.1-5.4% [6,7]. It can be diagnosed at every age from fetal period to advanced age of life and especially between the third and sixth decades [5,6,8]. There are limited case-reports of adrenal cysts in children. Although various theories have been proposed, the exact pathogenesis of adrenal cysts is unknown. These theories include vascular neoplastic growth, malformation, and

hemorrhage into the adrenal parenchyma due to stress, coagulopathy, etc [9]. In the literature, adrenal cysts are classified in many different ways. According to the presentation: they can be small or large, functional or nonfunctional, true or pseudocysts, and benign or malignant [10]. In addition, according to the pathologic classification, four types have been described: cystic degeneration of adrenal neoplasms, true cysts, pseudocysts and infectious cysts [11]. The most common types of adrenal cysts are epithelial cysts and pseudocysts. True cysts are lined with endothelial (vascular adrenal cysts) or mesothelial cells. Pseudocysts are not lined by any type of epithelium, are covered by a fibrous wall within the adrenal gland, classified into hemorrhagic cysts, neoplastic, and parasitic cysts. The most common cause of infectious cysts is *Echinococcus* [11]. We have categorized our case as large, noninfectious, endothelial, true adrenal cyst.

Most adrenal cysts are asymptomatic and can be detected incidentally, more often on the right side, and more often in female patients [2]. Symptoms occur with cystic mass effect (abdominal pain abdominal mass, flank pain) and potential hormonal activity [1,5,8]. Also arterial hypertension has been reported in adrenal masses [5,12]. Our patient had abdominal pain and chest pain due to mass effect. A cystic mass was diagnosed incidentally by echocardiography. Right upper quadrant tenderness was present in abdominal examination.

Laboratory tests in adrenal cysts are usually normal. However, cystic adrenal tumors that are active endocrinologically have been described in the literature, and consequently functional status of an adrenal tumor, as defined by secretion of adrenal cortical or medullary hormones [2,5]. Only 15% of all

adrenal cysts are found to be functional [2,3]. Nevertheless, performing hormonal tests in all patients with adrenal lesions is recommended, and Echinococcal hemagglutination test can also be performed if the hydatid disease suspicion. The laboratory evaluation in our case revealed a nonfunctional cyst with normal levels of adrenal hormones and hemagglutination test was negative.

US, CT and MRI examinations are very effective in recognizing cystic lesions. The abdominal cystic lesions such as splenic, pancreatic, bile duct, liver, kidney, splenic, mesenteric and retroperitoneal or hydatid cysts determined by imaging studies, and all of which are involved in the differential diagnosis of adrenal lesions [8]. However, it is not always possible to give information on the exact origin of the cysts or risk of malignancy by imaging studies. Our patient had intraabdominal cystic mass (size 6x5x4cm) initially thought to be adrenal cyst in ultrasonography and MRI findings. No definitive diagnosis was established by US and MRI in our case.

The treatment of adrenal cysts can be managed either conservative close monitoring or by surgery. Asymptomatic, small, and non-hormonally active cysts can be followed up closely by US, CT and MRI [2,5]. Surgical method options of adrenal cysts are defined as percutaneous needle aspiration followed by sclerotherapy, cyst unroofing, surgical resection of cyst and adrenalectomy with cyst surgical resection of cyst are performed for surgical treatment [2,8,13]. Surgical resection may be performed by laparoscopic or open surgery. Both methods can be applied to all patients with adrenal cyst [4,8]. There is no consensus on selection of the patients who need surgery. Surgical resection was recommended in symptomatic or hormonally

active adrenal cyst and/or cystic lesion greater than 4 or 5 cm [3,6,13]. Recently, adrenal sparing surgery is recommended regardless of the method used [8]. On the other hand, Bellantone et al [3] have performed total adrenal excision in all patients that have adrenal cysts due to possible adrenal malignancy. In our patient, open surgery preferred because of unclear differential diagnosis. The cystic mass was totally excised with partial adrenalectomy.

The postoperative complications include wound infections, organ/space infection, wound disruption/dehiscence, pneumonia, pulmonary embolism, and deep venous thrombosis/thrombophlebitis. Complications were seen more common in functional cysts [14]. Postoperative course of our patient was uneventful, and no complication was developed on follow-up period. Histopathological evaluation was revealed as vascular endothelial cyst without malignant component.

In conclusion, the adrenal cysts are generally asymptomatic, nonfunctioning benign lesions. It may not be distinguished from other abdominal or retroperitoneal cysts by imaging studies. Surgical excision provides both histopathological evaluation for differential diagnosis and treatment of adrenal cysts. Adrenal gland sparing surgery could be performed, if there is no evidence of adrenal malignancy.

Compliance with ethical statements

Conflicts of Interest: None.

Financial disclosure: None.

Consent: All photos were taken with parental consent.

References

- [1] Neri LM, Nance FC. Management of adrenal cysts. *Am Surg*. 1999;65(2):151-63.
- [2] Wedmid A, Palese M. Diagnosis and treatment of the adrenal cyst. *Curr Urol Rep*. 2010;11(1):44-50.
- [3] Bellantone R, Ferrante A, Raffaelli M, Boscherini M, Lombardi CP, Crucitti F. Adrenal cystic lesions: report of 12 surgically treated cases and review of the literature. *J Endocrinol Invest*. 1998;21(2):109-14.
- [4] Pogorzelski R, Toutounchi S, Krajewska E, Fiszer P, Pachucki J, Bednarczuk T, et al. Laparoscopic treatment of adrenal cysts--own research and literature review. *Endokrynol Pol*. 2015;66(5):469-72.
- [5] Ricci Z, Chernyak V, Hsu K, Mazzariol FS, Flusberg M, Oh S, et al. Adrenal cysts: natural history by long-term imaging follow-up. *AJR Am J Roentgenol*. 2013;201(5):1009-16.
- [6] Lyu X, Liu L, Yang L, Gao L, Wei Q. Surgical management of adrenal cysts: a single-institution experience. *Int Braz J Urol*. 2014;40(59):656-65.
- [7] Castillo OA, Litvak JP, Kerkebe M, Urena RD. Laparoscopic management of symptomatic and large adrenal cysts. *J Urol*. 2005;173(3):915-17.
- [8] Carsote M, Ghemigian A, Terzea D, Gheorghisan-Galateanu AA, Valea A. Cystic adrenal lesions: focus on pediatric population (a review). *Clujul Med*. 2017;90(1):5-12.
- [9] El-Hefnawy AS, El Garba M, Osman Y, Eraky I, El Mekresh M, Ibrahim el-H. Surgical management of adrenal cysts: single-institution experience. *BJU Int*. 2009;104(6):847-50.
- [10] Darwish A, Nagaraj V, Mustafa MB, Al Ansari A. Adrenal cyst presenting as hepatic hydatid cyst. *Case Rep Surg*. 2013;2013:150457.
- [11] Bulut G, Bulut MD, Yilmaz D, Celik S, Toprak N. Mixed type adrenal cyst: A case report. *Eastern Journal of Medicine*. 2015;2083:163-66.
- [12] Tanuma Y, Kimura M, Sakai S. Adrenal cyst: a review of the Japanese literature and report of a case. *Int J Urol*. 2001;8(9):500-503.
- [13] Sebastiano C, Zhao X, Deng FM, Das K. Cystic lesions of the adrenal gland: our experience over the last 20 years. *Hum Pathol*. 2013;44(9):1797-1803.
- [14] Gupta PK, Natarajan B, Pallati PK, Gupta H, Sainath J, Fitzgibbons RJ Jr. Outcomes after laparoscopic adrenalectomy. *Surg Endosc*. 2011;25(3):784-94.

Access this article online

<http://pediatricurologycasereports.com>

Quick Response Code

