



PEDIATRIC UROLOGY CASE REPORTS

ISSN 2148-2969

<http://www.pediatricurologycasereports.com>**Congenital urethroperineal fistula with scrotal localization: A case report****Mahamoud Omid Ali Ada¹, Hellé Moustapha¹, Oumarou Habou², Amadou Soumana³, Halidou Maazou⁴, Habibou Abarchi¹**¹Department of Pediatric Surgery, National Hospital of Lamordé, Niamey, Niger²Departments of Pediatric Surgery, National Hospital of Zinder, Zinder, Niger³Department of Urology, National Hospital of Lamordé, Niamey, Niger⁴Department of Urology, National Hospital of Zinder, Zinder, Niger**ABSTRACT**

A congenital urethroperineal fistula (CUPF) is a rare malformation that can be considered an unusual form of urethral duplication. A 3-year-old boy presented with an orifice in the middle of his scrotum through which urinary leakage was observed during micturition. Retrograde and voiding urethrocytograms showed a fistula tract extending from the prostatic urethra to his perineum. He was successfully treated with resection of the fistula performed via a perineal approach. No clinical sign and radiological evidence of disease were observed during his 4-month postoperative follow-up. Accurately distinguishing CUPF from a similar form of urethral duplication (type II A2-Y urethral duplication) is important for definitive treatment.

Key Words: Congenital urethroperineal fistula; urethral duplication; Y-type.

Copyright © 2018 pediatricurologycasereports.com

Corresponding Author: Dr. Mahamoud Omid Ali Ada, Pediatric surgeon, Assistant, Faculty of Health Sciences, Abdou Moumouni University of Niamey, BP 10894 Niamey, Niger.

E mail: omidali_1999@yahoo.com

ORCID ID: [0000-0003-2530-5620](https://orcid.org/0000-0003-2530-5620)

Accepted for publication: 30 May 2018

Introduction

A congenital urethroperineal fistula (CUPF) or congenital posterior urethral-perineal fistula is an abnormal communication extending from prostatic urethra to the perineal skin [1]. It is a rare and unusual form of urethral duplication [2,3]. The anus and the anterior urethra are observed to be normal, and the fistula always communicates with the prostatic urethra [4].

The primary issue in the management of CUPF is to accurately distinguish this condition from a similar pathology: type II A2-Y urethral duplication. Most patients clinically present with urinary leakage from the perineum [5]. A cystourethrogram shows the fistula tract. Surgical excision of the fistula performed via a perineal approach is the primary treatment, and most patients demonstrate good postoperative results [1].

Over the last 52 years, 30 cases have been reported in the literature reported in English [1,6]. We present a case of CUPF showing rare localization of the perineal opening in the scrotum.

Case report

A 3-year-old boy was observed since the age of 7 months to show an orifice in the middle of his scrotum from which drops of urine would leak out during micturition. He had no history of urinary incontinence or urinary tract infection. Physical examination revealed a tiny opening localized to the inferior part of his scrotum, slightly to the left, noted 7 cm above the anal margin [Fig. 1]. A Ch5 feeding tube could be introduced through this opening and urine could be drained. The external genitalia and the perineum were normal.

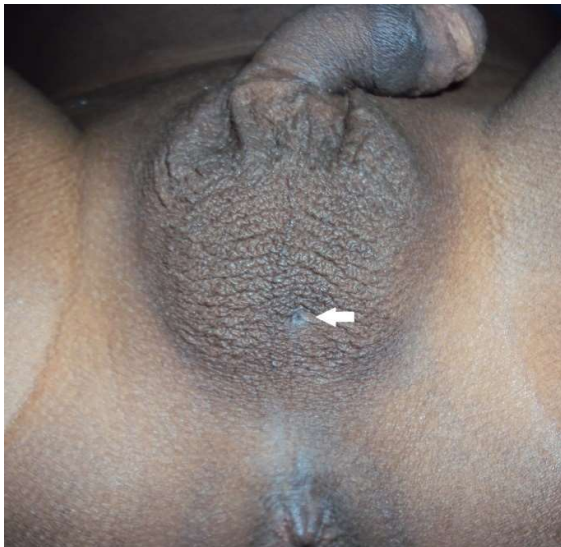

Fig. 1. Perineal orifice of the fistula (white arrow) is observed to be localized to the left-sided scrotal area.

Cytobacteriological examination of urine was normal. Retrograde and voiding urethrocytograms showed a normal urethra with a fistula originating from the prostatic urethra, thereby establishing the diagnosis of CUPF [Fig. 2]. Renal ultrasonography and intravenous urography did not identify associated malformations or pathology.

A fistulectomy was performed via a perineal approach after an urethral catheter has been placed. A Ch5 feeding tube was introduced and

a circular skin incision was made around the orifice. Dissection around the fistula was performed on a length of 6 cm [Fig. 3]. The proximal stump of the fistula with approximately 8 mm of length, was ligated using a 3-0 polyglactin acid thread, when further mobilization was not possible.

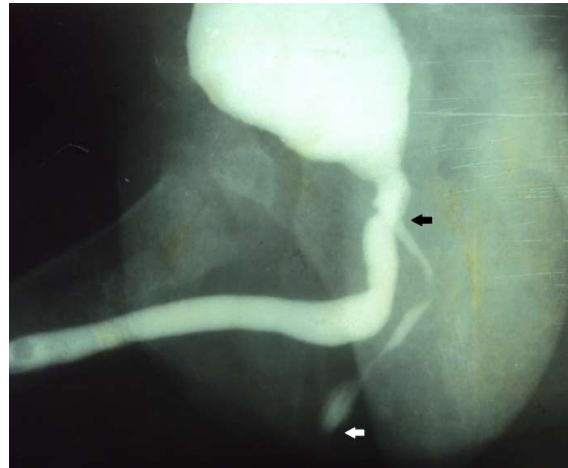

Fig. 2. Urethrocytogram shows the urethroperineal fistula tract originating from the prostatic urethra (black arrow) extending to the perineum (white arrow).

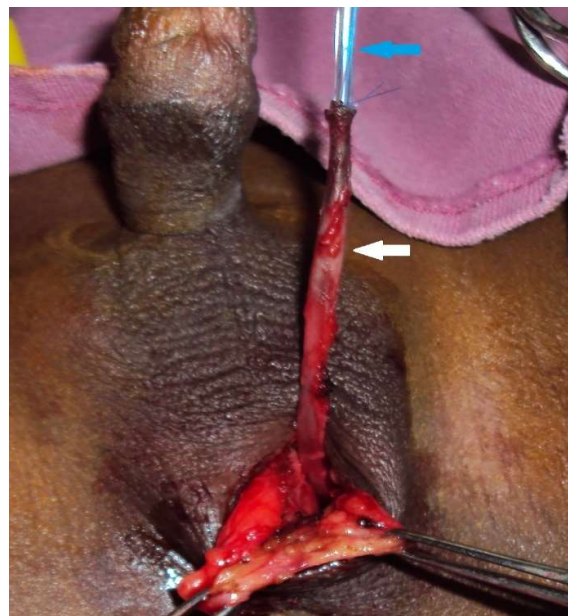


Fig. 3. Dissection of the fistula tract (white arrow) and its cannulation using a Ch5 feeding tube (blue arrow) to aid in dissection.

The patient reported no complaints or complications at his 4-month postoperative follow-up. Postoperative retrograde and voiding urethrocytograms were normal [Fig. 4].

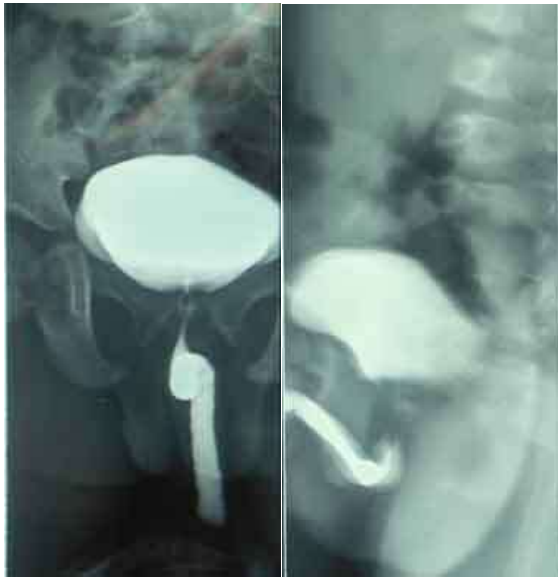

Fig. 4. Postoperative urethrocytogram without urethroperineal fistula tract visualized.

Discussion

CUPF is a rare congenital anomaly of the male genitourinary tract [1]. Several names have been used to refer to this pathology: congenital Y-type urethroperineal fistula, Y-type urethral duplication in a male, or Y-type congenital urethral duplication [4,5,7].

A few authors consider CUPF to be a congenital urethral duplication associated with a normal dorsal urethra and a small ventral fistula extending to the perineal skin [7], which could be categorized as a unique form or variation of urethral duplication [1,5,8].

The Effmann's classification describes different types of urethral duplication [7]. Per this classification, the type II A2 variety refers to complete urethral duplication in which a patient presents with 2 urethral meatuses. A large ventral second channel is observed to

originate from a hypoplastic, dorsal orthotopic urethra and when the two channels exit independently, they present a "Y" shaped configuration [5].

Thus, CUPF resembles the Y-type urethral duplication, although both entities clearly differ with respect to their anatomopathologic features [9,10]. In patients with Y-type urethral duplication, the ventral urethra (which opens onto the perineum) is the functional urethra, whereas the more dorsal channel remains underdeveloped. In contrast, in patients with CUPF, the dorsal urethra functions as the normal urethra, and the ventral urethra (fistula) is hypoplastic.

Patients with urethral duplication often present during infancy or early childhood, whereas CUPF is usually noticed in older children [3,11]. In those with Y-type urethral duplication, urinary leakage occurs predominantly through the perineum and less commonly the penis [1].

Although both pathological entities show similar features on imaging studies [9,11], each condition requires different treatment [9]. In patients with urethral duplication, the functional ventral urethra needs to be transposed into a more eutopic position [3,7]. Despite such differences between these two conditions, several authors propose that CUPF should be classified as a true urethral duplication and not a urethral fistula [3,4,8,13]. An argument in favor of this recommendation is the presence of transitional cell epithelium lining the fistula tract, either partially or completely [3,8,13]. It is usually expected that a fistula would be lined by squamous epithelium [6]. A second argument in favor of this proposition is the absence of factors predisposing to the formation of a fistula (e.g., presence of infection, trauma, or foreign bodies) [5].

Although numerous theories have been proposed, the embryological basis to explain CUPF formation remains unclear [3,8]. An abnormal descent of the urorectal septum or an anomaly in the fusion of its ridges during the stage of division of the cloaca are commonly mentioned [2,13]. Consequently, there originates an accessory urogenital sinus [2,8]. Pressure atrophy from the heel of the fetal foot and a vascular accident have been viewed as possible etiologies of the anomalies [5, 14]. The urethral opening of the fistula is located within the prostatic urethra, usually near the verumontanum or close to the bladder neck [1,3-14]. Localization of the perineal opening of the fistula may often be observed between the base of the scrotum and the anus [1,3,4,8,9,11,12,13]. Scrotal localization, as was observed in our patient, has been observed in 3 cases [5,14,15]. The length of the fistula varies between 3.6 cm and 6 cm [3,6,8,13]. A segment of the fistula tract can get enlarged to form a saccular dilatation or a palpable cystic mass, particularly at its distal end [4,13,15]. According materials used to perform catheterization of the fistula the diameter of the fistula tract varies between the dimensions of a lachrymal probe (0.4 mm) and a 4F ureteral catheter (1.33 mm) [3,7,9].

The age of presentation varies between 9 days and 82 years [1,6]. Twenty four of the 30 cases reported in the literature were child [1,6]. Leakage of urine from the perineum during voiding is the commonest clinical sign [2-5,8,9,12,13]. Urinary tract infections, perineal abscess, and purulent discharge are less common [8,9,11,12]. Micturition is often normal and dysuria may rarely be observed [8,9].

Voiding and retrograde cystourethrography are the primary imaging test used to diagnose CUPF, as was performed in our patient

[1,2,4,5,8,9,12,13]. These imaging studies show a normal dorsal urethra and the ventrally located fistula [1]. Fistulography is less commonly used [1,6,14]. When the external orifice of the fistula is closed or is not easily visualized, fistulography fails to demonstrate the ventral fistula [1,7]. Magnetic resonance imaging can show the exact anatomical course of the fistula tract and its relationship to adjacent pelvic and perineal structures [1,11]. Urethrocystoscopy is indicated to confirm the radiographic findings [5,8]. Through the perineal opening of the fistula tract methylene blue can be instilled or a catheter can be passed. Flow of the methylene blue or the catheter visualized in the prostatic urethra using a cystoscope confirm the diagnosis [8,13,14].

In most cases, histopathological examination of the fistula shows an inner layer of transitional and/or squamous epithelium [1,6]. A few cases of associated anomalies have been reported in the literature describing mainly urogenital anomalies associated with CUPF such as renal hypoplasia, unilateral vesicoureteral reflux, hypoplastic dorsal urethra, hypospadias, and testicular microlithiasis [6, 9,12,14].

CUPF requires treatment because it is symptomatic and owing to the risk of fistula cancerization (caused by urinary stasis and recurrent infections) [11]. Excision of the fistula via a perineal approach is the commonest treatment used [3,5-8,13]. This technique is simple and curative [1]. However, there is a lack of operatory site exposure. Risk of injury to the external sphincter, and the possibility of postoperative urethral stricture are likely complications [2,3,13]. These complications can be avoided by not excising approximately 4–5 mm of the last proximal segment of the fistula tract [3,13].

Two others treatments that have been used only in 1 patient respectively: injection of a bulking agent (dextranomer-based implant) around the internal orifice of the fistula [14] and fulguration of the fistula along its entire length using an electrode under cystoscopic guidance [2].

Several authors studying such cases have reported no recurrence of fistula or complications during 6-week to 2-year postoperative follow-up [3,5-7,14,15]. Fistula recanalization occurring 5 months postoperatively has been reported in one patient [9].

Conclusion

CUPF is a rare congenital anomaly of the male genitourinary tract with an unclear etiology. Leakage of urine from a perineal opening is the commonest clinic sign. Cystourethrography is the first diagnostic test. This condition requires treatment to avoid complications. Surgical excision of the fistula tract is the standard treatment and it has a good outcome. The primary issue that needs attention is differentiating between CUPF and type II A2-Y urethral duplication.

Compliance with ethical statements

Conflicts of Interest: None.

Financial disclosure: None.

Consent: All photos were taken with parental consent.

References

[1] Sakaguchi T, Hamada Y, Matsushima H, Hamada H, Shirai T, Shigeta Y, et al. Congenital urethroperineal fistula. *J Pediatr Surg Case Rep*. 2018; 28: 17–20.

[2] Brown C W, Dillon PW, Hensle TW. Congenital urethral.perineal fistula:

diagnosis and new surgical management. *Urology*. 1990; 36(2):157–59.

- [3] Bello JO. Congenital posterior urethroperineal fistula: a review and report of the 25th case in literature. *Urology*. 2014; 84 (6):1492–95.
- [4] Gupta A, Lal P, Krishna A. Congenital Y-Type urethra-perineal fistula. *Eur J Pediatr Surg*. 1997; 7(4): 252–53.
- [5] Sanchez MM, Vellibre RM, Castelo JL, Arias MP, Sarmiento RC, Costa AR. A new case of male Y-type urethral duplication and review of literature. *J Pediatr Surg*. 2006; 41(1): e69–71.
- [6] Perez JF, Díaz B, Ramos GU, Peralta SR. Congenital posterior urethral fistulae: Literature review and case report *Urol Int*. 2018. doi: 10.1159/000486040. [Epub ahead of print].
- [7] Meier DE, Latiff A. Y-type congenital urethral duplication with normal dorsal urethra and small ventral fistula to perineal skin – 28th reported case. *J Pediatr Surg Case Rep*. 2016; 8 :37–9.
- [8] Wagner JR, Carr MC, Bauer SB, Colodny AH, Retik AB, Hendren WH. Congenital posterior urethral perineal fistulae: a unique form of urethral duplication. *Urology*. 1996; 48(2) : 277–80.
- [9] Bates DG, Lebowitz RL. Congenital urethroperineal fistula. *Radiology*. 1995; 194(2) : 501–4.
- [10] Levin TL, Han B, Little BP. Congenital anomalies of the male urethra. *Pediatr Radiol*. 2007; 37(9): 851–62.
- [11] Ghadimi-Mahani M, Dillman JR, Pai D, Park J, DiPietro M. MRI of congenital urethroperineal fistula. *Pediatr Radiol*. 2010; 40 : S1–5.
- [12] Estaun JE, Alfageme AG. Testicular microlithiasis associated with congenital

- urethroperineal fistula. *Pediatr Radiol*. 2001; 31(9): 676.
- [13] Rice PE, Holder TM, Ashcraft KW. Congenital posterior urethral perineal fistula. *J Urol*. 1978 ;119 (3) :416–17.
- [14] Bedir S, Kilciler M, Ozgok Y. Case report: endoscopic treatment of isolated congenital urethroperineal fistula. *J Endourol*. 2006; 20 (1) :42–44.
- [15] Redman JF, Rountree GA. Congenital urethral scrotal fistula. *Urology*. 1977; 9(3): 310–11.

Access this article online

<http://pediatricurologycasereports.com>

Quick Response Code

