

**PEDIATRIC UROLOGY CASE REPORTS**

ISSN 2148-2969

<http://www.pediatricurologycasereports.com>**Nephrectomy for advanced ureteral hypoplasia accompanied by renal dysplasia in a patient with congenital hydronephrosis: A case report****Fumiko Chiba, Kouji Masumoto, Yasuhisa Urita***Department of Pediatric Surgery, Faculty of Medicine, Tsukuba University, Ibaraki, Japan***ABSTRACT**

The patient was an 8-month-old girl. Her prenatal ultrasonography at 26 weeks of gestation revealed an abdominal cystic lesion. After birth, the patient was diagnosed with left hydronephrosis and referred to our hospital. Ultrasonography showed grade IV hydronephrosis in the left kidney. MAG3 scintigraphy showed no function in the left kidney. Cystoscopic retrograde pyeloureterography revealed advanced stenosis throughout the entire length of the left ureter. For intraoperative findings, the ureter was extremely thin with 2.6 mm outer diameter and the renal parenchyma was mostly scarred. Since it was difficult to place a stent in the ureter, nephrectomy was performed. For pathological findings, fibrosis with cartilage tissue in the residual renal parenchyma was observed and renal dysplasia was confirmed. Nephrectomy should be considered for advanced ureteral hypoplasia in patients with the entire ureteral hypoplasia because the diseased kidney is often accompanied by dysplasia or severe hypoplasia.

Key Words: Congenital hydronephrosis; ureteral hypoplasia; non-functioning kidney; nephrectomy.

Copyright © 2018 pediatricurologycasereports.com

Corresponding Author: Fumiko Chiba, M.D.
*Department of Pediatric Surgery, Faculty of Medicine,
Tsukuba University, 1-1-1, Tennoudai Tsukuba City,
Ibaraki, Japan*

E-mail: fumikoc@md.tsukuba.ac.jp

Accepted for publication: 17 March 2018

dysplasia or severe hypoplasia occurs [2,3]. Therefore, it is often difficult to preserve the kidney if a patient has the entire hypoplastic ureter. Here we report a case of hydronephrosis associated with advanced ureteral hypoplasia, which was treated by left nephrectomy.

Introduction

Hydronephrosis is mostly caused by stenosis of the ureteropelvic junction or the ureterovesical junction [1], and it is extremely rare that hydronephrosis is caused by hypoplasia throughout the entire length of the ureter. Also, stenosis or obstruction of the fetal ureter tends to be high grade, and the earlier obstruction develops, the more likely renal

Case report

The patient was an 8-month-old girl. An abdominal cystic lesion was indicated on prenatal ultrasonography at 26 weeks of gestation. The girl was born through normal vaginal delivery at 40 weeks of gestation and weighed 3,150 g. She was referred to our hospital after left hydronephrosis was

suspected on ultrasonography at birth. Since grade III-IV left hydronephrosis was confirmed in our hospital, outpatient follow-up was conducted [Fig. 1]. Neither urinary tract infection nor growth retardation was observed during the follow-up.

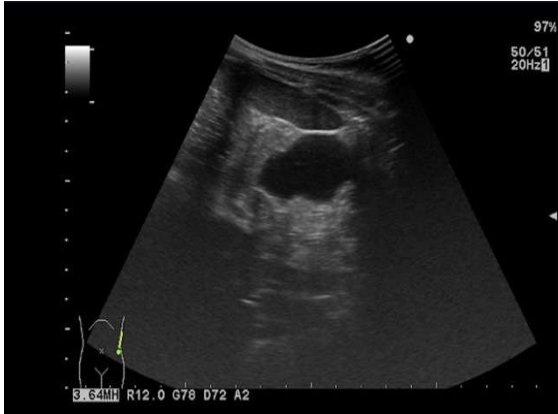


Fig. 1. Ultrasonography at age of 8-month. Grade IV left hydronephrosis with 7-8 mm renal parenchymal thickness are revealed.

At 8-month of age, blood/biochemical examination showed no major abnormal findings, but the levels of β 2-microglobulin and cystatin C were high with 2.7 mg/dl and 1.48 mg/L, respectively. Ultrasonography revealed grade IV left hydronephrosis with 7-8 mm renal parenchymal thickness. Calcification was not observed. Compensatory hypertrophy was observed in the right kidney, which was 6.8×3.3 cm in size. ^{99m}Tc -MAG3 renal scintigraphy revealed a split renal function of 3.2% (left) and 96.7% (right), showing no function in the left kidney and delayed excretion in the right kidney. Voiding cystourethrography showed no vesicoureteral reflux, urethral stricture, or neurogenic bladder. As ultrasonography confirmed the renal parenchyma although renal scintigraphy indicated no function in the left kidney, left pyeloplasty was planned for the surgical strategy.

First, cystoscopic retrograde pyeloureterography was conducted. When observing with a cystoscopy, the left ureteral orifice existed normally. It was difficult to insert a 3Fr tube into the left ureter, but barely inserted the tip of the tube into the ureteral orifice and injected a contrast medium. Severe stenosis of the entire ureter and dilation of the renal pelvis were observed [Fig. 2].

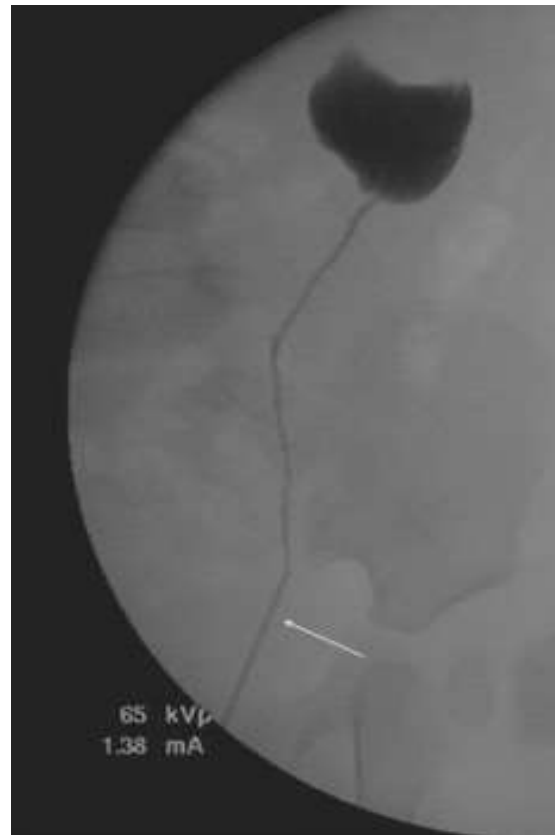

Fig. 2. Retrograde pyeloureterography. A 3Fr tube was inserted into left ureteral orifice (arrow) and injected a contrast medium. Severe stenosis of the entire ureter and dilation of the renal pelvis were observed.

After the retroperitoneal approach, the ureter was identified and separated. The ureter was extremely thin with the outer diameter of 2.6 mm and even thinner at the ureteropelvic junction. From the findings, we determined it would be too difficult to perform pyeloplasty.

Although stent placement was attempted, neither the outer cylinder of 24G indwelling needle nor 28G PI® catheter could be inserted. In addition, since scarring and atrophy of the left kidney were observed, left nephrectomy was performed. For blood flow to the left kidney, there were two renal arteries and two renal veins at the renal hilus, but the artery and vein flowing into the inferior kidney were extremely thin. Also, blood flow around the ureter was unidentified macroscopically.

Pathological examination confirmed immature lumen structure and cartilage tissue as well as fibrosis in the renal parenchyma. Small amounts of glomerulus and renal tubules were present. Fibrosis was also seen in the renal pelvic wall. Although the lumen of the ureter was observed, the entire ureter was highly hypoplastic.

There was no postoperative problem and no major change in the right kidney. In the 1-year postoperative biochemical examination, the β 2-microglobulin level was 1.5 mg/dl and the cystatin C level was 1.05 mg/L, which showed a decreasing tendency.

Discussion

The most common cause of congenital hydronephrosis is obstruction of the ureteropelvic junction, and other causes include vesicoureteral reflux, obstruction of the ureterovesical junction, and ectopic opening of the ureter [1]. Except for vesicoureteral reflux, obstruction of the ureter often results in hydronephrosis, but it is extremely rare that hypoplasia throughout the entire length of the ureter is the cause of hydronephrosis. Urinary obstruction with urinary hypoplasia usually occurs during early development of the fetus [5]. Therefore, the extent and timing of the obstruction are the most important factors for the functional status

of the kidneys. Because a hypoplastic ureter produces a wide range of pathologies associated with kidney, the obstruction in the early stages leads to the development of the dysplastic kidneys and the obstruction in the subsequent stages results in the development of simple fetal hydronephrosis [3,6]. It is put forward that frozen section biopsy can be a guide in determine of the renal pathology; however, in most cases, nephrectomy is suggested as the best approach [2]. Therefore, we examine the cause of the entire ureteral hypoplasia and the surgical strategy for the condition.

Unlike stenosis of the ureteropelvic junction or the ureterovesical junction, hypoplasia throughout the entire length of the ureter as seen in our case requires ureteroplasty of the whole ureter. In our case ureteroplasty was not performed because of the extremely narrow diameter of the ureter and the kidney scarring and atrophy. However, several attempts for ureteroplasty have been reported in the literature. El-Asmar have performed extensive pyeloplasty to reconstruct a new ureter. They reported two cases with good postoperative course, in which the new ureter was anastomosed with the urinary bladder [7]. In one case, renal scintigraphy showed a split kidney function of 10% on the affected kidney with no obstruction pattern. In the other case, a split kidney function on the affected side has improved from 22% to 28% after surgery. On the other hand, Allen reported three cases in which pyeloplasty was initially performed but nephrectomy was required as reoperation [2]. The reasons for reoperation were no urinary drainage from the affected kidney in one case, no improvement in hypertension in one case, and uncontrollable infection in one case. Fibrosis and atrophic scarring were confirmed in the removed kidneys, and dysplasia was also

observed in two cases. Therefore, the authors state that careful examination is necessary for ureteroplasty because extensive ureteral hypoplasia is often accompanied by renal dysplasia.

Based on the above findings, it is necessary to consider the possibility of renal dysplasia in patients with advanced ureteral hypoplasia or those with severe hydronephrosis from early pregnancy. As in our case, nephrectomy may be basically appropriate in patients with extensive ureteral hypoplasia and highly possible advanced renal dysplasia while ureteroplasty can be attempted in some patients.

Compliance with ethical statements

Conflicts of Interest: None.

Financial disclosure: None.

Consent: All photos were taken with parental consent.

References

- [1] Nguyen HT, Herndon A, Cooper C, et al. The society for fetal urology consensus statement on the evaluation and management of antenatal hydronephrosis. *J Pediatr Urol*. 2010; 6(3): 212-31.
- [2] Allen TD, Husmann DA. Ureteropelvic junction obstruction associated with ureteral hypoplasia. *J Urol*. 1989; 142(2 Pt 1): 353-55.
- [3] Glick PL, RH Harrison, Rhoda AN, Villa RL. Correction of congenital

hydronephrosis in utero III. Early Mid-trimester ureteral obstruction produces renal dysplasia. *J Pediatr Surg*. 1983; 18(6): 681-87.

- [4] Kiefer SM, Robbins L, Stumpff KM, Lin C, Ma L, Rauchman M. Sall1-dependent signals affect Wnt signaling and ureter tip fate to initiate kidney development. *Development*. 2010;137(18):3099-106.
- [5] Lee JW, You SH, Han DY, Jeong HJ, Choi DY, Oh YK. Retroperitoneoscopic nephrectomy for a horseshoe kidney with unilateral severe hydronephrosis and ureteral hypoplasia. *Korean J Urol*. 2009;50(5):512-15.
- [6] Beck AD. The effect of intra-uterine urinary obstruction upon the development of the fetal kidney. *J Urol*. 1971;105(6):784-49.
- [7] El-Asmar KM, El-Shafei EA, Abdel-Hay S. Using the renal flap to replace the whole hypoplastic ureter: a preliminary report. *Ann Pediatr Surg*. 2014;10(3):68-71.

