

**PEDIATRIC UROLOGY CASE REPORTS**

ISSN 2148-2969

<http://www.pediatricurologycasereports.com>**Quadriorchidism: A case of bilateral supernumerary testicle and review of the literature****Mehmet Sedat Durmaz<sup>1</sup>, Salih Hattapoglu<sup>2</sup>, Cihad Hamidi<sup>2</sup>, Cemil Goya<sup>2</sup>, Bora Ozbakir<sup>3</sup>**<sup>1</sup>Department of Radiology, Health Sciences University, Teaching and Research Hospital, Konya, Turkey<sup>2</sup>Department of Radiology Dicle University, Medical Faculty, Diyarbakir, Turkey<sup>3</sup>Department of Radiology, Gynecology-Obstetrics and Pediatrics Hospital, Isparta, Turkey**ABSTRACT**

Polyorchidism, which means one or more additional testicles, is a congenital anomaly and is seldom observed. In many polyorchidism patients, there is one supernumerary testicle (SNT) (triorchidism) whose left face is often the presentation. Two-sided SNT is very rare, and has been reported only in six cases. Here, we are presenting a male case who was six years old with bilaterally SNT (quadriorchidism) in scrotum that presented as asymptomatic masses.

**Key Words:** Supernumerary testicle; ultrasonography; quadriorchidism.

Copyright © 2018 [pediatricurologycasereports.com](http://www.pediatricurologycasereports.com)

**Corresponding Author:**

Dr. Mehmet Sedat Durmaz

Department of Radiology, Health Sciences University,  
Teaching and Research Hospital, Konya, Turkey

E-mail: [dr.msduzumaz@gmail.com](mailto:dr.msduzumaz@gmail.com)

Accepted for publication: 29 January 2018

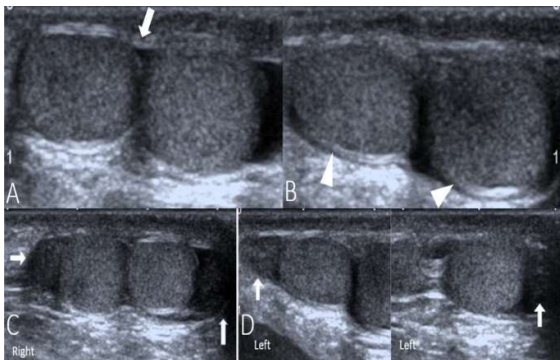
**Introduction**

Polyorchidism means there are one or more additional testicles. This congenital anomaly is seldom observed. In the literature, until our present day, 200 patients were reported. The most frequent presentation of polyorchidism is two homolateral and one contralateral (triorchidism) testicle [1, 2]. The left side is predominantly affected. Bilateral supernumerary testicle (SNT) is very rare, and

has been reported only in six cases [2, 3]. Nearly half of the patients were observed at 15-25 age range [4]. Many patients have no symptoms, and some of them present with painless inguinal or scrotal mass, undescended testicle, and more seldom, torsion of the SNT [5]. It may be related to cryptorchidism, testicular torsion and neoplasms [3, 6-9]. The SNT may be seen in a variety of ways in terms of its development and location. In some hypotheses, the development of SNT is due to the division occurring at embryonic stage. We would like to report a case of bilateral double testicles (quadriorchidism) with ultrasound (US) imaging findings presented as asymptomatic masses.

### Case report

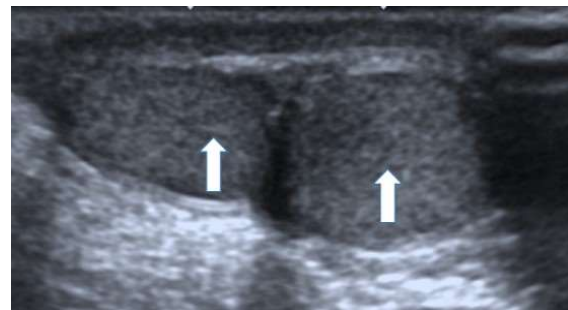
Scrotal US examination was performed with a high-frequency (4-14 MHz) linear array transducer with Toshiba Aplio 300 (Toshiba Medical System Corporation, Tokyo, Japan). Transverse scrotum scan was made for the correlation of the findings in orthogonal plane. The gray scale US showed a testicle on the bilateral side with an additional mass over it (SNT on each side of the hemiscrotum), with same echogenicity (isoechoic with testicle parenchyma), similar size consistent with a second testicle on bilateral side. During assessment of the bilateral hemiscrotal contents on right side scrotum there were two 11x7x10 mm and 13x7x12 mm, and on the left scrotum, there was two 11x6x9 mm and 14x8x12 mm isoechoic well-circumscribed oval structures (supernumerary testicle). Careful examination of the tunica vaginalis, tunica albuginea and epididymis were performed. In the right and left side, testicle and SNT was located in an odd tunica vaginalis. Each testicle had its own tunica albuginea, which made us discriminate each testicle one by one. All four testicles had a separate normal-appearing epididymis and draining the both testicles bilateral in hemiscrotum [Fig. 1]. A mediastinum testis in SNTs was also detected [Fig. 2].



**Fig. 1.** The gray scale US of scrotum shows a testicle on the bilateral side with an extra mass

over it (supernumerary testicle on each side of the hemiscrotum), with same echogenicity (supernumerary testicle has the same echogenicity as the testicle nearby), similar size consistent with a second testicle on bilateral side (A, B). Each side, testicle and supernumerary testicles are located in odd tunica vaginalis (arrow) (A). Transverse ultrasound of the scrotum demonstrating each testicle has its own tunica albuginea (arrow head), which made us discriminate each testicle one by one (B). Gray-scale longitudinal image of scrotum demonstrates that all four testicles have a separate normal-appearing epididymis (arrow) next to it (C and D).

On the basis of these characteristic sonographic imaging findings (intrascrotal location, ovoid shape, isoechoic parenchyma, similar sizes, having separate epididymis next to each, having mediastinum testis, similar doppler vascular pattern), a diagnosis of polyorchidism was considered.



**Fig. 2.** Sagittal ultrasound image of the scrotum right side showing two distinctly separated testicles, and both testicles have mediastinum.

The US examination showed no intra or extra-testicular masses nor any epididymal mass. There were no suspicious malignant features.

After the scrotal US, to rule out accompanying urogenital anomalies urinary and spleen US

were performed. Bilaterally renal sizes, parenchymal echogenicity, collecting system was normal. Spleen size and parenchyma was normal.

### Discussion

SNT may have scrotal, inguinal, or it may be present with a mal-descended testicle in abdominal location. The most frequently observed place of SNT is in scrotum, as superior/inferior to ipsilateral testicle. The dimension is frequently smaller than the two ipsilateral and contralateral testicles [10, 11]. In many polyorchidism patients, there is one SNT (triorchidism) with left side often [5, 11]. Bilateral SNT were also reported, but it is very rare. In the literature, 6 cases were reported [12].

The etiology for occurrence of polyorchidism may be associated with embryological and developmental anomaly when the testicles are formed [13, 14]. In nearly sixth week in embryological life, the primordial testicle starts to emerge from the medial aspect of primitive genital ridge, while the epididymis and vas deferens emerge from the Wolffian duct [15]. The most accepted theory of polyorchidism is thought to be due to anomalous division of genital ridge with/without mesonephros, prior to 8<sup>th</sup> gestational week sometimes through local accident and sometimes through development of peritoneal bands. Based on the segmentation plane and place, SNT can emerge with a common or single epididymis and vas deferens. In many patients, epididymis and vas deferens are shared or lacking [3, 6-9].

Based on embryologic development, polyorchidism is grouped into four classes. In type 1, the SNT lacks an epididymis and vas deferens. In type 2, the SNT has its epididymis. In type 3, the SNT has its epididymis sharing

the vas deferens with the regular testicle in a parallel way. Type 2 is the most frequent type, and with Type 3 constitutes 90% of the patients. In Type 4, there are 4 testicles (quadriorchidism) in bilateral scrotum which has separate own epididymis. In Type 4, there are testicles that are completely duplicated in SNT, epididymis and vas deferens because of complete longitudinal duplication of the genital ridge and mesonephric duct. Type 4 can be related to ipsilaterally duplicated ureter [5, 14]. Our case was consistent with type 4.

There can be comorbidities with polyorchidism like inguinal hernia, testicular mal-descent, testicular torsion, hydrocele, pain, hypospadias, persistent Muller duct, altered chromosomes, testicular cancer, microlithiasis and varicocele [1, 11]. The risk of malignancy is high if there is SNT. The polyorchid testicle is one of differential possibilities in extratesticular scrotal mass category. Definitive diagnosis involves spermatocele, hydrocele, epididymal cysts, fibrous pseudotumor, adenomatoid tumors, and papillary cystadenoma. In accessory testicle, the malignancy risk is increased [14]. Malign conversion can appear not depending on the place of SNT. The most common neoplasm in SNT is embryonal carcinoma, germ cell tumor, and seminomas [11]. Extratesticular rhabdomyosarcoma and adenoma of rete testes due to a supernumerary testicle were also observed [8].

Bergholz and Wenke examined 140 histologically patients who were confirmed about polyorchidism. Triorchidism was the most frequent type. Quadriorchidism was observed in six patients (4.3 %) [8].

The physical examination alone cannot accurately diagnose polyorchidism. When a polyorchidism is doubted of palpable mass in scrotum, US is the influential, non-invasive

modality to be used in its examination and evaluation. US can strongly suggest the diagnosis. On US, SNT shows a second, free-moving ovoid structure defined well with echo-pattern similar to that of the ipsilateral normal testicle. Color Doppler US of the SNT demonstrates flow features identical to the ones seen in the ipsilateral testicle. The color Doppler US appearance of polyorchidism is a scrotal oval mass with a flow identical to the one seen in normal testicles. A supernumerary epididymis adjacent to the SNT may be seen. Identification of the epididymis will appear as a tubular structure that is mildly inhomogeneous with mid to low-level echoes that run from the superior towards inferior poles of testicles. The presence of a mediastinum would confirm an SNT [2].

Polyorchidism is usually detected through US and confirmed by magnetic resonance imaging (MRI) [1]. MRI may be helpful to verify it especially when an US-based diagnosis is not definitive [2]. On MRI, SNT has the same features, typical signal characteristics (round or oval shaped structure that has a signal intensity that is homogeneous and intermediate on T1-weighted images and in T2-weighted images, high signal intensity) as a normal testicle [2, 16]. The extra testicle may be surrounded by a continuous low-signal intensity in both T1-and T2-weighted images and shows tunica albuginea. A mediastinum testis, which is visible in MRI, verifies that there is an SNT [11]. In uncomplicated polyorchidism patients, an MRI does not yield extra data to those yielded by US; however, it has a confirmative significance and a significant role in complicated cases like the ones associated with cryptorchidism and tumor. Yalçinkaya et al. [1] claimed that in many patients, US was diagnostic on its own. In our case, typical sonographic findings of

polyorchidism (ovoid structure that is defined well + an echo pattern identical to ipsilateral normal testicle, a supernumerary epididymis adjacent to the SNT, presence of a mediastinum, and similar vascular flow characteristics with ipsilateral testicle) were present. In our case, we did not need to perform MRI. The sonographic findings were typical for polyorchidism, and there were not any findings that suggested malignancy. For that reason, we thought that MRI would not give additional information for the diagnosis.

In conclusion, polyorchidism is a very rare congenital anomaly, and diagnosis of polyorchidism is usually incidental. In many polyorchidism patients, there is an SNT (triorchidism) and the left face is the most frequent presentation. Two-way SNT was reported as well, but it is very rare. We think our case with sonographic appearances will be included as an illustrative case in the literature.

### **Compliance with ethical statements**

*Conflicts of Interest:* None.

*Financial disclosure:* None.

*Consent:* All photos were taken with parental consent.

### **References**

- [1]Yalçinkaya S, Şahin C, Şahin AF. Polyorchidism: sonographic and magnetic resonance imaging findings. *Can Urol Assoc J.* 2011;5(5): 84–86.
- [2]Artul S, Habib G. Polyorchidism: two case reports and a review of the literature. *J Med Case Rep.* 2014; 25;8:464.
- [3]George Veloudis Nikolaos Pallas Andreas Zografidis Stavros Gourgiotis, Constantinos Villias. Bilateral polyorchidism associated with intraabdominal cryptorchidism: A case

- report. *Med Princ Pract*. 2009;18(2): 159–61.
- [4]Hwang S, Aronoff DR, Leonidas JC. Polyorchidism with torsion. *Radiology*. 2005;235(2): 433–35.
- [5]Leung AK. Polyorchidism. *Am Fam Physician*. 1988;38(3): 153–56.
- [6]Sheah K, Teh HS, Peh OH. Supernumerary testicle in a case of polyorchidism. *Ann Acad Med Singapore*. 2004;33(3):368-70.
- [7]Nocks BN. Polyorchidism with normal spermatogenesis and equal sized testes. A theory of embryological development. *J Urol*. 1978;120(5): 638-40.
- [8]Bergholz R, Wenke K. Polyorchidism: a meta-analysis. *J Urol*. 2009;182(5):2422–27.
- [9]Jorion JL, Wese FX, Hennebert P, Vandervaeren D, Clapuyt P, et al. Polyorchidism. Report of three cases and further embryological considerations. *Eur Urol*. 1990;17(1): 90-92.
- [10]Ferro F, Iacobelli B. Polyorchidism and torsion. A lesson from 2 cases. *J Pediatr Surg*. 2005;40(10): 1662–64.
- [11]Amodio JB, Maybody M, Slowotsky C, Fried K, Foresto C. Polyorchidism: report of 3 cases and review of the literature. *J Ultrasound Med*. 2004;23(7): 951–57.
- [12]Sozer IT, Kamberoglu H, Yucebas E. Polyorchidism, bilateral double testis and unilateral testicular torsion. *Br J Urol*. 1989;64(5): 546–47.
- [13]Arslanoglu A, Tuncel SA, Hamarat M. Polyorchidism. Color Doppler ultrasonography and magnetic resonance imaging findings. *Clin Imaging*. 2013;37(1): 189–91.
- [14]Singer BR, Donaldson JG, Jackson DS. Polyorchidism. Functional classification and management strategy. *Urology*. 1992;39(4): 384-88.
- [15]Wolf B, Youngson GG. Polyorchidism. *Pediatr Surg Int*. 1998;13(1): 65-6.
- [16]Akbar S, Sayyed T, Jafri S, Hasteh F, Simeon J. Multimodality imaging of paratesticular neoplasms and their rare mimics. *Radiographics*. 2003;23(6): 1461–76.
- [17]Thum G. Polyorchidism: case report and review of literature. *J Urol*. 1991;145(2): 370–72.

Access this article online

<http://pediatricurologycasereports.com>

Quick Response Code

