



PEDIATRIC UROLOGY CASE REPORTS

ISSN 2148-2969

<http://www.pediatricurologycasereports.com>



A new variant of urethral duplication- collateral urethral duplication with paraspadiac meatus: A case report

Prashant Mulawkar¹, Parag Tapre², Utpala Mulawkar³, Deepak Bhat⁴

Tirthankar Superspeciality Hospital, ¹Urology, ²Pediatric Surgery, ³Plastic Surgery and ⁴Anesthesiology, Gaddam Plots, Akola, Maharashtra, India

ABSTRACT

We report a case of isolated collateral urethral duplication with accessory urethra in paraspadiac location. Paraspadias is a congenital condition where the urethra opens on one side of penis. A four-year male child had collateral urethral duplication. One urinary meatus was located at normal apical position, whereas the other meatus was located on left side in paraspadiac collateral location. There was no other congenital malformation. The duplicated urethra was excised. Five cases of isolated collateral urethral duplication have been reported so far. We report the sixth such case and the first case of collateral urethra in paraspadiac location.

Key Words: Urethral duplication; collateral duplication; paraspadias; duplication of lower urinary tract.

Copyright © 2018 [pediatricurologycasereports.com](http://www.pediatricurologycasereports.com)

Corresponding Author: Dr. Prashant Mulawkar
Tirthankar Superspeciality Hospital, Department of
Urology, Gaddam Plots, Akola, Maharashtra, India
E-mail: pmulawkar@hotmail.com
Accepted for publication: 18 November 2017

Introduction

Urethral duplication is a rare anomaly. It usually presents with double urinary stream when the duplicated urethra is communicating with the urinary system. It usually occurs in sagittal plane when both the urethras are one behind the other. These can be in epispadiac or hypospadiac type [1].

Collateral urethral duplication, where two urethras are side by side, is still rarer anomaly.

It usually occurs with duplication of urinary bladder, midline defect or caudal duplication [2]. Collateral urethral duplication without associated midline anomaly is extremely rare [3]. In this type usually both the urethras open in glans. Paraspadias [4] as a congenital malformation is described in WHO manual 1948. It is a congenital condition where the urethra opens on one side of penis [5].

To the best of our knowledge, we report the first case of collateral urethral duplication with accessory urethra in paraspadiac location with no associated congenital anomalies. We also describe its management along with review of literature.

Case report

A four-year male child was referred to us with double urinary stream. There was no history of trauma or urethral instrumentation in past. Main stream was straight whereas another thin stream was directed on left side. This sometimes caused soiling of the clothes. There was no history of dysuria or urinary infections. There was no significant family or past history. On examination, he was uncircumcised. One urinary meatus was located at normal apical position, whereas the other meatus was located on left side in distal penile region in paraspadiac collateral location at 3'O clock position [Fig. 1].

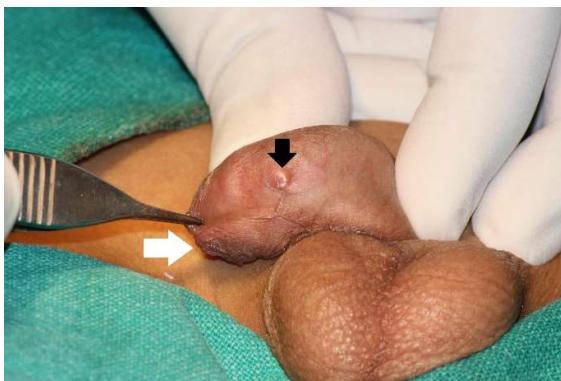


Fig. 1. Paraspadiac collateral urethra opening in distal penile region at 3 'O clock position marked by black arrow. Native urethral meatus is marked by white arrow.

The urine stream from the paraspadiac collateral meatus was weak [Fig. 2a]. Both the testes were well descended. There was no other congenital anomaly. His routine laboratory parameters were normal. Abdominal ultrasound confirmed normal kidneys and urinary bladder. There was no septum or diverticulum in bladder. There was no significant residual urine. Methylene blue injected from apical meatus was coming out through paraspadiac collateral meatus [Fig. 2b]. Micturating cystourethrogram was done

by filling the bladder through a 5 Fr feeding tube passed through the normally located meatus. Bladder was smooth in outlines.

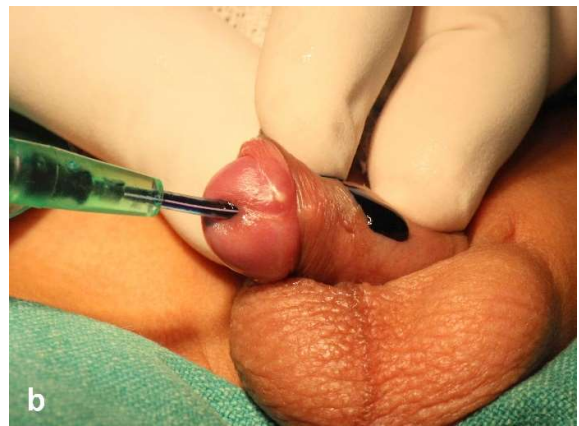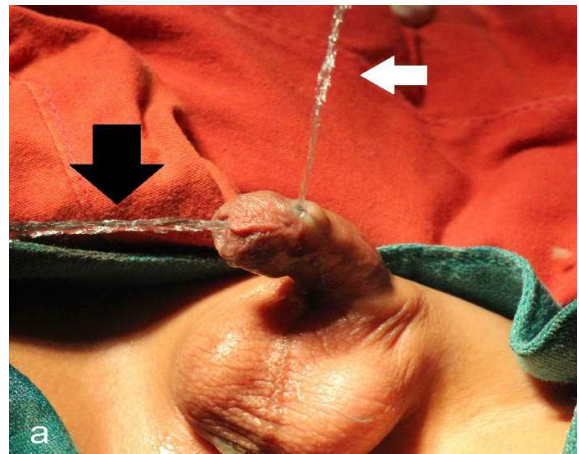


Fig. 2. a) Urinary stream from both the meatuses: White arrow points to stream from apical meatus, Black arrow points to stream from collateral meatus. **b)** Methylene blue injected from apical meatus coming out through paraspadiac collateral meatus.

There was no vesicoureteral reflux. There were two urinary streams coming from the penis. These two streams are better appreciated on the positive images of the x ray films [Fig. 3]. The child was posted for examination under anesthesia and surgery. A 0.035" hydrophilic (Terumo ® corporation, Japan) guide wire was passed through the paraspadiac collateral

meatus. It was seen in distal urethra on urethroscopy [Fig. 4].

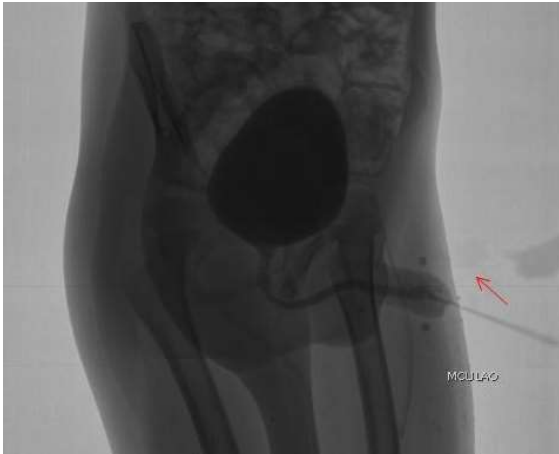


Fig. 3. Micturating cystourethrogram showing two streams, no reflux, smooth walled bladder.

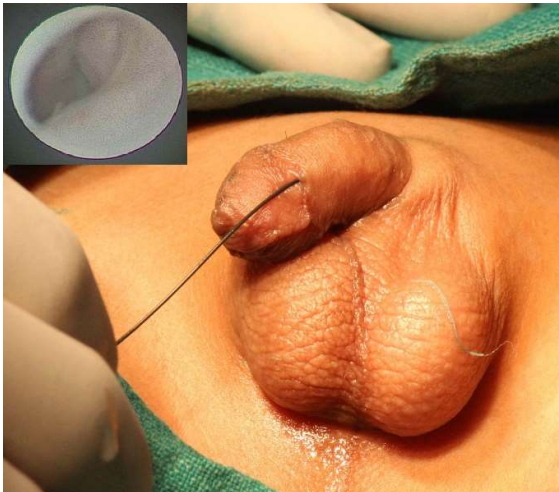

Fig. 4. Guidewire passed through collateral meatus is seen in urethra on urethroscopy (inset).

Rest of the urethra was normal. 6 Fr Foley catheter was passed through the main apical meatus. The paraspadiac collateral duplicated urethra was excised through a circular incision. It was excised up to native urethra. The collateral urethra was opening in the native urethra in its distal penile region [Fig. 5]. It was not coursing proximally up to bladder. The native urethra was repaired in single layer with

5-0 polydioxanone (PDS: Johnson & Johnson India) sutures. This was covered with a locally rotated layer of Buck's fascia in non-overlapping fashion, followed by skin closure.

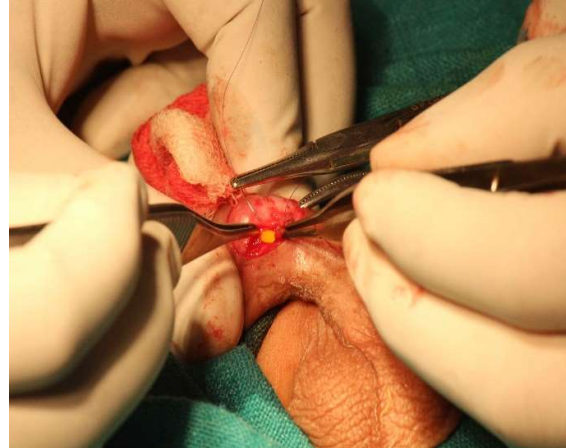

Fig. 5. Collateral urethra has been excised. Repair under process. Collateral urethra is opening in native distal penile urethra.

The patient is doing well at fourth month after surgery. He is passing urine in good stream from apical meatus in projectile stream without any fistula.

Discussion

Duplication of urethra is rare. No more than 500 cases have been reported so far [6,7]. Collateral urethral duplication, where two urethras are side by side, is still rarer anomaly. It usually occurs with duplication of urinary bladder, midline defect or caudal duplication. Anomalies associated with this are complete bladder duplication, thoracic hemivertebrae, supraleator imperforate anus, rectourethral fistula, vesicoureteral reflux, partial sacral agenesis [8] and duplication of external genitalia [2]. Collateral urethral duplication without associated midline anomaly is quite rare [3].

Many classifications for the duplication of urethra have been described but none of the

classifications have considered all possible variants. Effman [1,9] classification is the most widely used, which classified urethral duplication in three types; in type I the duplicated urethra is blind and incomplete. This is also called as accessory urethra. This is further subclassified as Type IA (proximal) and Type IB (distal). In type IA the accessory urethra opens on the dorsal or ventral surface of penis but does not communicate with the urethra or bladder. This is the most common type. This is usually asymptomatic and actual incidence is not known. In type IB the accessory urethra opens from the urethral channel and ends blindly in periurethral tissue. In this type there is only one urethral opening externally. It is difficult to differentiate this type from dilated Cowper's duct or narrow mouthed urethral diverticulum. Type II is called as complete patent type. This is subclassified in type IIA having two meatuses and type IIB having one meatus. Type IIA is further subclassified as IIA1 where two independent urethras arise from bladder and open externally in two different locations and IIA2 where the second channel arises from the main urethra and courses independently to a separate meatus. In type IIA2, the second urethra commonly arises from the first urethra in prostatic urethra. The second channel arising from distal urethra is rare. In type IIB, two urethras arise from either bladder or posterior urethra and unite distally to open in a single channel. Type III in Effman classification is urethral duplication as a part of complete or partial caudal duplication. Effman classification does not mention about collateral location of the second urethra and may not be applicable to collateral duplication. If we try to apply the Effman classification to our case, this patient comes closest to Type IIA2: a second urethral channel arising from the first and

ending in a separate meatus. Williams and Kenawi [10] classified the duplications in more common sagittal and less common collateral types. The sagittal is further classified into epispadiac (the most common), hypospadiac, spindle type and Y duplication. As per this Williams Kenawi classification, this patient fits into collateral type. Recently Lima et al [11] have proposed a new classification system for urethral duplication. This classification takes into consideration male as well as female urethral duplication and encompasses all types of duplications known. As far as male urethral duplication is concerned, Type 1 urethral duplication is the consequence of vesical duplication. Type 2 is one bladder two urethras. Type 3 is lambda (the so-called y duplication) and type 4 is miscellaneous. As per this classification, our case falls into Type 2 coronal incomplete. In this the coronal word is used for collateral duplication. As the collateral word is more commonly used, we have retained that nomenclature.

Five cases of isolated collateral urethral duplication have been reported so far. Urakami [12] is credited with the first report if such a case. 69-year male patient presented with double urinary stream since birth and lower urinary tract symptoms. The collateral meatus was opening on glans on right side. It was communicating with the main urethra in bulbar region. Patient underwent transurethral prostatic resection. Collateral duplicated urethra was not treated surgically. Walsh [13] reported a case of 20-year male with three episodes of retention of urine. He had a single urinary meatus and an accessory collateral passage on left side in posterior segment of anterior urethra. The retention episodes responded to medical therapy. Another report is by Frederik [14] of an 11 month boy who

underwent surgical approximation of distal urethras to create a single meatus. The next one is [15] 8 month old boy with two meatuses. He was asymptomatic and observed. Pastor Navarro [6] reported a case of 48 year married man with two children. He had two urethral meatuses on glans. The left one was collateral. Ejaculation and urination were present only from the right meatus. He presented with prostatitis and was treated with medications. Khaled [3] reported a 50 year old man who had collateral duplicated urethra opening on glans on right side. He used to ejaculate and urinate through both the meatuses. This patient also had adult polycystic disease of kidneys. His urethra was not treated surgically because he had end stage renal disease and was asymptomatic for urethral condition. To the best of our knowledge, we report the sixth case of collateral urethral duplication and the first case of collateral urethra in paraspadiac location with no associated congenital anomalies.

Conclusion

We describe a new variant of collateral urethral duplication with paraspadiac meatus.

Compliance with ethical statements

Conflicts of Interest: None.

Financial disclosure: None.

Consent: All photos were taken with parental consent.

References

- [1] Tiwari C, Bothra J, Kumbhar V, Shah H. A rare case of congenital Y-type urethral duplication. *Ped Urol Case Rep*. 2015;2(6):20-26.
- [2] AbouZeid AA, Safoury HS, Mohammad SA, et al. The double urethra: revisiting the

surgical classification. *Ther Adv Urol*. 2015;7(2):76-84.

- [3] Khaled DT, Saltzman AF, Prats LJ. Collateral urethral duplication in an adult with adult polycystic kidney disease. *Rev Urol*. 2016;18(4):242.
- [4] Congenital malformations. *Bulletin of the World Health Organization Supplement*. 1948;1:206-212.
- [5] <http://medical-dictionary.thefreedictionary.com/paraspadias>.
- [6] Pastor Navarro H, Carrion Lopez P, Martinez Ruiz J, Pastor Guzman JM, Salinas Sanchez AS, Virseda Rodriguez JA. Collateral urethral duplication in an adult. *Arch Esp Urol*. 2014;67(4):345-349.
- [7] Colin P, Ballereau C, Puech P, Gilliot P, Leroy X, Biserte J. [Urethral duplication in an adult. A case report]. *Prog Urol*. 2006;16(3):386-389.
- [8] Kennedy HA, Steidle CP, Mitchell ME, Rink RC. Collateral Urethral Duplication in the Frontal Plane: A Spectrum of Cases. *J Urol*. 1988;139(2):332-334.
- [9] Effmann EL, Lebowitz RL, Colodny AH. Duplication of the urethra. *Radiology*. 1976;119(1):179-185.
- [10] Williams DI, Kenawi MM. Urethral duplications in the male. *Eur Urol*. 1975;1(5):209-215.
- [11] Lima M, Destro F, Maffi M, Persichetti Proietti D, Ruggeri G. Practical and functional classification of the double urethra: A variable, complex and fascinating malformation observed in 20 patients. *J Pediatr Urol*. 2017;13(1):42.e1-42.e7.
- [12] Urakami S, Igawa M, Shiina H, et al. Congenital Collateral Urethral Duplication in the Frontal Plane. *J Urol*. 1999;162(6):2097-2098.
- [13] Walsh CA, Mulvin D. Collateral urethral

duplication in the frontal plane. *BJU Int.* 2003;92(SUPPL. 3):4189.

- [14] Frederick L, Benson AD. A case of coronal urethral duplication with no other abnormalities. *Can J Urol.* 2011;18(1):5557-9.
- [15] Ching CB, Palmer JS. Collateral urethral duplication. *Dialogues Pediatr Urol.* 2008;29(3):16-17.

