



## PEDIATRIC UROLOGY CASE REPORTS

ISSN 2148-2969

<http://www.pediatricurologycasereports.com>

### Ureteric diverticulum: A diagnostic challenge

**Rahul Kumar Gupta, Beejal Sanghvi, Gayatri Munghate, Sonali Mane,  
Pooja Tiwari, Kedar Mudkhedkar, Sandesh V Parelkar**

*Department of Pediatric Surgery, Seth GSMC and KEM Hospital, Mumbai, India*

#### ABSTRACT

Ureteric diverticulum is a rare urological condition with only 47 cases described in the literature till 2013. A full term female infant presented with a huge cystic lump occupying almost the entire right side of the abdomen at 1 month of age. Ultrasonography and Magnetic Resonance Urography (MRU) revealed right sided gross hydronephrosis with pelvis appeared folded onto itself along with left sided mild hydronephrosis. On EC scan, differential function of right sided kidney was 0.9%. With working diagnosis of right sided giant hydronephrosis secondary to pelviureteric junction obstruction, the child was posted for Anderson - Hynes pyeloplasty through right flank incision. On exploration we were surprised to find ureteric diverticula. Excision of ureteric diverticulum with proximal ureterostomy was done. Distal part of ureter was transfixed. Histopathological examination of diverticulum showed presence of fibromuscular wall suggestive of true diverticulum. Since ureterostomy was draining only few drops of clear fluid and on repeat EC scan there was no improvement in function of right kidney, right nephroureterectomy was done after 6 months.

**Key Words:** Ureteric diverticula, pediatric age group, giant hydronephrosis.

*Copyright © 2017 pediatricurologycasereports.com*

**Corresponding Author:** Dr. Rahul Kumar Gupta  
*Department of Pediatric Surgery, Seth GSMC and  
KEM Hospital, Mumbai 400012, India  
E-mail: [drrahulg78@yahoo.co.in](mailto:drrahulg78@yahoo.co.in)  
Accepted for publication: 29 September 2017*

#### Introduction

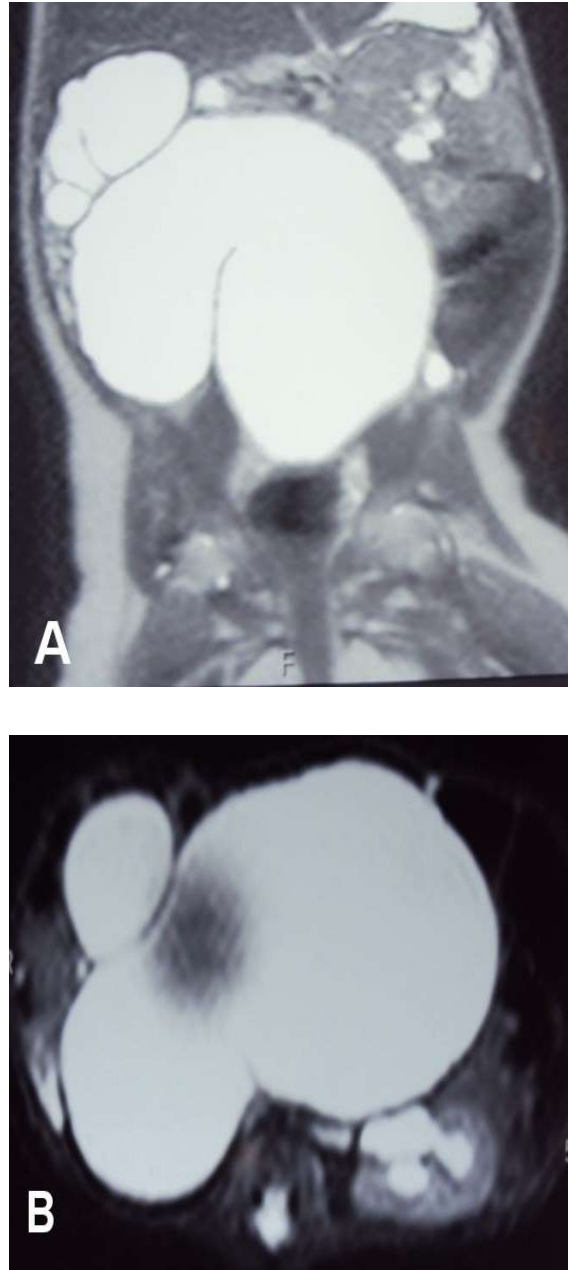
Ureteric diverticulum is a rare urological condition with only 47 cases described in the literature till 2013 [1]. These cases varied in their presentation, diagnosis and management. We report index case with massive abdominal distention caused by mid ureteric diverticulum

along with the diagnostic dilemma faced by us while managing this child. Cope and Snow reported two cases of massive cystic ureteric diverticula with distal obstruction in infancy [2]. To our knowledge, this is the third case in English literature which is detected in infancy with massive cystic ureteric diverticulum.

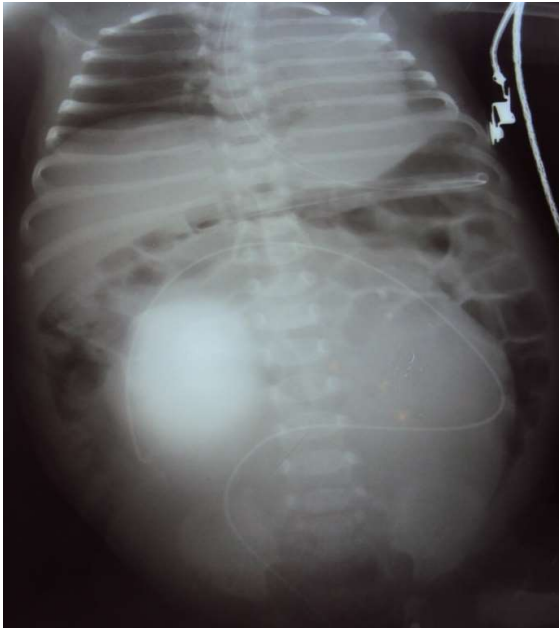#### Case report

A full term female infant presented with a huge cystic lump occupying almost the entire right side of the abdomen at 1 month of age.

She was diagnosed antenatally at 27 weeks of gestation to have right sided gross hydronephrosis with anteroposterior diameter of pelvis as 2.4 cm with no hydroureter. Left kidney, ureter was normal and liquor was adequate. Ultrasonography report at 37 weeks of gestation showed right sided gross hydronephrosis with anteroposterior diameter of pelvis 7 cm with right sided hydroureter with mild left hydronephrosis with no hydroureter. Bladder could not be visualized because of the massive right hydronephrosis. Postnatal ultrasound revealed that the right kidney was replaced by large hydronephrotic sac with renal pelvis reaching up to urinary bladder with anteroposterior diameter of 6.4cm with paper thinning of renal parenchyma suggestive of right pelviureteric junction obstruction. Left kidney showed mild hydronephrosis, with AP diameter of 1.3cm. Voiding- cystourethrogram was normal. Suspecting right side giant hydronephrosis, Magnetic Resonance Urography (MRU) was done to confirm the diagnosis. It revealed right sided gross hydronephrosis with thinned out parenchyma measuring 3mm in upper pole and 4mm in middle pole due to pelviureteric junction obstruction, with AP diameter of 5.1 cm. The pelvis appeared folded onto itself along with left sided mild hydronephrosis [Fig 1A,B]. On cystoscopy both ureteric orifices were seen and were normal. On ascending ureterogram ureteric stent appeared to be coiled in pelvis [Fig 2]. On EC scan, differential function of right sided kidney was 0.9% and level of obstruction was difficult to comment on due to poor filling of pelvicalyceal system. Left renogram curve showed normal cortical and prolonged non-obstructed excretory phases.



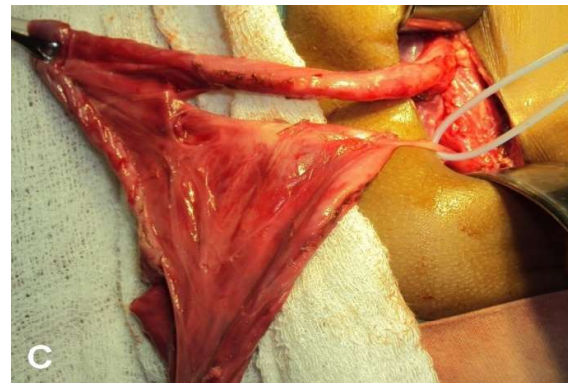
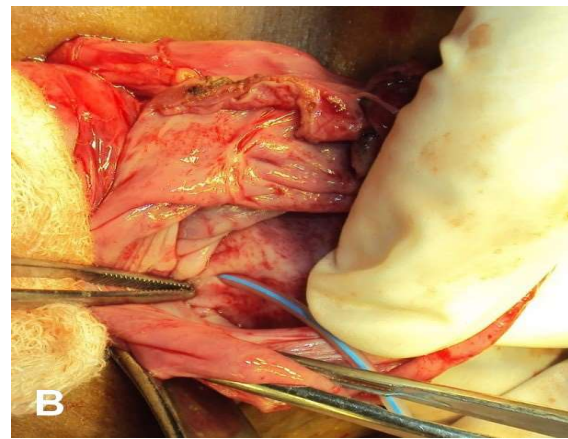
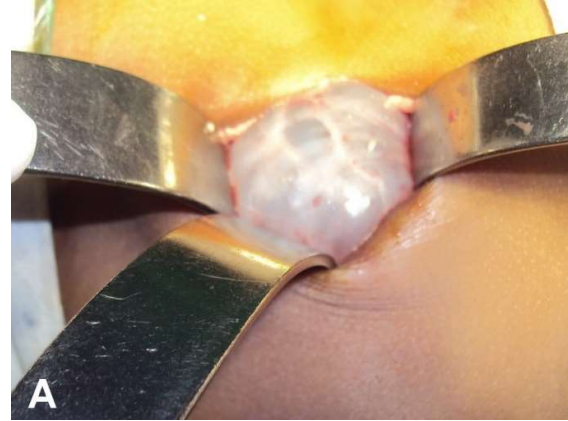**Fig. 1. A)** MR Urography (coronal section) showing grossly dilated Right renal pelvis due to pelviureteric junction obstruction which appears folded upon itself and left hydronephrosis. **B)** MR Urography (sagittal section) showing grossly dilated Right renal pelvis due to pelviureteric junction obstruction which appears folded upon itself and left hydronephrosis.



**Fig. 2.** Ascending ureterogram showing ureteric stent appeared to be coiled in the dilated pelvis.

With working diagnosis of Right sided giant hydronephrosis secondary to pelviureteric junction obstruction, the child was posted for Anderson - Hynes pyeloplasty through right flank incision. After opening the Gerota's fascia, we found a large cystic structure which was thought to be a grossly hydronephrotic kidney with thinned out renal parenchyma [Fig. 3A]. After decompression of cystic mass, we could see a narrow ureter going down towards pelvis. We hooked the junction of ureter with the cystic mass thinking it to be the pelviureteric junction, with a plan of pyeloplasty. We opened the "pelvis" to reduce its size. There was a tiny opening in the upper part of cystic structure. We cannulated that opening with a small tube [Fig. 3B]. It led to another tubular structure going upwards from this cystic structure. At this moment, we wondered whether we were dealing with duplex system. But on further dissection, we were surprised to find that this tubular structure was infact ureter. Thus, finally we identified

right sided small kidney with proximal 5cm length of good calibre ureter, midureter which was replaced by huge cystic diverticulum measuring approximately 7x7cm, distal ureter 1cm in length [Fig. 3C].



**Fig. 3. A)** Multiloculated cystic structure after opening the Gerota's fascia mimicking thinned out renal parenchyma. **B)** Post decompression and after opening the cystic structure, a tiny opening being cannulated with infant feeding tube. **C)** Diverticulum with proximal ureter and distal narrow ureter hooked by sling.

Finally, we had the diagnosis of ureteric diverticulum which was communicating with both proximal and distal part of ureter. Since she was only 2 months old, with the attempt to salvage the function of kidney, excision of ureteric diverticulum with proximal ureterostomy was done. Distal part of ureter was transfixed. Histopathological examination of diverticulum showed presence of fibromuscular wall suggestive of true diverticulum. Since ureterostomy was draining only few drops of clear fluid and on repeat EC scan there was no improvement in function of right kidney. Differential function and ERPF of right kidney were 2.6% and 5.22 ml/min respectively. ERPF of left kidney was 187.5 ml/min. Left renogram shows normal cortical and prolonged non-obstructed excretory phases hence Right nephroureterectomy was done.

### Discussion

First case of ureteric diverticula was described by Peper in 1808. Ureteric diverticulum is an extremely rare urological condition. On review of literature, we have encountered only 47 cases of this rare anomaly [1]. In 1947, Culp classified them into congenital and acquired [3]. Congenital diverticula contain all tissue layers of the normal ureter with size usually more than 0.5 cm and single, whereas acquired diverticula represent mucosal herniation through the defect in the ureteric wall. Acquired ureteric diverticula are usually single and larger than pseudodiverticula which are small and multiple. Holly and Sumcad first described the entity of pseudodiverticulosis in 1957 [4]. According to Rank and associates, ureteric diverticula are merely extra extension of bifid ureters [5]. On the other hand, acquired ureteric diverticulum develops due to distally obstructed ureter which could be due to any

pathology like distal calculus, strictures causing increase in pressures resulting into diverticulum. These patients usually present with symptoms of flank pain and fever, similar to patients of ureteric strictures, ureteric valve and fibroepithelial polyps [6,7,8]. Ureteric calculi may also occur in conjunction with true congenital diverticulum [9]. It has been described by Franco et al. [10] that fibroepithelial polyps and congenital diverticula of the ureter are part of a spectrum of the same developmental anomaly. Majority of cases of ureteric diverticulum are completely asymptomatic and present as an incidental finding on imaging [11]. However sometimes patients can have painless hematuria as presenting feature [9,11].

Radiological investigations are mainstay of diagnosis [1]. Ultrasonography was initially advocated by Wan et.al [10] whereas Herndon described the first case of antenatally detected ureteric diverticulum with use of antenatal ultrasound [6]. CT is generally used in symptomatic cases. Use of magnetic resonance imaging was reported in diagnosis [1]. In our case, we used all radiological investigations like USG, MRI, ascending ureterogram which were suggestive of gross hydronephrosis. None of the investigations had diagnosed the condition of ureteric diverticulum because of the rare incidence of this condition.

Asymptomatic cases usually do not require any surgical intervention [1,11]. Treatment is required only in cases where the diverticulum is cause of the symptoms like pain or associated with some distal obstruction like stricture or stone.

Initial case reports advocate nephroureterectomy in management of ureteric diverticulum [3], however segmental resection of diverticulum with end to end ureteric anastomosis is the procedure of choice,



recently [2]. In 2006, Li et al. [13] described the use of laparoscopy in the management of acquired ureteric diverticulum.

Overall prognosis of uncomplicated untreated ureteric diverticula is excellent [11,12]. However perforation of diverticulum as well as transitional cell carcinoma in ureteric diverticulum have been reported in literature if left untreated [14,15].

### Conclusion

Ureteric diverticulum is extremely rare condition in pediatric age group. A very high index of suspicion is needed in the diagnosis. Symptomatic patients, as the presented case, require surgical intervention.

### Acknowledgements

The author(s) declare that they have no competing interest and financial support.

### References

- [1] Mcloughlin LC, Davis NF, Dowling C, Eng MP, Power RE. Ureteral diverticulum: review of the current literature. *Can J Urol*. 2013; 20(5):6893-6.
- [2] Cope RM, Snow BW. Massive cystic ureteral diverticula in infancy. *J Urol*. 1991; 146 (2(pt2)):575-7.
- [3] Culp OS. Ureteral diverticulum: classification of the literature and report of an authentic case. *J Urol*. 1947; 58(5):309-21.
- [4] Holly LE 2<sup>nd</sup>, Sumcad B. Diverticular ureteral changes: a report of four cases. *Am J Roentgenol Radium Ther Nucl Med*. 1957; 78(8):1053-60.
- [5] Rank WB, Mellinger GT, Spiro E. Ureteral diverticula: etiologic considerations. *J Urol*. 1960; 83:566- 8.
- [6] Herndon CD, McKenna PH. Antenatally detected proximal ureteral diverticulum. *Urology* 2000; 55(5):774.
- [7] Horebeek IV, Wyndaele M, Verlinde P, Ost D, Cherian A, Win De G, Trouet D. Fibroepithelial ureteral polyps as a cause of ureteropelvic junction obstruction in children: A case report. *Ped Urol Case Rep*. 2016; 3(5):147-152.
- [8] Bhatnagar S. Ureteral valve masquerading as obstructive megaureter. *Ped Urol Case Rep*. 2017; 4(3):325-328.
- [9] Mori C, Yamada D, Homma Y. A case of calculus in the true ureteral diverticulum. *Int J Urol*. 2011; 18(2):180-181.
- [10] Franco I, Choudhury M, Eshghi M, Bhalodi A, Addonizio JC. Fibroepithelial polyp associated with congenital ureteral diverticulum: report of 2 cases. *J Urol*. 1988; 140(3):598-600.
- [11] Barrett DM, Malek RS. Ureteral diverticulum. *J Urol*. 1975; 114 (1):33-35.
- [12] Wan YL, Hsieh ML, Hsueh C, Shum HC, Kea CL. Sonographic diagnosis of a ureteral diverticulum. *J Ultrasound Med*. 1996; 15(6):483-485.
- [13] Li JR, Chiu KY, Lin HM, Cheng CL, Yang CR, Hung SW. Laparoscopic excision of a ureteral diverticulum. *Int J Urol*. 2006; 13(7):995-996.
- [14] Cappellani A, Di Vita M, Zanghi A, Lo Menzo E, Conti P. Perforation of a ureteral diverticulum: a case report and review of the literature. *Annali italiani di chirurgia* 2003; 74[3]:349-352; discussion 52-53.

- [15] Harrison GSM. Transitional cell carcinoma in a congenital ureteral diverticulum. *J Urol*. 1983; 129(6):1231-2.

Access this article online
<a href="http://pediatricurologycasereports.com">http://pediatricurologycasereports.com</a>
Quick Response Code
