

**PEDIATRIC UROLOGY CASE REPORTS**

ISSN 2148-2969

<http://www.pediatricurologycasereports.com>**Extrusion of peritoneal end of ventriculoperitoneal shunt through urethra in an infant: A rare complication****Kamal Nain Rattan, Rashmi Hooda, Ahmad Khursheed, Surbhi Gupta***Department of Pediatric Surgery, PGIMS, Rohtak, Haryana, India***ABSTRACT**

Ventriculoperitoneal (VP) shunt is a common procedure performed in the management of hydrocephalus in children. The peritoneal end of the shunt can migrate in the peritoneal cavity and extrude through the mouth, umbilicus, anus, vagina or urethra after injuring the overlying structures. Timely removal is necessary to prevent transmission of infection. We are reporting a case in which there is extrusion of shunt per urethra.

**Key Words:** Hydrocephalus; ventriculoperitoneal shunt, extrusion; per urethra.

*Copyright © 2017 pediatricurologycasereports.com*

**Corresponding Author:** Dr. Rashmi Hooda

*Department of Pediatric Surgery, PGIMS  
Rohtak, Haryana, India*

*E-mail: [rashmihooda112@gmail.com](mailto:rashmihooda112@gmail.com)*

*Accepted for publication: 13 September 2017*

**Introduction**

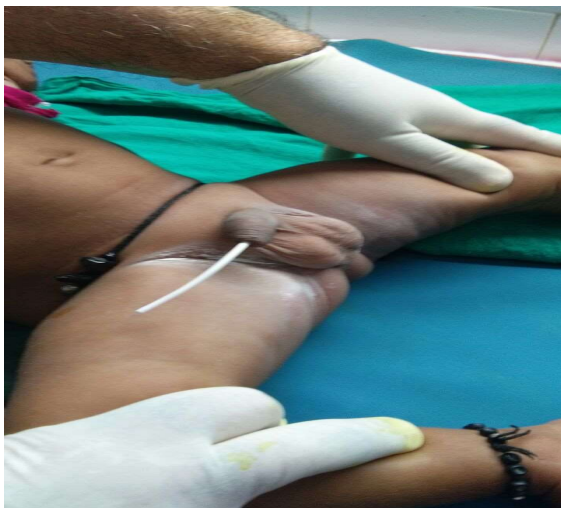
Hydrocephalus is commonly managed by ventriculoperitoneal (VP) shunt. The first successful introduction of ventriculoperitoneal shunt was done by Hartwell in 1910, using a silver wire. This is quite a safe procedure except for some complications. The complications related to this include shunt obstruction, infection, and ascites, shunt migration, perforation of viscus, skin or other body cavities. Shunt migration resulting in extrusion of peritoneal end of shunt through urethra is a rare complication. It was first described way back in 1974 by Grosfeld et al [1] who reported two instances of bladder

perforation along with two cases of bowel perforation. Since then, 20 more cases of bladder perforation have been reported.

**Case report**

We present the case of a child admitted in a tertiary care hospital in the department of pediatric surgery. The child presented with congenital severe obstructive hydrocephalus. Cranial sonography (USG) and computerized tomography (CT) head showed gross dilatation of ventricles. Right VP shunt was performed. In follow up, the child was well till 10 months. At 10 months of age, the patient presented with the complaints of tip of the catheter coming out per urethra in the casualty [Fig. 1]. Patient was passing urine normally. There were no complaints of fever, irritability or excessive crying while micturition. The catheter tip was visible 4 cm outside the urethra. USG abdomen

was done to rule out any vesical calculi. The shunt was removed through an incision in post auricular area, under local anesthesia; the chamber was identified and the whole shunt was pulled out through the incision wound and wound was closed in single layer. Postoperatively, the child had seizures which were aborted with antiepileptics. Antibiotics were given for 10 days. Postoperatively, abdominal ultrasound showed no urinary leak or evidence of bladder injury. There was no increase in head size or ventriculomegaly on cranial ultrasound. CT scan head showed no evidence of hydrocephalus. The child was discharged on postoperative day 10 with advice for close follow up in OPD after 1 week for hydrocephalus.



**Fig. 1.** Male infant with ventriculoperitoneal shunt coming out per urethra.

### Discussion

The peritoneal end of the catheter can perforate the bladder and hence can get retained there acting as a foreign body and a nidus for calculus formation. This has been described in 5 case reports previously [2-6]. It can present with obstructive symptoms reported in two patients. In the index case, there were no

obstructive symptoms or vesical calculi. It can come out to be visible externally through urethra, which has been reported in 12 patients previously [7-18]. This can be asymptomatic as in our case or it can present with urinary symptoms like urinary incontinence [19] or hematuria [20]. Shunt infection can either present with features of meningitis, peritonitis or urinary tract infection [18,21]. This could result due to respiratory movements resulting in erosion of peritoneal membrane and resulting fibrosis. It can erode bladder wall to come out through the urethra. This theory has not been substantiated by research. We need better understanding of the mechanisms resulting in these complications by perhaps using animal models.

This extrusion can be managed by removal through laparotomy incision/cystoscopy/retro-auricular route. However, our approach is much simpler than the previously reported ones. We removed it through the bulb through a retro-auricular incision under local anesthesia. There were no complications seen in our patient.

### Conclusion

In our opinion, the VP shunt can be removed through an incision in the post auricular region above the bulb, without doing laparotomy or cystoscopy. The bladder perforation undergoes spontaneous closure.

### Acknowledgements

The author(s) declare that they have no competing interest and financial support.

### References

- [1] Grosfeld JL, Cooney DR, Smith J, Campbell RL. Intraabdominal complications following

- ventriculoperitoneal shunt procedures. *Pediatrics*. 1974; 54(6):791–6.
- [2] Eichel L, Allende R, Mevorach RA, Hulbert WC, Rabinowitz R. Bladder calculus formation and urinary retention secondary to perforation of a normal bladder by a ventriculoperitoneal shunt. *Urology*. 2002; 60(2): 344.
- [3] Ibrahim AK. Urinary bladder stone complicating ventriculovesical shunt. *Sultan Qaboos Univ Med J*. 2014; 14(1):e142–4.
- [4] Ramana Murthy KV, Jayaram Reddy S, Prasad DVSRK. Perforation of the distal end of the ventriculoperitoneal shunt into the bladder with calculus formation. *Pediatr Neurosurg*. 2009; 45(1):53–5.
- [5] Gupta R, Dagla R, Agrawal LD, Sharma P. Vesical calculi formation on the slit valves of migrated distal end of ventriculoperitoneal shunt. *J Pediatr Neurosci*. 2015; 10(4): 368-70.
- [6] Butler L, Keys C, Lam JPH. Bladder calculus formation on the tip of a migrated disused ventriculoperitoneal shunt. *J Pediatr Surg*. 2013; 48(5):E1–3.
- [7] De Aguiar GB, Mizrahi C, Aquino JHW, Tavares CM, Telles C, Nigri F, et al. Urethral extrusion of a peritoneal catheter in a patient with neobladder: a rare complication of shunt insertion. *Neuropediatrics*. 2011; 42(3):124–7.
- [8] Kataria R, Sinha VD, Chopra S, Gupta A, Vyas N. Urinary bladder perforation, intracorporeal knotting and per-urethral extrusion of ventriculoperitoneal shunt in a single patient: case report and review of literature. *Childs Nerv Syst*. 2013; 29(4):693–7.
- [9] Mihajlovic M, Tasic G, Raicevic M, Mrdak M, Petrovic B, Radlovic V. Asymptomatic perforation of large bowel and urinary bladder as a complication of ventriculoperitoneal shunt: report of two cases. *Srp Arh Celok Lek*. 2012; 140(3-4):211–5.
- [10] Pohlman GD, Wilcox DT, Hankinson TC. Erosive bladder perforation as a complication of ventriculoperitoneal shunt with extrusion from the urethral meatus: case report and literature review. *Pediatr Neurosurg*. 2011; 47(3):223–6.
- [11] Prasad VSSV, Krishna AM, Gupta PK. Extrusion of peritoneal catheter of ventriculoperitoneal shunt through the urethra. *Br J Neurosurg*. 1995; 95(2):209–10.
- [12] Surchev J, Georgiev K, Enchev Y, Avramov. Extremely rare complications in cerebrospinal fluid shunt operations. *J Neurosurg Sci*. 2002; 46(2):100–2.
- [13] Ueda Y, Kakino S, Hashimoto O, Imoto K. Perforation of the bladder by a peritoneal catheter: an unusual late complication of ventriculo-peritoneal shunt. *No Shinkei Geka*. 1998; 26(5):413–6.
- [14] Yazar U, Kanat A, Akca N, Gazioglu G, Arda I, Kazdal H. Urethral protrusion of the abdominal catheter of ventriculoperitoneal shunt: case report of extremely rare complication. *J Pediatr Neurosci*. 2012; 7(2):111–3.
- [15] Mutlu M, Kader S, Aslan Y, Yazar U, Imamoglu M. An acute complication of ventriculoperitoneal shunt with bladder perforation and extrusion through the urethra in a newborn: case report and review of literature. *Pediatr Neurosurg*. 2014; 50(5): 264-9.
- [16] Park S, Lee KS, Lee KC. Perforation of urinary bladder by distal catheter: a rare complication of ventriculoperitoneal shunt. *J Korean Neurosurg Soc*. 1984; 13: 563-5

- [17] Miranda ME, Sousa MB, Tatsuo ES, Quites LV, Giannetti AV. Bladder perforation by ventriculoperitoneal shunt. *Childs Nerv Syst*. 2016; 32(12): 2321-6.
- [18] Chen TH, Lin MS, Kung WM, Hung KS, Chiang YH, Chen CH. Combined ventriculoperitoneal shunt blockage, viscus perforation and migration into urethra, presenting with repeated urinary tract infection. *Ann R Coll Surg Engl*. 2011; 93(7):e151-3.
- [19] See MC, Chua ME, Dy JS. A rare case of pediatric urinary incontinence: ventriculoperitoneal shunt with bladder perforation. *Ped Urol Case Rep*. 2016; 3(3): 76-83.
- [20] Binning MJ, Ragel BT, Walker ML, Kestle JR. Retained peritoneal shunt tubing causing hematuria. Case illustration. *J Neurosurg Pediatr*. 2006; 104(6):434.
- [21] Yerkes EB, Rink RC, Cain MP, Luerssen TG, Casale AJ. Shunt infection and malfunction after augmentation cystoplasty. *J Urol*. 2001; 165(6 Pt 2):2262-4.

