

**PEDIATRIC UROLOGY CASE REPORTS**

ISSN 2148-2969

<http://www.pediatricurologycasereports.com>**Ectopic adrenal tissue of spermatic cord in a 3- year- old boy, an incidental finding during orchidopexy: A case report****Biserka Pigac¹, Silvija Mašić², Slavko Gašparov³, Valentina Mašić⁴**¹*Pathology, Cytology and Forensic Medicine Unit, Varaždin General Hospital, Varaždin, Croatia*²*Clinic for Oncology and Nuclear Medicine, University Hospital Centre Sestre Milosrdnice, Zagreb, Croatia*³*Department of Pathology and Cytology, Clinical Hospital Merkur, Zagreb, Croatia*⁴*Training and Education Center 'Vinko Bek', Zagreb, Croatia***ABSTRACT**

Ectopic adrenal tissue is usually found in kidney and retroperitoneum, yet other locations are considered uncommon. Spermatic cord remains one of the sites where this entity is mostly incidentally found during surgical procedure in childhood. Macroscopically, it represents as yellowish, lipomatous nodule. We present a case of ectopic adrenal tissue of spermatic cord in a 3-year-old boy, found during orchidopexy of the right testicle. Histopathological analysis of the spermatic cord nodule revealed adrenal cortical tissue composed of zona fasciculata cells. Although usually being benign and asymptomatic, cases of hyperplasia, adenoma and carcinoma arising from ectopic adrenal tissue have been reported. Therefore, removal of this tissue, when detected, is recommended.

Key Words: Ectopic adrenocortical tissue; spermatic cord; undescended testis.

Copyright © 2017 pediatricurologycasereports.com

Corresponding Author: Dr. Silvija Mašić

Clinic for Oncology and Nuclear Medicine, University Hospital Centre Sestre Milosrdnice, Zagreb, Croatia

E-mail: silvijamasic57@gmail.com

Accepted for publication: 20 September 2017

Introduction

Adrenal tissue found in spermatic cord represents an uncommon occurrence [1]. Incidence of this finding varies from 1.6% to 5.1% in cases of children with undescended testes [1]. Other sites where ectopic adrenal

tissue has been noticed include: kidney, placenta, ovary, mesosalpinx, coeliac axis, lungs, liver, intracranial lesions, pancreas, colon, stomach, retroperitoneum, supradiaphragmatic area [1-5]. It is usually benign asymptomatic entity [4,6,7] and therefore, mostly incidentally found while performing surgical procedure [4,5,8,9].

We report a case of ectopic adrenal tissue of spermatic cord in a 3-year-old boy, incidentally found during orchidopexy of the right testicle.

Case report

Here, a 3-year-old boy was presented, who underwent orchidopexy due to undescended right testes. Although by birth being declared as having both testicles in the scrotum, 3 years later the boy's parents asked for medical assistance since they noticed painless, movable lump in the right inguinal canal. In manual inguinal examination, the right testis was found in high scrotal location. Additionally, surgical examination pointed out that inguinal hernia was actually testicle, which could have only partially been descended to the scrotum, since it immediately retracted to the inguinal canal. Therefore, orchidopexy was recommended and performed shortly after the initial examination. During the surgical procedure, an oval nodule, 0.5 cm in its longest diameter in the area of spermatic cord was found. Macroscopically, it appeared yellowish, lipomatous and soft in consistency.

Histologically, hematoxylin and eosin stain revealed adipose tissue surrounding a sharply demarcated nodule composed of adrenal gland cortical tissue, mostly zona fasciculata cells, which was normal in appearance. No segments of adrenal medulla were found [Fig. 1A-C].

Postoperative course was uneventful. No other anomalies or hormonal disturbances have been found. Follow-up one month after the surgery demonstrated a healthy boy with both testicles placed in the scrotum.

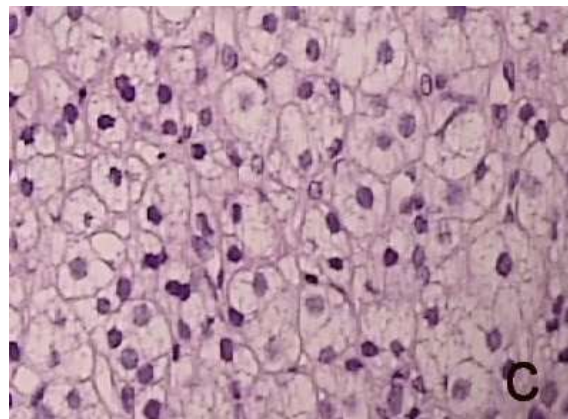
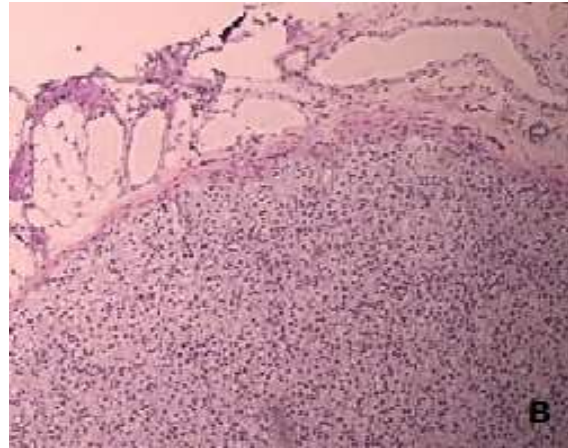
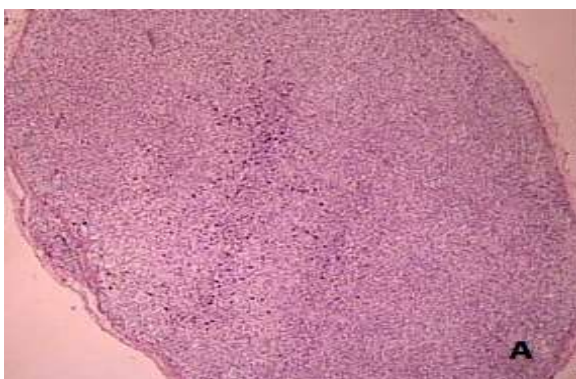


Fig. 1A-C. Histological appearance (H&E). Adipose tissue surrounding sharply demarcated nodule composed of adrenal gland cortical tissue, mostly zona fasciculata cells, which was normal in appearance.

Discussion

The entity of ectopic adrenal gland was first mentioned by Morgagni in 1740, who noticed yellow nodules in adrenal gland environment [3,5]. It is believed that in 50% of newborns, ectopic adrenal tissue can be encountered [1,9]. Aging process leads to its atrophy, so it remains intact in rare cases only [1,9].

Explanation of adrenal tissue displacement in spermatic cord lies in the fact that gonads and adrenal primordium are spatially close to one another during embryological development and therefore, some of adrenal cortical cells

separate and join gonadal tissue during its descending [3]. Another theory explains the origin of this entity to be from pluripotent stem cells [6].

Grossly, ectopic adrenal appears as yellow nodule that resembles adipose tissue lobule and is usually well-demarcated and surrounded by capsule composed of connective tissue [3,10]. Surgeon can suspect of ectopic adrenal tissue based on its macroscopic appearance, however, diagnosis should be confirmed histopathologically [3,4]. Microscopically, ectopic tissue usually contains only elements of adrenal cortex, but in some cases, parts of medulla can be found [1]. Whether cortical or medullar tissue comprises ectopic adrenal, depends on the time when segment of primitive adrenal separates [11]. If the event occurs before junction of medulla and cortex, only cortical tissue is found in ectopic sites [11].

Ectopic adrenal tissue usually causes no symptoms, however, hyperplasia, adenomatous and neoplastic changes of the tissue can occur, leading to development of paraganglioma, adrenocortical carcinoma, pheochromocytoma, adrenal adenoma or Leydig cell's tumor [3,6,9,12]. It usually remains indolent concerning hormonal production, still cases of hormonally active ectopic adrenal tissue were mentioned in the literature, pointing out to possible Cushing's syndrome development [6,10]. In patients with functionally damaged adrenal glands or excessive production of adrenocorticotrophic hormone, hyperplasia of ectopic tissue can be encountered [1,5]. Also, another important thing to mention is, that it should not be confused for tumor metastasis [3,6].

Ectopic adrenal tissue usually appears as an incidental finding during surgery. According to literature, despite its benign behavior,

recommendation to remove ectopic adrenal tissue when discovered remains [8,7,13], since they are associated with hyperplasia and neoplastic change [1,5]. However, a routine search for them is not mandatory.

Acknowledgements

The author(s) declare that they have no competing interest and financial support.

References

- [1] Mendez R, Tellado MG, Somoza I, Liras J, Sanchez-Abuin A, Pais E et al. Ectopic adrenal tissue in the spermatic cord in pediatric patients: surgical implications. *Int Braz J Urol*. 2006;32(2):202-207.
- [2] Ventura L, Leocata P, Hind A, Greco I, Ventura T. Ectopic adrenal tissue in the spermatic cord. Case report and review of the literature. *Arch Ital Urol Androl*. 1998;70(1):15-18.
- [3] Floyd Jr MS, Itam S, Nasir N, Weerasinghe SM, Irwin PP, Maddineni SB. Concomitant testicular seminoma and ectopic adrenal tissue of the cord in a 45-year-old male. *Can Urol Assoc J*. 2014;8(3-4):176-8.
- [4] Senescende L, Bitolog PL, Auberger E, Zorzavadjian Le Bian A, Cesaretti M. Adrenal ectopy of adult groin region: a systematic review of an unexpected anatomopathologic diagnosis. *Hernia*. 2016;20(6):879-85.
- [5] Khandakar B, Dey S, Sen Ray P, Sarkar R, Bhattacharyya P. Ectopic paratubal adrenal cell rest associated with mucinous cystadenoma of ovary. *J Clin Diagn Res*. 2015;9(10):13-14.
- [6] Thulasi Raman R, Revathi Sree R, Hemanathan G, Nerune M, Savitri, Anuradha S. Adrenal cortex heterotopia in an undescended testis—a case report. *J Clin Diagn Res*. 2014;8(9):11-12.

- [7]Ketata S, Ketata H, Sahnoun A, FakhFakh H, Bahloul A, Mhiri MN. Ectopic adrenal cortex tissue: an incidental finding during inguinoscrotal operations in pediatric patients. *Urol Int.*2008;81(3):316-9.
- [8]Savaş C, Candir O, Bezir M, Cakmak M. Ectopic adrenocortical nodules along the spermatic cord of children. *Int Urol Nephrol.* 2001;32(4):681-5.
- [9]Anderson JR, Mclean Ross AH. Ectopic adrenal tissue in adults. *Postgrad Med J.* 1980;56(661):806-808.
- [10]Sullivan JG, Gohel M, Kinder RB. Ectopic adrenocortical tissue found at groin exploration in children: incidence in relation to diagnosis, age and sex. *BJU International.* 2005;95(3):407–410.
- [11]Ye H, Suk Yoon G, Epstein JI. Intrarenal ectopic adrenal tissue and renal–adrenal fusion: a report of nine cases. *Mod Pathol.* 2009;22(2):175–181.
- [12]Vaos G, Zavras N, Boukouvalea I. Ectopic adrenocortical tissue along the inguinoscrotal path of children. *Int Surg.* 2006;91(3):125-8.
- [13]Dobanovacki DS, Maric DM, Maric DL, Vuckovic N, Jokic RR, Slavkovic AR et al. Ectopic adrenocortical tissue: an incidental finding during inguinal surgery in children. *Fetal Pediatr Pathol.* 2013;31(1):32-37.

