



## PEDIATRIC UROLOGY CASE REPORTS

ISSN 2148-2969

<http://www.pediatricurologycasereports.com>

# Peritonitis caused by *Candida albicans*: Rare presentation of a refluxing ureteral stump

Ada Molina Caballero, Alberto Pérez Martínez, Sara Hernández Martín

*Pediatric Surgery Department. Complejo Hospitalario de Navarra, Pamplona, Spain.*

## ABSTRACT

Ureteral stump syndrome is a medical condition caused by a refluxing distal ureteral remnant left after nephrectomy. Fungal colonization of the ureteral stump is uncommon and distant site infection is exceptional. We present a unique case of fungal peritonitis in a 13-year-old boy who had a right lower-moiety heminephro-ureterectomy at age three with a ureteral stump that served as reservoir for *Candida* resulting in the subsequent spontaneous fungal passage to the peritoneum.

**Key Words:** *Candida albicans*; peritonitis; ureteral stump, cystoscopy; vesicoureteral reflux.

*Copyright © 2017 pediatricurologycasereports.com*

**Corresponding Author:** Dr. Ada Molina Caballero  
*Pediatric Surgery Department. Complejo Hospitalario de Navarra. Irunlarrea Street, 3. 31008 Pamplona, Spain.*

Email: [adyemoca@yahoo.com](mailto:adyemoca@yahoo.com)

Accepted for publication: 10 May 2017

## Introduction

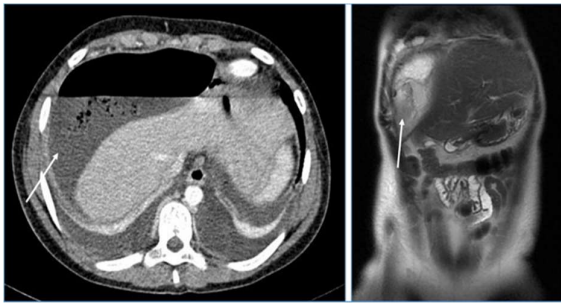
The ureteral stump (US) is a distal segment of ureter left in situ after total or partial nephrectomy. Majority of patients are asymptomatic but when reflux into the stump produces recurrent febrile urinary tract infections, bacteriuria or hematuria, empyema, stones or even malignancy, the condition is called ureteral stump syndrome [1,2]. It is a rare entity with an incidence of 1.1-10% usually occurring many years after surgery [3]. Fungal colonization of the stump is uncommon and distant site infection is exceptional [4]. We present a unique case of fungal peritonitis

resulting from a US that served as reservoir for *Candida albicans*.

## Case report

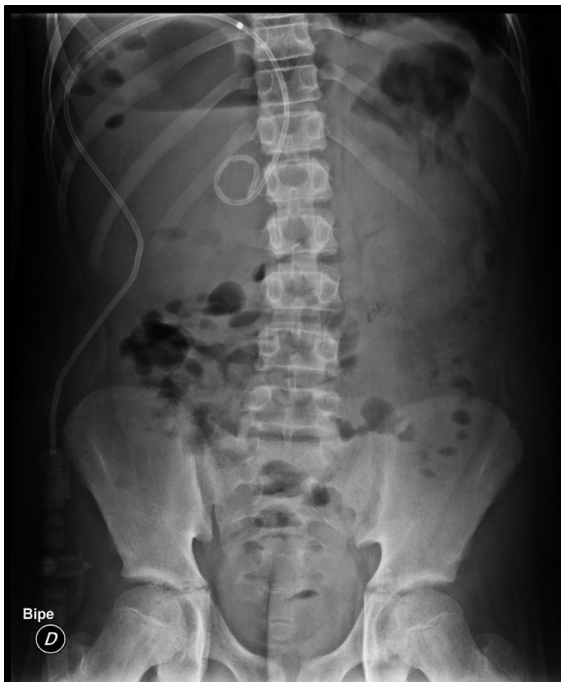13-year old boy operated on for suspected peritonitis of sudden onset. During surgery, no cause of peritonitis was found but *Candida albicans* was isolated in the peritoneal fluid. He had an antecedent of right lower-pole heminephrectomy and proximal ureterectomy at age 3, for a nonfunctional moiety due to vesicoureteral reflux in a duplex system. Ultrasound controls were normal with no subsequent symptomatology to date.

Antifungal treatment (fluconazole and caspofungin) was initiated. At seventh postoperative day, suspecting a possible complicated US, CT scan and MRI were performed showing a right subphrenic abscess and no abnormalities of the US [Fig. 1].



**Fig. 1.** CT scan and MRI showing a large right subphrenic abscess (arrows).

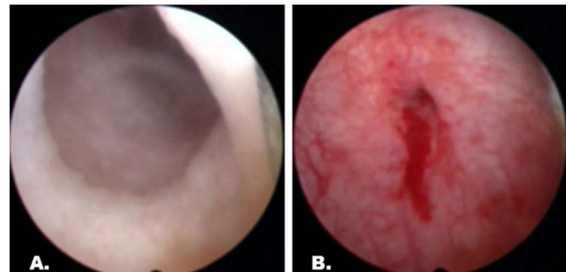
The immunity-host defense study and blood and urine cultures were negative. Evolution was torpid despite CT-guided drainage of the intra-abdominal abscess by *Candida*, requiring laparoscopic debridement with improvement afterwards [Fig. 2].



**Fig. 2.** CT-guided drainage of the intra-abdominal abscess by *Candida*.

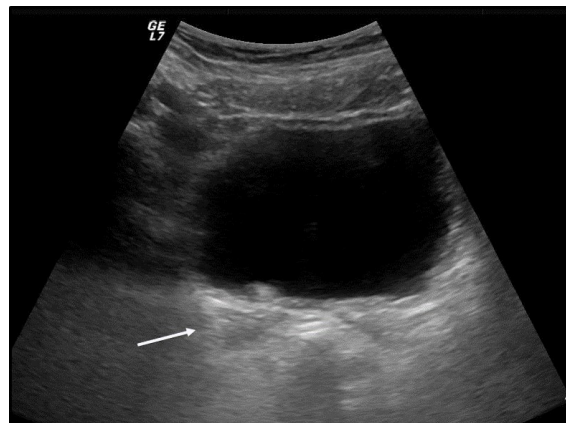
Failing to find a source of infection and suspecting the US might be acting as reservoir despite negative urine cultures, a cystoscopy was performed encountering a wide ureteral remnant. Mucosa biopsy showed *Candida*

colonization and after 6 month of antifungal medication, the stump was treated endoscopically with mucosal fulguration and antireflux technique by subureteric injection of a synthetic bulking agent [Fig. 3].



**Fig. 3.** Cystoscopy. A. Wide ureteral remnant. B. Final aspect of the ureteral orifice after mucosal fulguration and antireflux technique.

Over 2 years follow-up, the patient has remained asymptomatic with a practically inappreciable US in echography [Fig. 4].



**Fig. 4.** Echography showing the unstructured US (arrow).

### Discussion

In general, a poorly or nonfunctional kidney connected to a refluxing, obstructed or dysplastic ureter is managed with (hemi) nephrectomy and total or proximal ureterectomy [4]. Following nephrectomy, US with good drainage eventually undergo

muscular atrophy. If the US continues to suffer repeated episodes of urinary reflux, it may lead to gross dilatation with urine not effectively drained [2,5,6]. However, Escolino et al. [4] found that even a relatively short US (3 cm) could become symptomatic due to reflux. In addition, previous surgery or subsequent periureteritis may damage the nerve supply of the US, rendering it adynamic and favoring urinary stasis [4].

There is no literature regarding fungal peritonitis due to translocation to peritoneum from a colonized US. *Candida albicans* is the most common fungus colonizing and infecting the urinary tract (50-70% in most series) [7], but urine rarely yields *Candida* in persons who do not have specific risk factors: increased age, female sex, antibiotic use, urinary drainage devices, prior surgical procedures, and diabetes mellitus. These allow the organism to gain access and colonize the bladder mucosa or, in our case, the US mucosa [7,8]. *Candida* peritonitis may present with vague symptomatology or as a bacterial-like peritonitis. Infection is suspected when the organism is cultured from fluid samples. Drainage of any abscess (surgically or percutaneously) and antifungal therapy are vital [8]. Our patient had an important risk factor for *Candida* colonization –prior surgical procedure of the urinary tract– but we ignore what could have triggered the passage of the fungus to peritoneum years after the initial surgery, in an otherwise healthy patient.

Traditionally, the treatment of symptomatic US was open surgical excision of the stump [1,3]. With the advent of minimally invasive surgery, less invasive options have been reported [3,9]. Both laparoscopic excision and endoscopic electrofulguration or occlusion of the stump with bulking agents have shown to be effective [3,9,10]. We opted for an

endoscopic treatment given the multiple abdominal surgeries and possible peritoneal adhesions that could have hindered the laparoscopic excision of the stump. Bullock et al. [10] were the first to successfully treat a refluxing US by endoscopic subureteric injection of Teflon. Failure in endoscopic treatment has been attributed to ectopically ureteral orifices [3]. When faced with complications associated with residual US, minimally invasive techniques should be considered the treatment of choice.

Here, the insistence in finding the fungus, despite repeated negative urine cultures and imaging studies, allowed for the etiological diagnosis and resolution of our case.

#### Acknowledgements

The author(s) declare that they have no competing interest and financial support.

#### References

- [1] Arora S, Yadav P, Ansari MS. Diagnosis and management of symptomatic residual ureteral stump after nephrectomy. *BMJ Case Rep*. 2015;26;2015. pii: bcr2015209441.
- [2] Labanaris AP, Zugar V, Smiszek R, Nützel R, Kühn R. Empyema of the ureteral stump. An unusual complication following nephrectomy. *Scientific World Journal*. 2010; 5;10:380-3.
- [3] Alenezi H, Eltiraifi AE, Alomar M. Minimally invasive surgery for the treatment of ureteral stump syndrome. *Urol Ann*. 2015;7(4):454-8.
- [4] Escolino M, Farina A, Turrà F, et al. Evaluation and outcome of the distal ureteral stump after nephro-ureterectomy in children. A comparison between laparoscopy and retroperitoneoscopy. *J Pediatr Urol*. 2016;12(2):119.e1-8.

- [5] Iaquinto M, Esposito C, Escolino M, Farina A, Settini A, Cigliano B. Symptomatic refluxing distal ureteral stump after retroperitoneoscopic nephrectomy. *APSP J Case Rep*. 2014;1;5(1):14.
- [6] Lee YS, Hah YS, Kim MJ, et al. Factors associated with complications of the ureteral stump after proximal ureteroureterostomy. *J Urol*. 2012;188(5):1890-4.
- [7] Kauffman CA. Diagnosis and management of fungal urinary tract infection. *Infect Dis Clin North Am*. 2014;28(1):61-74.
- [8] Rebolledo M, Sarria JC. Intra-abdominal fungal infections. *Curr Opin Infect Dis*. 2013;26(5):441-6.
- [9] Androulakakis PA, Stephanidis A, Antoniou A, et al. Outcome of the distal ureteric stump after (hemi)nephrectomy and subtotal ureterectomy for reflux or obstruction. *BJU Int*. 2001;88(6):586-9.
- [10] Bullock KN, Deane AM, Ashken MH. Endoscopic Teflon injection for a refluxing ureteric stump after simple nephrectomy. *Br Med J (Clin Res Ed)*. 1985;290:1109.

