



PEDIATRIC UROLOGY CASE REPORTS

ISSN 2148-2969

<http://www.pediatricurologycasereports.com>



Acute scrotal swelling caused by scrotal suppurative appendicitis in a young infant: A case report

Ramaswamy Rajendran, Mohammed Shawky, Rayan Baz, Ghazi Mukttash

Department of Pediatric & Neonatal Surgery, Maternity & Children's Hospital (MCH), Najran, Saudi Arabia

ABSTRACT

A 70d old infant who had reducible bilateral inguinal hernia was found to have acute bilateral scrotal swelling, erythema and tenderness without intestinal obstruction. Radiography and ultrasonography studies detected right side inguinoscrotal hernia. With a diagnosis of strangulated inguinal hernia on right side, exploration was done. Amyand's hernia and acute scrotal appendicitis were found. Appendectomy, bilateral inguinal herniotomy and scrotal fixation of testes were done. Scrotal appendicitis is an exceptionally rare cause of acute scrotum in young infants. Scrotal manifestations and scrotal complications of acute appendicitis in children are reviewed. This case stresses the need for emergency exploration of acute scrotum in which there is diagnostic dilemma

Key Words: Acute scrotum; Amyand's hernia; scrotal appendicitis; patent processus vaginalis.

Copyright © 2017 pediatricurologycasereports.com

Corresponding Author: Dr. Ramaswamy Rajendran
 Department of Pediatric & Neonatal Surgery
 Maternity & Children's Hospital (MCH), PB No.3600,
 Najran, Saudi Arabia.

Email: pedsurgdrraj57@yahoo.in

Accepted for publication: 21 March 2017

Introduction

Acute pain and swelling in scrotum can be due to torsion of testis or of its appendage, acute epididymitis or orchitis, idiopathic scrotal edema, strangulated inguinoscrotal hernia, or hematocele. Other rare causes have been reported [1]. Acute scrotum is a surgical emergency considering the limitation of investigations to specify the diagnosis, and the therapeutic need in some of them particularly in testicular torsion. Disease of an extrascrotal

organ causing acute scrotum is reported herewith.

Case report

Seventy days old boy was admitted 2 days back under pediatrics due to respiratory distress with a diagnosis of bronchiolitis. He was on treatment with antibiotics, salbutamol nebulization, oxygen inhalation, intravenous fluids and nil per oral. Surgical consultation was done due to inguinal swellings. The mother noticed bilateral inguinal swellings 2 weeks back and swelling in scrotum the previous day. The child was born by caesarean delivery at 38weeks gestation as one of twins. Mother was P3G5A1. His birth weight was 1550g, due to intrauterine growth retardation.

He was observed in newborn nursery for 4 days due to respiratory distress from transient tachypnea of newborn. Ultrasound scan (US) of abdomen at 9 days old showed prominent pelvicalyceal system on right side. Echocardiogram done one month back revealed small muscular ventricular septal defect for which the cardiologist has advised follow-up. Child had no vomiting, constipation or fever. On examination, child weighed 2600g, had tachypnea with normal temperature. Abdomen showed gaseous distension with no visible or palpable bowel loops, and was soft and nontender. There were bilateral reducible inguinal hernia which reached the neck of scrotum on both sides. Scrotum was swollen, erythematous, indurated and tender up to its neck on both sides. Testes could not be palpated through the swelling. Blood examination showed hemoglobin level of 8.2 gm/dl, total white cell count 5.91×10^3 , neutrophils 48%, lymphocytes 45.7%, monocytes 5.1%, and basophils 1.2%, blood urea level 4.69 mmol/L, creatinine 3.7mmol/L, sodium 135 mmol/L, potassium level of 4.9mmol/L. C-reactive protein estimation in blood was positive. Plain chest radiograph showed patch of consolidation in right upper lobe. Abdominal skiagram showed dilated bowel loops without significant air-fluid levels, and a gas shadow with fluid level in the right hemiscrotum [Fig. 1].

US of scrotum showed sizeable right inguinal hernia reaching the bottom of right hemiscrotum, compressing that testis to posterior. Right testis was grossly normal in size. There was bilateral scrotal edema. Left testis was not detected by ultrasound. Doppler study of herniated bowel and of right testis was inconclusive. Clinical, radiographic and ultrasound findings together indicated strangulated inguinal hernia on right side. So

emergency operation was done. Under general endotracheal anesthesia, right inguinal canal was opened and external inguinal ring was divided.

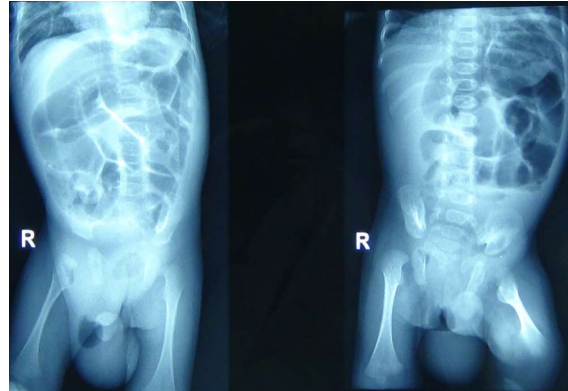


Fig. 1. A gas shadow with fluid level in the right hemiscrotum.

Ascending colon and terminal ileum were seen healthy in the hernia. Caecum and vermiform appendix occupied the hernial sac in the bottom of scrotum and were adherent to scrotum. The appendix showed suppurative inflammation [Fig. 2].

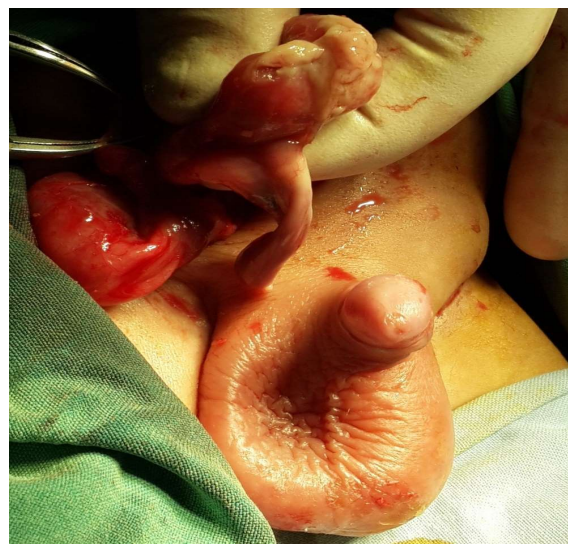

Fig. 2. Fibrin covered the caecum.

There was purulent fluid in the hernial sac. Right testis was delivered out and inspected.

Pyogenic membrane covered the testis, but it was viable. Appendectomy, reduction of caecum and terminal ileum, high ligation and division of right hernial sac, intrascrotal lavage, fixation of right testis, followed by left inguinal herniotomy and scrotal fixation of left testis were performed. Left testis also was covered by pyogenic membrane. Postoperatively he was mechanically ventilated for about 20 hours. He had smooth recovery from surgery. Feeding was started after 48 hours. Culture of purulent fluid and fibrin on caecum proved *E. coli* infection. Histopathological examination of appendectomy specimen revealed gangrenous appendicitis. Right inguinal herniotomy wound developed infection and gaping. Sensitive antibiotics were injected and wounds healed. He was discharged on 7th postoperation day.

Discussion

Acute scrotum in the present case is from inflammation of vermiform appendix, a normal extrascrotal organ. Inguinal hernia containing appendix is named as Amyand's hernia (AH), in honour of Claudius Amyand who, in 1735, successfully resected a perforated appendix from the hernia of 11y old boy. Amyand's patient presented with fecal fistula of scrotum due to ignored appendicitis [2]. About 1% of all inguinal hernias contains vermiform appendix and only in 0.1% of cases the appendix is complicated (inflammation / perforation). Mucus accumulation and ischemia of the entrapped appendix may precipitate infection and inflammation. Inflammation cause edema and formation of adhesions resulting in incarceration of appendix, ischemia and bacterial growth. Contraction of the musculature of abdominal wall would cause a sudden rise in intra-

abdominal pressure with incarceration of appendix, subsequent inflammation and bacterial proliferation [3]. A congenital band extending from tip of appendix up to right testis in scrotum [4] or the manoeuvre to reduce hernia can result in inflammation of the appendix [5]. The obvious prerequisites for herniation of appendix are mobile caecum and patent processus vaginalis.

Based on Losanoff and Basson classification [2] of AH, that with sepsis confined to scrotum comes under type-2 AH. This is the commonest manifestation (53%) of neonatal appendicitis with inguinoscrotal manifestation [2]. Hernial appendicitis (HA) is seen only in males. It is more common in preterm and small-for-gestational-age newborns in an analysis of 24 cases found over 25y period worldwide [2]. Genital swelling and redness or scrotal pain was noted in all the neonates. One or more systemic symptoms such as vomiting (46%), fever (46%), abdominal distension (21%), feed refusal (21%), and restlessness (21%) were noticed. Correct preoperative diagnosis was not made in any of them. Strangulated hernia (54%), epididymo-orchitis (21%) and testicular torsion (13%) were the 3 commonly mistaken diagnoses. Most of the differential diagnosis indicated early exploration. This avoided therapeutic delay. Interestingly, despite early diagnosis the rate of perforation remains as high as 50% in scrotal appendicitis (SA). Notwithstanding this there was no mortality in this group [2].

Our patient was small-for-gestational age, young infant with no systemic symptom. Scrotal swelling of 24h duration, erythema, induration, tenderness and presence of bowel up to the bottom of scrotum by radiograph and US were suspicious of strangulated inguinoscrotal hernia. There was no radiological evidence of bowel obstruction and

inconclusive doppler study of viability of bowel. At exploration, it was SA. This case stresses the need for emergency exploration of acute scrotum in which there is diagnostic dilemma or therapeutic need of surgery. Delay in operation might have led to abdominal sepsis (AH type-3) and even systemic sepsis and mortality.

There had been exceptionally rare reports of SA in children after newborn period [1,5,6]. A 1y old male child presented with a discharging sinus over the right hemiscrotum since the age of 3m, following rupture of scrotal abscess. This was found to be due to HA [7]. Fifteen month old child with recurrent episodes of painful swelling in right hemiscrotum had histopathologically proved HA [8].

Acute scrotum in children can rarely be due to scrotal abscess from synchronous abdominal appendicitis [9-12]. If child presents with acute scrotal signs and vague lower abdominal symptoms, US of right iliac fossa must be done along with doppler US of scrotum. In this way acute appendicitis as the cause of acute scrotum can be diagnosed [13]. Scrotal abscess causing acute scrotum had occurred as complication following appendectomy for abdominal appendicitis [14]. Left hemiscrotal abscess from appendicitis was presented as acute hemiscrotum [14,15]. Patent processus vaginalis is the route of spread of abscess from abdominal appendicitis. Theoretically, fulminant scrotal sepsis can induce thrombosis of testicular vessels and jeopardise testicular blood supply with consequent ischemia or necrosis. But surprisingly, testicular viability was unaffected in SA in newborns and children [2,16].

Differential diagnosis of acute scrotal swelling and pain include testicular torsion, torsion of one of the testicular appendages, epididymitis, orchitis, idiopathic scrotal edema, acute

hydrocele, traumatic hematocele, incarcerated inguinal hernia, and scrotal cellulitis. Rare causes [1] include thrombosed scrotal veins, bleeding into the testis in Henoch-Schonlein purpura, intra-abdominal bleeding secondary to blunt abdominal trauma or warfarin therapy. To this list, acute scrotal appendicitis and scrotal abscess from abdominal appendicitis can be added. The present case is the first of its kind in this tertiary-care referral hospital which is 12y old. Acute appendicitis (AA) in infants less than 1y old represents 2% of the total cases of appendicitis. Generally, AA is associated with Hirschsprung's disease, necrotizing enterocolitis, or hernia with incarcerated appendix, the latter representing about 1/3 of the cases [5].

Complications of appendectomy in scrotal appendicitis are wound infection, epididymitis, urinary retention, recurrence of hernia and mortality. Some surgeons delayed the herniotomy up to six months to avoid recurrence [11,14,16]. Mortality (14%-30%) is associated with perforated appendicitis and peritonitis [7]. Our patient had wound infection as complication.

Acknowledgements

The author(s) declare that they have no competing interest and financial support.

References

- [1]Vlazakis S, Vlahakis I, Kakavelakis K.N, Charissis G. Right acute hemiscrotum caused by insertion of an inflamed appendix. *BJU Int.* 2002; 89(9):967-8.
- [2]Raveenthiran V. Neonatal Appendicitis (Part 2): A Review of 24 cases with Inguinoscrotal Manifestation. *J Neonat Surg.*2015; 4(2):15.
- [3]Mancini A. Hernia of Amyand. *MedEmlt.* Posted on 03/01/2013.

- [4]Mandhan P, Rayes TA, Ali MJ, Aldhaheri M. Complicated Amyand's Hernia in a Neonate. *J Neonat Surg*. 2014;3(3):38.
- [5]Piedade C, Alves JR. Amyand's Hernia in a 6-Week-Old Infant: A Delayed Diagnosis. *Case Rep Pediatr*. 2013; 2013: 758171.
- [6]Bar-Maor J.A. Acute appendicitis located in a scrotal hernia of a premature infant *J Pediatr Surg*.1978;13(2):181-182.
- [7]Jain P, Mishra A. Amyand's hernia presenting as chronic scrotal sinus. *J Indian Assoc Pediatr Surg*. 2012; 17(3):128–129.
- [8]Mbibu NH, Khalid L, AmehEA. Scrotal appendicitis in a child mimicking recurrent testicular torsion. *Afr J Urol*. 2002;8(2):94-95.
- [9]Nagel P. Scrotal swelling as the presenting symptom of acute perforated appendicitis in an infant. *J Pediatr Surg*. 1984;19(2): 177-8.
- [10]Mansoor K, Samujh R, Al Alayet YF. Scrotal abscess with a rare cause. *J Indian Assoc Pediatr Surg*. 2009;14(3):119–120.
- [11]Mendez R, Tellado M, Montero M, et al. Acute scrotum: An exceptional presentation of acute nonperforated appendicitis in childhood. *J Pediatr Surg*. 1998; 33(9): 1435-36.
- [12]Shehzad KN, Riaz AA. Unusual cause of a painful right testicle in a 16-year-old man: a case report. *J Med Case Rep*. 2011;21;5:27.
- [13]Satchithananda K, Beese RC, Sidhu PS. Acute appendicitis presenting with a testicular mass: ultrasound appearances. *Br J Radiol*. 2000;73(871):780-2.
- [14]Saleem MM. Scrotal abscess as a complication of perforated appendicitis: A case report and review of the literature. *Cases J*. 2008;19:1(1):165.
- [15]Yasumoto R, Kawano M, Kawanishi H, et al. Left acute scrotum associated with appendicitis. *Int J Urol*. 1998; 5(1):108–10.
- [16]Okur, MH, Arslan MS, Zeytun H, Otcu S. Amyand's hernia complicated with acute appendicitis: A case report and literature review. *Ped Urol Case Rep* 2015;2(4): 7-12.

Access this article online

<http://pediatricurologycasereports.com>

Quick Response Code

