

**PEDIATRIC UROLOGY CASE REPORTS**

ISSN 2148-2969

<http://www.pediatricurologycasereports.com>**Vesicovaginal reflux as a cause of hydrocolpos in prepubertal females:
A radiologist's perspective****Dayananda Sagar Gopal, Sunita Gopalan, Prakash Nayak, Anita Nagadi, Shyam Shankar, Sriram Patwari***Department of Radiology, Columbia Asia Referral Hospital, Yeshwanthpur, Bengaluru, India***ABSTRACT**

Vesicovaginal reflux (VVR) is common in prepubertal females presenting with voiding dysfunction. However, VVR as a cause of gross hydrocolpos is uncommon in clinical practice. The varied clinical presentation and perplexing imaging findings often results in undergoing a battery of clinical and radiological tests before arriving at a definitive diagnosis. In this article we present the classical imaging features of non-obstructive hydrocolpos due to VVR which differentiates it obstructive causes that can present with similar imaging features.

Key Words: Hydrocolpos; vesicovaginal reflux; non obstructive; spinning top urethra.

Copyright © 2017 pediatricurologycasereports.com

Corresponding Author:

Dr. Dayananda Sagar Gopal

Department of Radiology, Columbia Asia Referral Hospital, Yeshwanthpur, Bengaluru, India

E mail: dayananda.s@columbiaasia.com

Accepted for publication: 10 May 2017

findings in such cases is diagnostic and mitigates the need for further evaluation.

Case report

8 year old prepubertal female presented to urology outpatient department with complaints of intermittent lower abdominal pain and nocturnal enuresis from past 6 months. There was history of urge incontinence during day time. No history of day time incontinence. The developmental milestones, height and weight were normal. No history of any urological disorders, trauma or surgery in the past. The limited local examination was normal. Urinalysis revealed numerous pus cells and few RBCs. Otherwise total count and renal function tests were within normal limits.

Introduction

Hydrocolpos refers to distension of vagina due to accumulation of fluid. In children, the most common cause of hydrocolpos is congenital vaginal outlet obstruction. It is important to know that organic obstruction is not the only cause and this condition may also result from non-obstructive process [1]. VVR is one such cause which though common in patients with voiding disorders can rarely present with hydrocolpos. Classical radiological imaging

The patient was referred for ultrasonography (USG) which demonstrated an anechoic cystic structure posterior to urinary bladder outlined by cervix on cranial aspect [Fig. 1].

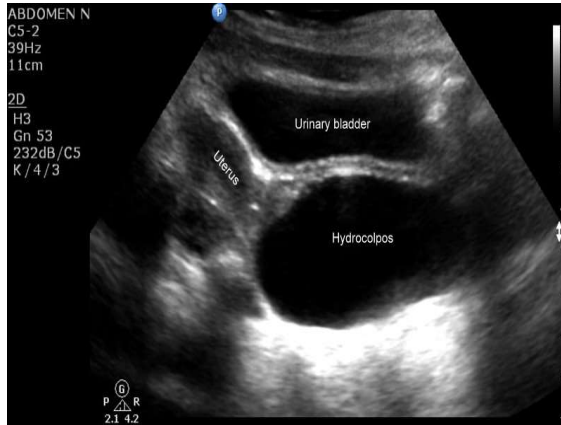


Fig. 1. Transabdominal sonography longitudinal view- anechoic cystic structure posterior to urinary bladder suggesting hydrocolpos.

A sonographic diagnosis of hydrocolpos was made with rest of the study being normal. The patient was subsequently taken up for vaginoscopy and decompression under general anaesthesia. Intra-operatively no features suggestive of obstruction were found. Intra-operative USG demonstrated normal vagina with no hydrocolpos and hence no surgical intervention was carried out. The discordance between imaging features and intra-operative findings were discussed and the patient was referred for a detailed evaluation by MRI pelvis.

Non contrast MRI demonstrated hydrocolpos as detected on USG [Fig. 2a]. The urinary bladder, uterus, ovaries and rest of the pelvis was normal. The MRI study was repeated after voiding which demonstrated complete resolution of hydrocolpos [Fig. 2b]. An imaging diagnosis of non-obstructive hydrocolpos due to vesicovaginal reflux was made.

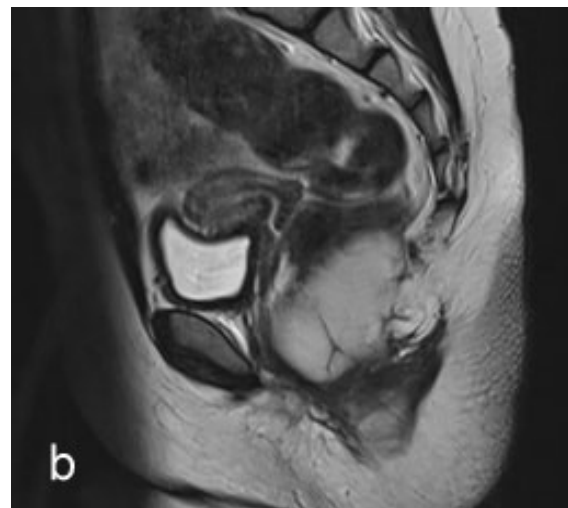
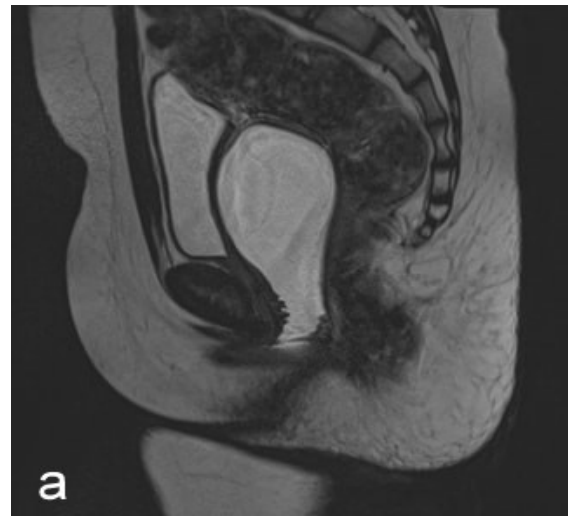


Fig. 2. T2W MRI of pelvis sagittal view: (a) Fluid filled vagina - hydrocolpos when urinary bladder is full, (b) Complete resolution of hydrocolpos after voiding.

The findings were confirmed on Voiding cystourethrogram (VCU) which demonstrated dynamic reflux of contrast into vagina during early voiding [Fig. 3b] with complete resolution of hydrocolpos by the end of voiding [Fig 3c]. Dilatation of the posterior urethra distal to internal sphincter referred to as “Spinning top urethra” was also seen [Fig 3a]. The possibility of a vesico-vaginal fistula and ectopic ureter was also ruled out on MRI and VCU.

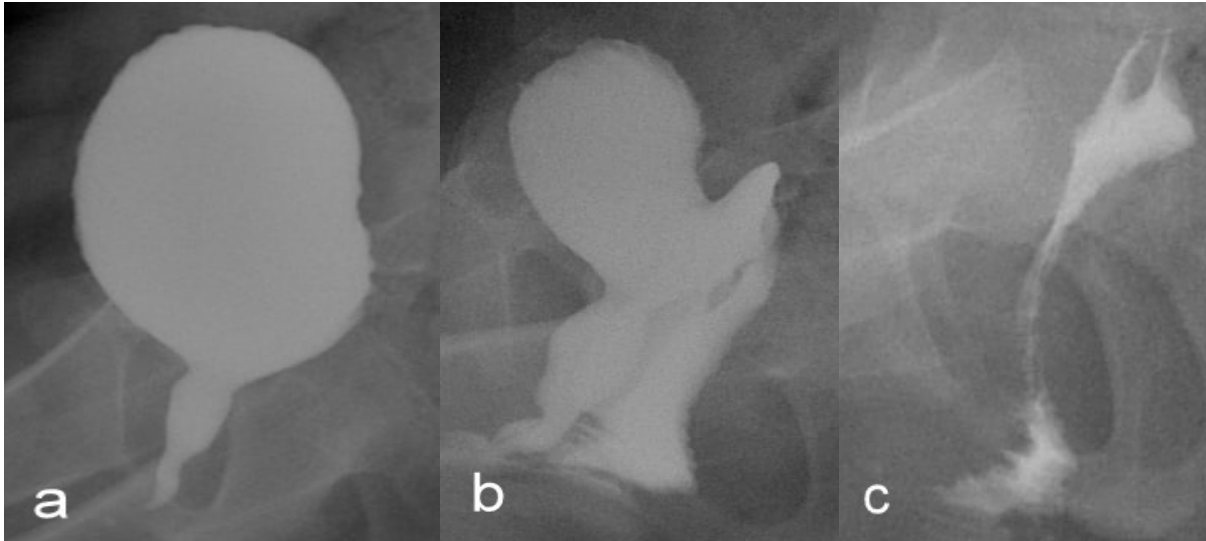


Fig. 3. Voiding cystourethrogram: **(a)** Dilatation of posterior urethra – “ Spinning top urethra” at the onset of voiding, **(b)** Dynamic reflux of contrast into vagina during early voiding, **(c)** Near total evacuation of vaginal fluid after complete voiding.

Discussion

VVR is defined as reflux of urine into vagina during voiding. It is relatively common, occurring in 43-69 % of girls undergoing imaging evaluation for voiding dysfunction [2, 3]. Reflux can occur in either supine or erect position, however gross hydrocolpos due to VVR is uncommon [3].

Gross hydrocolpos in pediatric population is rare and is most often secondary to obstructive causes like imperforate hymen, vaginal septum, vaginal atresia and other complex urogenital malformations. VVR represents an uncommon cause of hydrocolpos and the exact etiology of this condition is unknown. However various predisposing conditions are postulated, such as adhesions of labia minora, ectopic ureter or ureteral duplication and female hypospadias [4,5,6]. Functional factors like voiding with tightly opposed legs [4] and spastic disorders like cerebral palsy are the other predisposing factors [7]. In most of the cases no anatomical abnormality is

detected and hence VVR is likely to represent a functional voiding disorder.

Patients may be asymptomatic or present with recurrent urogenital infections, lower urinary tract symptoms, post void dribbling or day time incontinence. Ultrasonography is the initial imaging modality of choice which demonstrates an anechoic cystic structure outlined by cervix posterior to urinary bladder suggesting hydrocolpos. In such cases a post void USG must be carried out to document resolution of hydrocolpos which suggests a non-obstructive cause.

VCU is the next investigation and is the reference examination of choice. VCU demonstrates reflux of contrast into vagina during early voiding phase and progressive complete evacuation of hydrocolpos in late voiding phase. An associated bladder abnormality like wide bladder neck, “spinning top urethra” (STU) and low bladder volume may be seen. STU refers to dilated posterior

urethra just distal to internal sphincter in females. Previously STU was thought to be a normal variant, however recent studies have demonstrated that STU is seldom if ever a normal variant [8]. When present, STU represents underlying bladder instability and warrants a detailed evaluation for functional voiding dysfunction.

Role of CT and MRI is largely limited in a typical case with classical findings on USG and VCU. CT and MRI are necessary in ruling out obstructive causes of hydrocolpos with MRI considered superior due to excellent soft tissue resolution and lack of radiation risk.

Conclusion

Hydrocolpos due to VVR is rare in prepubertal girls presenting with voiding dysfunction. It is important that the reporting radiologist be aware of this condition and its imaging features to avoid unnecessary tests and patient anxiety. USG and VCU with post void imaging are diagnostic.

Acknowledgements

The author(s) declare that they have no competing interest and financial support.

The authors sincerely acknowledge the clinical inputs by Dr. Sai Prasad T.R (Consultant, Pediatric surgery) and Dr. Jyothi V Shenoy (Consultant, Gynecology & Obstetrics), Columbia Asia Referral Hospital, Yeshwanthpur, Bangalore, in preparation of this case report.

References

[1] Snyder EM, Nguyen RA, Young KJ, Coley BD. Vesicovaginal reflux mimicking Davis

obstructive hydrocolpos. *J Ultrasound Med.* 2007;26(12):1781-4.

- [2] LA, Chumley WF. The frequency of vaginal reflux during micturition - its possible importance to the interpretation of urine cultures. *Pediatrics.* 1966;38(2):293-4.
- [3] Kelalis PP, Burke EC, Stickler GB, Hartman GW. Urinary vaginal reflux in children. *Pediatrics.* 1973;51(5):941-2.
- [4] Stannard MW, Lebowitz RL. Urography in the child who wets. *AJR Am J Roentgenol.* 1978;130(5):959-62.
- [5] Capraro VJ, Greenberg H. Adhesions of the labia minora. A study of 50 patients. *Obstet Gynecol.* 1972;39(1):65-9.
- [6] Gassner I, Geley TE. Ultrasound of female genital anomalies. *Eur Radiol.* 2004;14 Suppl 4:L107-22. Review.
- [7] Szabó L, Lombay B, Borbás E, Bajusz I. Videourodynamics in the diagnosis of urinary tract abnormalities in a single center. *Pediatr Nephrol.* 2004;19(3):326-31.
- [8] Saxton HM, Borzyskowski M, Mundy AR, Vivian GC. Spinning top urethra: not a normal variant. *Radiology.* 1988;168(1):147-50.

Access this article online

<http://pediatricurologycasereports.com>

Quick Response Code

