



PEDIATRIC UROLOGY CASE REPORTS

ISSN 2148-2969

<http://www.pediatricurologycasereports.com>


Y-type urethral duplication with posterior perineal fistula: A new variant

**Sandesh V Parelkar, Beejal Sanghvi, Rahul Kumar Gupta,
Arjun Apparao Pawar**

Department of Pediatric Surgery, King Edward Memorial Hospital, Parel, Mumbai, India

ABSTRACT

13 months old boy presented with constipation and straining during micturition with poor urinary stream and voiding of urine per rectum. Perineal examination revealed posterior perineal fistula. Voiding cysto-urethrogram showed bilateral vesicoureteral reflux with bladder diverticuli, normal dorsal urethra and dye going from urethra to rectum suggestive of Y type urethral duplication. Under stoma cover, he underwent excision of posterior perineal fistula with accessory ventral urethra and anorectoplasty was done. At present patient is passing urine in good stream without straining. The uniqueness of our case is the presence of Y type of urethral duplication with normal calibre dorsal urethra and presence of posterior perineal fistula. Therefore, we consider our case to be an unusual variant of Y type of urethral duplication that has not been described before.

Key Words: Urethral duplications; posterior perineal fistula; anorectal malformation.

Copyright © 2017 pediatricurologycasereports.com

Corresponding Author: Dr Arjun A Pawar
Mch Pediatric surgery, Department of Pediatric Surgery,
King Edward Memorial Hospital, Parel, Mumbai, India
Email: jd-drarjunapawar@gmail.com
Accepted for publication: 29 March 2017

duplication. In this report, we present an unusual case of Y type urethral duplication with normal calibre dorsal urethra associated with posterior perineal fistula.

Introduction

Urethral duplication is a rare anomaly usually seen in males, particularly Y type of urethral duplication is often associated with low anorectal malformations; in the form of anal stenosis of normally or slightly anteriorly placed anal opening. The Y-type urethral duplication constitutes 6-30% of all urethral duplications [1] and the dorsal urethra is usually stenotic in the Y-type urethral

Case report

A 13 months old boy was referred to us for endoscopic evaluation of the urogenital tract. Patient had received treatment for constipation in the form of laxatives and anal dilatation before being referred to us. He had history of recurrent urinary tract infections with passing of urine per rectum in addition to normal stream. Perineal examination revealed posterior perineal fistula with thick median

raphae at the expected site of normal anal opening [Fig. 1] and reversal of anal position index (API).

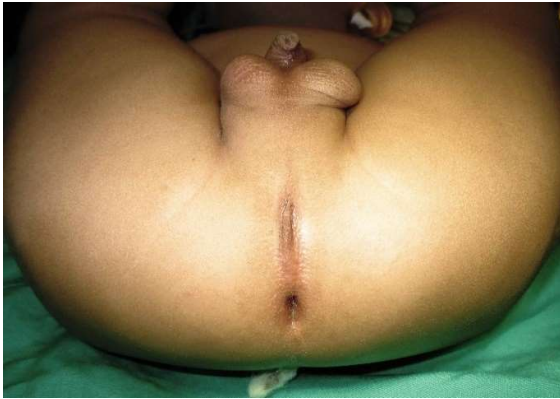

Fig. 1. Perineum showing posterior perineal fistula with reversed API.

X-ray abdomen showed faecal loading. Voiding cysto-urethrogram (VCUG) showed bilateral vesicoureteric reflux (VUR) with bladder diverticuli, good calibre normal dorsal urethra and dye going from urethra to rectum which suggested Y type urethral duplication [Fig. 2].

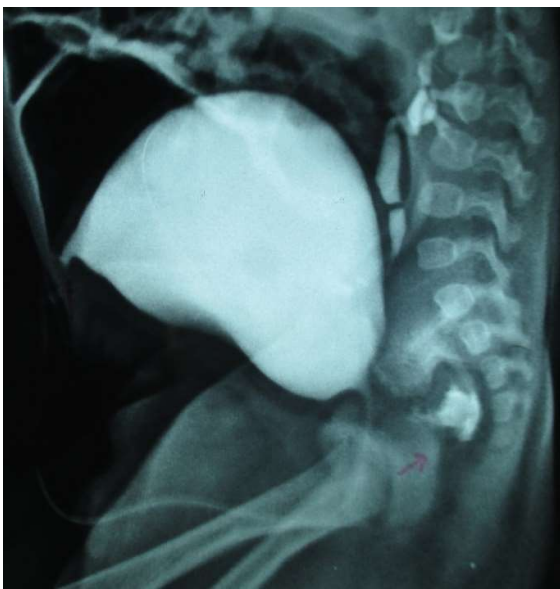

Fig. 2. VCUG showing bilateral vesicoureteric reflux with bladder diverticuli, good caliber normal dorsal urethra and dye going from urethra to rectum which suggested Y type urethral duplication.

High sigmoid colostomy was done in view of Y type urethral duplication with posterior perineal fistula. Cystoscopy showed normal dorsal urethra. Diluted betadine solution injected into anterior urethra was seen coming out through posterior perineal fistula. A posterior sagittal approach with excision of accessory ventral urethra, excision of perineal rectal fistula and placement of rectum within sphincter muscle complex was planned. Posterior sagittal incision was taken from the tip of the coccyx, incorporating perineal fistula opening till anterior limit of neanus which was marked with the help of muscle stimulator. The fistula was dissected till the normal calibre rectum was reached and was excised. The rectum was retracted cephalad and the ventral limb of y duplication was dissected, hooked and excised. The rectum was placed in the muscle complex and anoplasty was completed. Postoperatively, anal dilatation was started and colostomy closure was done subsequently. At present, he is passing urine in good stream without straining and is on chemoprophylaxis for VUR. He has no complaints of constipation at present.

Discussion

Urethral duplication is a rare congenital anomaly of lower urinary system. The uniform embryological explanation of urethral duplication is very difficult due to presence of the various types described in the literature. Various theories have been postulated [2,3]. One end of spectrum of urethral duplication like complete duplication of bladder and urethra can be explained by either excessive constriction between the urogenital and vesicourethral portions of the ventral cloaca, or due to a supernumerary cloacal septum that indents the epithelial wall of the bladder. The other end of the spectrum like Y-type

duplication can occur due to faulty closure of the urorectal membrane, impaired growth of the dorsoinferior wall of the urogenital sinus or fistula formation in the dorsal margin of the urogenital sinus due to possible vascular accident [4,5]. There appears to be a misalignment between the termination of the cloacal membrane and its interaction with the developing genital tubercle and urogenital sinus.

The clinical presentation differ according to the anatomical variant and there are a variety of types and several classification systems [2,5,6]. The most used is the classification of Effman [Fig. 3] which is based on radiological findings and separates urethral duplication into 3 types as shown [2].

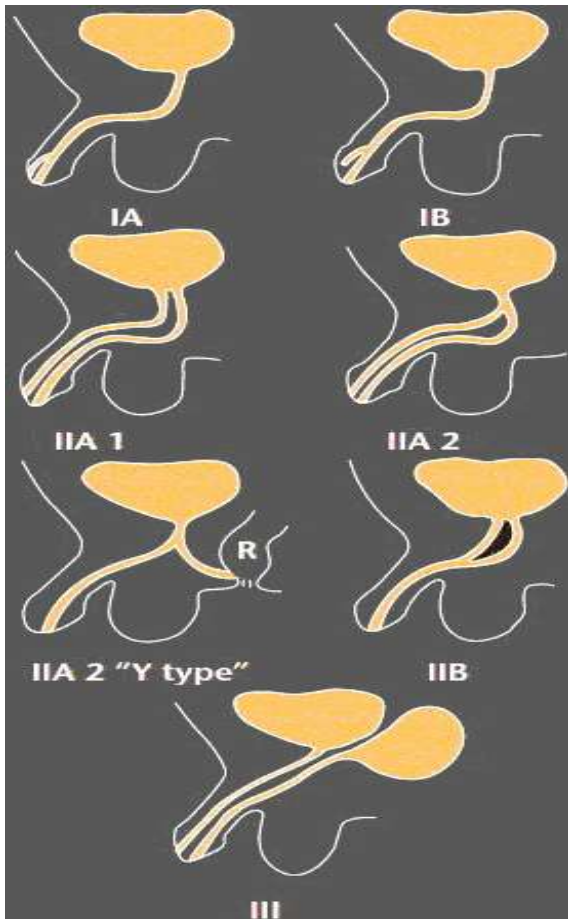


Fig. 3. Effman's Classification.

Y-type duplication is a special form of type IIA2 urethral duplication, two urethras originating from the bladder neck. It has two variants; the usual form of Y-type duplication is characterized by a stenotic dorsal urethra and a more functional accessory ventral urethra, which opens into the perineum, perianal region or the anal canal. The unusual form includes a normal dorsal urethra and hypoplastic ventral urethra, however, index case had both dorsal and ventral urethra of normal caliber [5].

Urethral duplication is frequently associated with other genitourinary anomalies such as vesicoureteral reflux (most common), bladder exstrophy, cryptorchidism, and megaureters [2,3,6]. Associated urethral abnormalities are mainly urethral hypoplasia, stenosis, or atresia and are seen in less than half of the boys [7]. Index case had associated bilateral vesicoureteral reflux. Y-type duplication may be associated with disorders of midline development and other congenital anomalies such as cloacal exstrophy, conjoined twins, early amnion rupture syndrome, and hand-foot genital syndrome. None of them were present in index case [5].

Most cases of urethral duplication with genetic anomalies are diagnosed during infancy. Urinary symptoms show a wide range, such as double stream, incontinence, urinary tract infection, voiding urine per rectum or outflow obstruction.

Voiding cystourethrography, retrograde urethrography and fistulography are methods assisted imaging in diagnosis of Y-type urethral duplication. Urethrocystoscopy should be performed to confirm the radiographic findings [3,6]. Additionally, these radiographic methods are used to find out other lower urinary tract abnormalities such as posterior urethral valve, bladder neck obstruction and megalourethra, which might

be associated with Y-type urethral duplication [8].

Differential diagnosis of index case was H type anorectal malformation. H-Type anorectal malformation with normal anus in boys are extremely rare with reported incidence of 3.2% to 7.1% [9] and they usually have a communication between the anorectum and anterior urethra [10]. In this anomaly, the urethral calibre remains normal along with presence of normal anus at normal site with a rectourethral connection. It doesn't correlate with index case as it was associated with posterior perineal fistula opening much posterior to expected site of normal anus.

Treatment of urethral duplication depends on the patient's symptoms and the type of anomaly. The standard Y-type duplications meatus obviously require more complex intervention [3]. Excision of the accessory ventral urethra in cases of normal dorsal urethral is the final surgical treatment and can be successful; alternative methods of sclerosis or fulguration of the accessory urethra is also reported [5,11].

The options for management of the Y-type urethral duplication are: (i) diversion sigmoid colostomy with anterior mobilization of ventral urethra as perineal urethrostomy via anterior sagittal approach; (ii) Orthotopic urethral reconstruction; (iii) anastomosis of orthotopic urethral and perineal urethra; (iv) colostomy closure with management of complications. The patients having ventral urethra onto the perineum underwent single stage urethral reconstruction [3,4,12].

The index case had a congenital Y type urethral duplication with normal dorsal urethra with an accessory ventral urethra opening into posterior perineal fistula which is a possibly new type.

As a results, congenital Y type urethral duplication with normal dorsal urethra with ventral urethra opening into posterior perineal fistula is very rare and could be new variant of Y type urethral duplication in Effman's classification. Posterior sagittal approach is advisable for managing this variant.

Acknowledgements

The author(s) declare that they have no competing interest and financial support.

References

- [1] Bogaert GA. Urethral duplication and other urethral anomalies. In: Gearheart JP, Rink RC, Mouriquand PD, Pediatric Urology. 2nd ed. Philadelphia: Saunders; 2010. p. 446–58.
- [2] Effman EL, Lebowitz RL, Colodny AH. Duplication of the urethra. *Radiology*. 1976;119(1):179-85.
- [3] Podesta ML, Medel R, Castera R, Ruarte AC. Urethral duplication in the children: Surgical treatment and the results. *J Urol*. 1998;160(5):1830-33.
- [4] Sánchez MM, Vellibre RM, Castelo JL, Arias MP. A new case of male Y-type urethral duplication and review of literature. *J Pediatr Surg*. 2006;41(1):69–71.
- [5] Dayanc M, Irkilata HC, Kibar Y, Bozkurt Y, Basal S, Xhafa A. Y-type urethral duplication presented with perineal fistula in a boy. *Ger Med Sci*. 2010;29;8:Doc33.
- [6] Woodhouse CR, Williams DI. Duplications of the lower urinary tract in children. *Br J Urol*. 1979;51(6):481–87.
- [7] Rizalar R, Demirbileks Bemay F, Gurses N. H-type urethrorectal communication and complete urethral stenosis with unilateral renal agenesis. *J Pediatr Surg*. 1994;4(1):49-50.

- [8] Arena S, Arena F, Scuderi G, Di Benedetto V. An unique case of Y-type urethral duplication associated with posterior urethral valve. *Minerva Pediatr.* 2008;60(4):461–63.
- [9] Rintala RJ, Mildh L, Lindah H. H-type anorectal malformation, incidence and clinical characteristics. *J Pediatr Surg.* 1996;31(4):559-62.
- [10] De Varies PA, Friedland GW. Congenital H-type ano-urethral fistula. *Radiology.* 1974; 113(2):397-7.
- [11] Gupta NP, Ansari MS, Aron M, and Mandal S. Y duplication of the urethra with complete atresia of the orthotopic channel: 1- stage reconstruction. *J Urol.* 2000;163(3):949-50.
- [12] Sunita Singh, Jiledar Rawat. Y-type urethral duplication in children: Management strategy at our center. *J Indian Assoc Pediatr Surg.* 2013; 18(3): 100–104.

Access this article online

<http://pediatricurologycasereports.com>

Quick Response Code

