



PEDIATRIC UROLOGY CASE REPORTS

ISSN 2148-2969

<http://www.pediatricurologycasereports.com>

Penile hair tourniquet syndrome: A case report and review of literature

Virender Sekhon, Nitin J Peters, JK Mahajan

Department of Pediatric Surgery, PGIMER, Chandigarh, India

ABSTRACT

Penile hair tourniquet syndrome is a relatively uncommon clinical situation. It involves a thread of hair tied around a penis, causing strangulation which may result in various complications. It is seen mostly in circumcised boys from the developed nations. If not diagnosed early, it can lead to devastating sequelae and even loss of a vital organ. We report a case of penile hair tourniquet syndrome and a review of literature.

Key Words: Hair; penis; syndrome; tourniquets.

Copyright © 2017 pediatricurologycasereports.com

Corresponding Author: Dr. Virender Sekhon
Department of Pediatric Surgery, PGIMER, India
Email: virender.sekhon@gmail.com
Accepted for publication: 17 December 2016

Introduction

Hair tourniquet syndrome occurs when a strand of hair or occasionally a thin thread is tied around a body appendage, mostly the fingers or toes and rarely the penis. When tied around the penis, the strand of hair causes progressive strangulation and may result in various complications like urethra-cutaneous fistula, complete urethral transaction, penile gangrene and amputation. This condition is seen almost exclusively in circumcised boys, between the ages of 3 and 9 years mostly from the developed countries [1]. We report a case of this uncommon entity.

Case report

A seven years old Sikh boy, previously

circumcised for phimosis, was admitted with complaints of pain and swelling over the penis for the last six days. Attendants had noticed multiple strands of hair tied tightly around the coronal sulcus, along with penile engorgement and swelling.

Multiple hair were removed by a general practitioner, who did a compression bandage which further led to venous engorgement and superficial gangrene of right side the penile shaft [Fig. 1]. The glans and left sided skin of the penile shaft had normal vascularity and the color. The glans was mildly engorged and the patient had been successfully catheterized elsewhere. Despite pointed queries history of child abuse, sexual assault or any foul play could not be elicited. On examination, the child was averagely built for his age and gender. Abdominal examination was normal and the bladder not palpable.

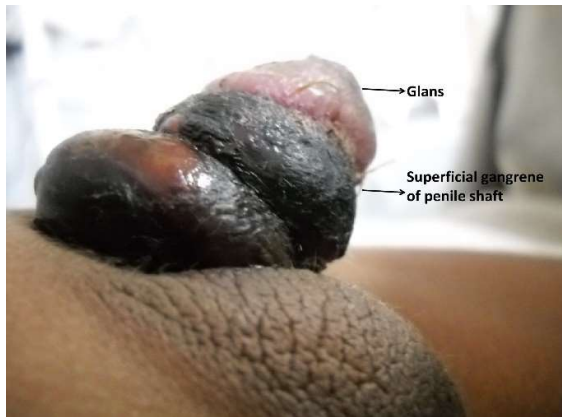

Fig. 1. Superficial gangrene of penis from hair tied around the coronal sulcus.

The patient was started on antibiotics and anti-inflammatory drugs. As there was swelling and edema of the penile shaft, the patient underwent suprapubic cystostomy under general anesthesia. There was superficial gangrene with blisters involving 2/3rd of the circumference of penile shaft. No residual entwining hair could be seen. Bilateral testis and scrotum were normal. There was no evidence of any other injury or trauma to the genito-urinary system. Post operatively, the patient did well with local antibiotic application and regular saline dressings. At the time of discharge, the superficial gangrene was completely dry and the glanular congestion had further improved [Fig. 2].

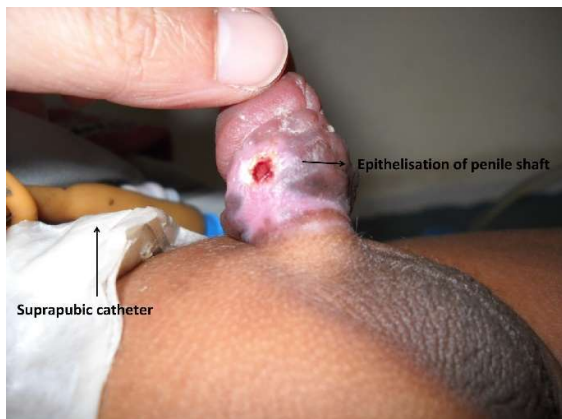


Fig. 2. Epithelialized penile shaft at 4 weeks follow-up.

In the follow up, the superficial gangrenous patch has separated with epithelialization underneath. The SPC was removed and the child now voids urine normally.

Discussion

The term 'hair-thread tourniquet syndrome' was coined by Barton et al in 1988 and refers to a condition where a strand of hair or thread or fibre encircling an appendage causes ischemic strangulation [2]. Hair strangulation of the penis was first recognized in the 1600s by Guillimeau [3] and one of the earliest reported references is from Gaultier in 1755 [4].

The usual appendages involved are fingers and penis. However, there are a few reports of strangulation of toes, labia, clitoris, mons pubis and neck [5]. This is generally a condition of very young children, but rarely, it may occur in elderly people past their sixth decade.

Penile tourniquet injury has been reported following application of numerous objects like rings, rubber bands, bottles, pipes and threads. But penile strangulation caused by hair frequently goes unrecognized and is therefore the most devastating. The process of hair-thread tourniquet syndrome may develop rapidly over hours or insidiously over months. In the latter instances, the fibre can cut-through and become buried under the skin, which may re-epithelialize obscuring the offending hair altogether [4]. The differential diagnosis in such cases should include ainhum, pseudo-ainhum [6], congenital constriction bands and pityriasis rubra pilaris.

Lymphatic obstruction from tourniquet effect of the hair leads to tissue edema on either side of the constricting band. Resultant secondary venous congestion impairs the arterial perfusion causing necrosis and tissue loss. In such a situation, pressure dressing will further

accentuate the impairment of circulation and should be avoided. This was possibly the cause of tissue loss in our patient rather than the tourniquet effect itself.

Accidental causes of penile strangulation are more common than incidental, intentional or undetermined causes. Our patient belonged to the Sikh community, where both the genders support long hair, hence there is a high probability of accidental etiology in our case. In specific instances, the child abuse must also be considered. Hair is more easily entangled around a circumcised penis than a glans covered by intact prepuce [7]. Human hair is stretchable when wet and contracts on drying. These properties along with a great tensile strength make it an effective constricting agent [8].

Penile hair-thread tourniquet syndrome may present as complete or partial amputation, urethral fistula, wasp-waist deformity or a combination of the above [3]. Bashir et al [9] have categorized severity of penile strangulation as follows:

Grade 0: Constriction of skin without urethral injury

Grade 1: Partial division of corpus spongiosum with urethro-cutaneous fistula,

Grade 2: Complete division of corpus spongiosum and constriction of corpus cavernosum,

Grade 3: Gangrene, necrosis and complete amputation of glans.

Such a progression of penile injury can be explained by the anatomical nature of the penile shaft. The skin devoid of any subcutaneous tissue is affected first. Corpora spongiosum and urethra are covered by only a thin layer of fibrous tissue, and are therefore more prone to injury than corpora cavernosa which is relatively protected by a dense fibrous layer of tunica albuginea [9].

Complete removal of the encircling fibre is the mainstay of therapy. This might warrant a surgical exploration in doubtful settings, via an infero-lateral penile incision between corpus cavernosum and corpus spongiosum [10], avoiding injury to the urethra, main nerves and the blood supply. Thereafter, the patient should be reviewed regularly to ascertain restoration of circulation and complete resolution of strangulation.

Although, hair-thread tourniquet syndrome is an uncommon entity, the pediatricians, general and family practitioners should be made aware of this condition. Prompt diagnosis and appropriate treatment can save many vital body parts.

Acknowledgements

The author(s) declare that they have no competing interest and financial support.

References

- [1] Badawy H, Soliman A, Ouf A, Hammad A, Orabi S, Hanno A. Progressive hair coil penile tourniquet syndrome: multicenter experience with 25 cases. *J Pediatr Surg*. 2010;45(7):1514-8.
- [2] Barton DJ, Sloan GM, Nichter LS, Reinisch JF. Hair-thread tourniquet syndrome *Pediatrics*. 1988;82(6):925-8.
- [3] Guillemeau J. *The Nursing of Children* [quoted by Hadda and Thomas et al]. Chapter 24. London: 1612
- [4] Gaultier J. *J de Med Chir Pharm* [quoted by Mackey et al]. 2nd ed. 1755.
- [5] Mat Saad AZ, Purcell EM, McCann JJ. Hair-thread tourniquet syndrome in an infant with bony erosion: a case report, literature review, and meta-analysis. *Ann Plast Surg*. 2006;57(4):447-52.

- [6] Corazza M, Carlà E, Altieri E, Virgili A. What syndrome is this? Tourniquet syndrome. *Pediatr Dermatol.* 2002;19(6):555-6.
- [7] Haddad FS. Penile strangulation by human hair. Report of three cases and review of the literature. *Urol Int.* 1982;37(6):375-88.
- [8] Alpert JJ, Filler R, Glaser HH. Strangulation of an appendage by hair wrapping. *N Engl J Med.* 1965;273(16):866-7.
- [9] Bashir AY, El-Barbary M. Hair coil strangulation of the penis. *J R Coll Surg Edinb.* 1980;25(1):47-51.
- [10] Kerry RL, Chapman DD. Strangulation of appendages by hair and thread. *J Pediatr Surg.* 1973;8(1):23-7.

Access this article online

<http://pediatricurologycasereports.com>

Quick Response Code

