



PEDIATRIC UROLOGY CASE REPORTS

ISSN 2148-2969

Journal homepage: <http://www.pediatricurologycasereports.com>

Labial adhesion: An office problem in pediatric urology

Govindarajan Krishna Kumar

Pediatric Surgery, Jawaharlal Institute of Postgraduate Medical Education & Research, Puducherry, India

ABSTRACT

Labial adhesion is a common gynecologic problem in childhood. It is probably associated with hypo-estrogenic state of the female infant. Labial adhesions are usually diagnosed during regular check-ups or when the fusion results in post-void dripping, vaginal irritation, dysuria, urinary tract infection or obstruction. Hence, we recommend physicians to perform genital examination in girls who show symptoms of urinary tract infection. Treatment options include topical estrogen or betmethasone creams, manual separation or adhesiolysis. Follow up of these children is important to ensure complete resolution without residual adhesion or recurrence.

Key Words: Labial adhesion, topical treatment; estrogen; children.

Copyright © 2017 pediatricurologycasereports.com

Corresponding Author Associate Prof. Dr. G. Krishna Kumar, Pediatric Surgery, Jawaharlal Institute of Postgraduate Medical Education & Research, Puducherry, India

Email: kkpeds@gmail.com

Accepted for publication: 15 June 2016

Introduction

Labial adhesions (vaginal synechiae) affect close to 2% of girls in the first few years of life with a peak incidence in the second year of life. However, its prevalence may be even greater because many patients with this condition are asymptomatic and may go undetected [1]. Although the exact etiology of labial adhesion is not known, it is probably associated with the hypo-estrogenic state of the female infant [2,3]. In these cases, the labia minora stick together in the midline, usually from posterior fourchette, until only a small opening is left

superiorly through which urine is passed and presents as labial adhesion [3].

Labial adhesions are usually asymptomatic, but they may cause symptoms such as urinary tract infection and pain during activity, post-void dripping, and abnormal urinary stream [2,4]. Labial adhesion may also present as urinary retention [5].

Estrogen cream to be applied on the labia for several weeks should be offered for young girls. Eighty percent resolve spontaneously within one year of diagnosis, but many physicians offer topical therapy in the form of Estrogen cream, to be applied on the labia for 2-3 weeks or adhesiolysis [6,7]. Here, the treatment of two girls with labial adhesions was presented. In addition, we would like to remind you once more of this office problem with the literature review.

Case 1

A 1 year old baby girl was referred by a general practitioner for “abnormal external genitalia – possible vaginal atresia”. The child was active alert and otherwise well. On examination, the labia majora were incompletely fused in the midline concealing the labia minora and the urogenital openings [Fig. 1].

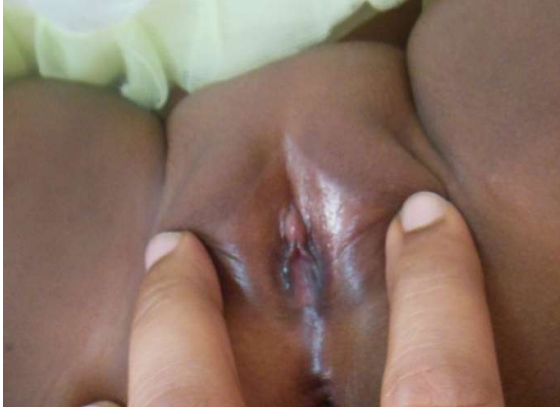

Fig. 1. Partial adhesion of labia.

A simple and gentle lysis was undertaken which resulted in clear visualization of the urethral meatus and the vagina [Fig. 2].

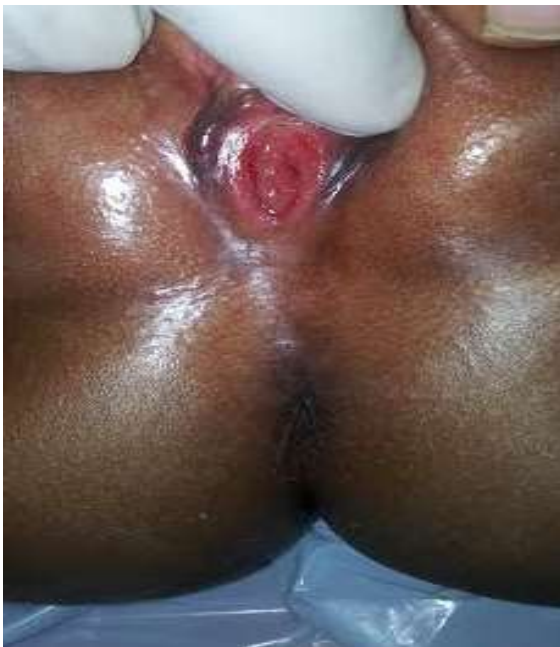

Fig. 2. Post-surgical lysis of labial adhesion.

Treatment was continued with topical vaseline application for couple of weeks. There was no recurrence at follow up beyond 6 months.

Case 2

An 18 month old girl was brought by parents with history of crying during voiding and poor urinary stream for the past few weeks. The child was well before and was otherwise reported to be normal by parents. On examination, complete labial fusion was noted [Fig. 3].

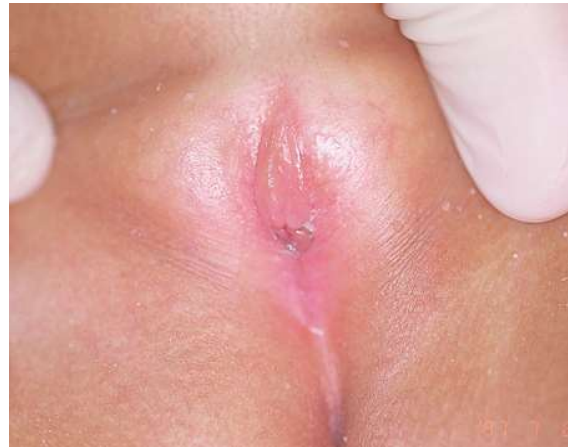

Fig. 3. Complete adhesion of labia giving the appearance of ‘absent external genitalia’.

Under local anesthesia, the labial fusion was released successfully. Treatment was continued with topical Vaseline application over the next 2 weeks. The child was well at 8 months follow up.

Discussion

Labial adhesions are common pediatric gynecological problem encountered in general pediatric practice and are associated with low estrogen conditions. They are commonly misdiagnosed or unnecessarily

investigations may be ordered [8,9]. Although labial adhesions are generally asymptomatic, the symptoms such as postvoid dribbling or vaginal voiding, associated urinary tract infection and discomfort with voiding may be noted [10-12]. In physical examination, thin, pale, semitranslucent adhesions covering the vaginal opening between the labia minora may be present. Additionally, the adhesions sometimes entirely close the vaginal opening [10-14] [Fig. 4].

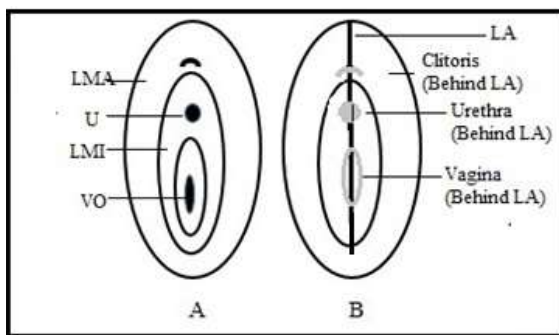


Fig. 4. A. Normal anatomy. B. Complete labial adhesion. LMA: Labia majora; U: Urethra; LMI: Labia minora; VO: Vaginal opening; LA: Labial adhesion.

Conditions to be considered in the differential diagnosis include the following: Hymenal skin tags, imperforate hymen, introital cysts (paraurethral or Gartner duct cysts, ureterocele, urethral polyp, urethral prolapse, vaginal atresia or müllerian agenesis and vaginal rhabdomyosarcoma [10-14].

Treatment of labial adhesions consists of estrogen cream application to the labia three times a day for three to four weeks [9]. This treatment usually results in success rates of 66% to 100% in opening of the labia with minimal recurrence [1]. Three studies published in the 1970s, with a total of 150 girls, reported success rates of 88% to 100% in opening of the labia, with minimal recurrence [15-17]. Another study from Turkey reported

a success rate of 66% among 49 girls [7]. Another study with 107 patients reported successful separation in 79% of patients; however, almost 40% of these patients had recurrence and needed repeated treatments [18]. Only 1 study reported a success rate of less than 50% with estrogen; it was the largest retrospective study thus far, with 262 girls [19].

A recent study compared 131 children with labial adhesions who received either topical estrogen cream only, betamethasone cream only, or a combination of the 2 for 4 weeks on average [20]. There were no significant differences among the groups, signifying that Estrogen cream is as efficacious as topical steroid cream. Of note is the cost / availability of Estrogen cream. Practically, topical Vaseline cream is equally effective in the management of this condition after adhesiolysis. Failure of separation, patients with severe adhesions or patients presenting with urinary tract infections should be managed by manual lysis using a surgical probe under topical anesthesia [9]. Additionally, surgical adhesiolysis under general anesthesia may be required in about 5-10% of cases [19]. In this study, labial adhesions were manually separated in two female children presented as an example. Treatment was continued with estrogen cream application.

In conclusion, labial adhesions, a source of great parental anxiety, are commonly misdiagnosed or unnecessarily investigations may be ordered. Hence, we recommend physicians to perform genital examination in girls who present with urinary tract symptoms. They are usually managed conservatively. Additionally, manual or surgical separation can be performed for symptomatic patients. After surgical separation of adhesions there is a 10% recurrence rate [18]. Hence, the topical

treatment should be applied for a few weeks before considering surgical alternatives [1].

Acknowledgements

The author(s) declare that they have no competing interest and financial support.

References

- [1]Goldman RD. Child health update: Estrogen cream for labial adhesion in girls. *Can Fam Physician*. 2013;59 (1):37–8.
- [2]Girton S, Kennedy C. Labial adhesion: a review of etiology and management. *Postgraduate Obstet Gynecol*. 2006;26:1
- [3]DeUgarte MC. Embryology of the urogenital system and congenital anomalies of the genital tract. In: DeCherney AH, Nathan L, Goodwin TM, Laufer N, Roman A, editors. *Current Obstetrics and Gynecologic Diagnosis and Treatment*. 11th ed. USA: Lange Medical Books/McGraw-Hill; 2013. pp. 38–66.
- [4]Bacon JL. Prepubertal labial adhesions: evaluation of a referral population. *Am J Obst Gynecol*. 2002;187(2):327–31.
- [5]Norbeck J, Ritchey M, Bloom D. Labial fusion causing upper urinary tract obstruction. *Urology*.1993;42(2):209–11.
- [6]Samuels E, Ocheke AN, Samuels NE. Labial adhesion in children at the Jos University Teaching Hospital. *Afr J Paediatr Surg*. 2016;13(1):6-8
- [7]Soyer T. Topical estrogen therapy in labial adhesions in children: therapeutic or prophylactic? *J Pediatr Adolesc Gynecol*. 2007;20(4):241-4.
- [8]Papagiani M, Stanhope R. Labial adhesions in a girl with isolated premature thelarche: the importance of estrogenization. *J Pediatric Adolesc Gynecol*. 2003; 16(1): 31-32.
- [9]Sinha A, Ojha S, Samujh R, Rao KL. Labial adhesions: facts and fiction. *Indian J Pediatr*. 2005;72(4):365.
- [10]Leung AK, Robson WL. Labial fusion and urinary tract infection. *Child Nephrol Uro* 1992; 12 (1): 62-64.
- [11]Gaudens DA, Moh-Ello N, Fiogbe M, et al. [Labial fusion in the paediatric surgery department of Yopougon University hospital (Cote d'Ivoire): 108 cases]. *Sante*. 2008;18(1):35-8.
- [12]Bacon JL, Romano ME, Quint EH. Clinical Recommendation: Labial Adhesions. *J Pediatr Adolesc Gynecol*. 2015;28 (5):405-9.
- [13]Leung AK, Robson WL, Tay-Uyboco J. The incidence of labial fusion in children. *J Paediatr Child Health*. 1993;29(3):235-6.
- [14]Caglar MK. Serum estradiol levels in infants with and without labial adhesions: the role of estrogen in the etiology and treatment. *Pediatr Dermatol*. 2007;24(4):373-5.
- [15]Capraro VJ, Greenberg H. Adhesions of the labia minora. A study of 50 patients. *Obstet Gynecol*. 1972;39(1):65-9.
- [16]Aribarg A. Topical oestrogen therapy for labial adhesions in children. *Br J Obstet Gynaecol*. 1975;82(5):424-5.
- [17]Khanam W, Chogtu L, Mir Z, Shawl F. Adhesion of the labia minora—a study of 75 cases. *Obstet Gynecol Surv*. 1978;33(5):364-5.
- [18]Schober J, Dulabon L, Martin-Alguacil N, Kow LM, Pfaff D. Significance of topical Estrogens to labial fusion and vaginal introital integrity. *J Pediatr Adolesc Gynecol*. 2006;19(5): 337-9.

- [19]Muram D. Treatment of prepubertal girls with labial adhesions. J Pediatr Adolesc Gynecol. 1999; 12(2): 67-70
- [20]Eroglu E, Yip M, Oktar T, Kayiran SM, Mocan H. How should we treat prepubertal labial adhesions? Retrospective comparison of topical treatments: estrogen only, betamethasone only, and combination estrogen and betamethasone. J Pediatr Adolesc Gynecol. 2011;24(6):389-91.

Access this article online

<http://pediatricurologycasereports.com>

Quick Response Code

