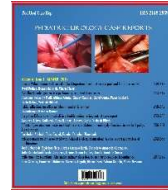



## PEDIATRIC UROLOGY CASE REPORTS

ISSN 2148-2969

Journal homepage: <http://www.pediatricurologycasereports.com>

### Classic Wilms' tumor with raised alpha-fetoprotein levels: A case report and literature review

**Jyoti Bothra, Hemanshi Shah, Charu Tiwari***Department of Pediatric Surgery, TNMC & BYL Nair Hospital, Mumbai Central, Mumbai, Maharashtra, India*

#### ABSTRACT

Tumor markers have become important in the armamentarium of diagnostic and prognostic tools in the field of oncology. With advances in the scientific research they have created a place in the management protocols of various tumors. Alpha-fetoprotein (AFP) is one such tumor marker which is known to be elevated in liver tumors and germ cell tumors, especially those with the yolk sac elements. However, there are only a few reports describing elevated AFP levels in Wilms' tumor, the second most common primary intra-abdominal malignant tumor in children. We present a case of classic Wilms' tumor with raised AFP levels which followed the trend of treatment.

**Key Words:** Wilms' tumor; alpha-fetoprotein; children.

*Copyright © 2017 pediatricurologycasereports.com*

**Corresponding Author** Dr Hemanshi Shah  
*Dept of Paediatric Surgery, TNMC & BYL Nair Hospital, Mumbai Central, Maharashtra, India.*  
Email: [hemanshisshah@gmail.com](mailto:hemanshisshah@gmail.com)  
*Accepted for publication: 25 October 2016*

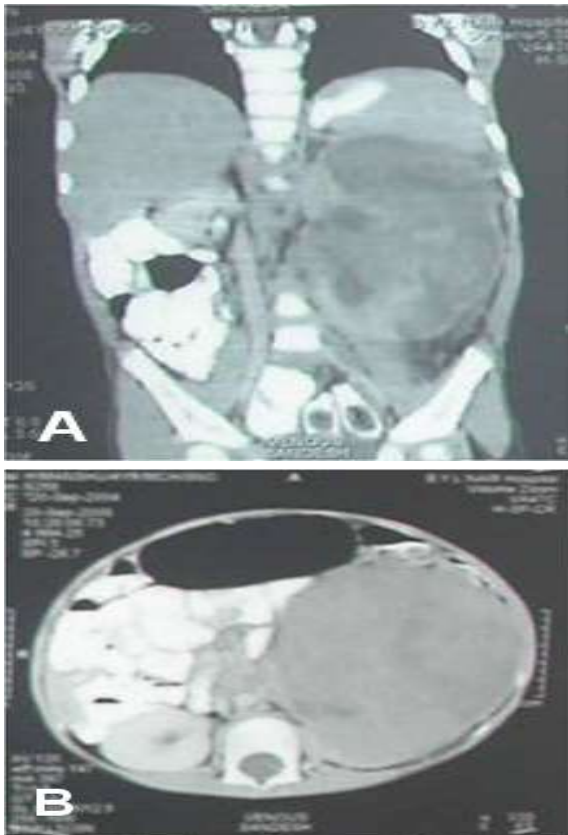
#### Introduction

Wilms' tumor is the second most common primary intra-abdominal malignant tumor in pediatric age group, representing 6%–8% of childhood malignancies. [1]. Derived from primitive metanephric blastemal cells, this tumor is known for its histopathological diversity [1]. The tumor cells generally replicate the various stages of renal embryogenesis consisting of blastemal, stromal and epithelial cells [1]. Alpha fetoprotein (AFP) is an onco-developmental

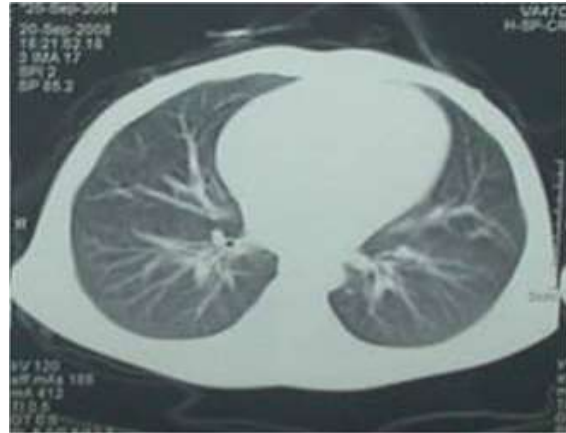antigen produced by the foetal yolk sac, liver and gut [1, 2]. At birth, its levels vary from 10,000ng/ml and 70,000ng/ml [3]. The levels decline with a half-life of 5-7 days and the normal adult levels (<10ng/ml) are attained at 8 months to 1 year of age [3]. AFP is known to be elevated in liver tumors and germ cell tumors, especially those with the yolk sac elements [1, 3]. Elevated levels of neuron specific enolase, carcinoembryonic antigen, erythropoietin and renin have been associated with Wilms' tumor in literature [1]. However, there are only a few reports describing elevated AFP levels in Wilms' tumor [1]. We describe a 4 year old boy diagnosed with a palpable left renal mass and markedly raised alpha-fetoprotein levels which followed the trend of treatment.

### Case report

A 4 year boy presented to us with an abdominal lump of ten days duration. There were no other complaints or positive history. On examination, a 12x10 cm renal lump was palpable in left lumbar region. A left testicular swelling measuring 2.5x2cm was detected on genital examination. Rest of the systemic examination was normal. An abdominal ultrasound suggested a 15x7.8 cm heterogeneous mass in left renal fossa with areas of calcification and features of left epididymitis. A contrast-enhanced computed tomography (CECT) abdomen revealed a 14x12x10cm heterogeneous mass at the upper pole of left kidney with calcified specks, areas of necrosis and degeneration suggestive of Wilms' tumor [Fig. 1A,B]. A high-resolution computed tomography (HRCT) chest showed no metastatic involvement of the lungs [Fig. 2].

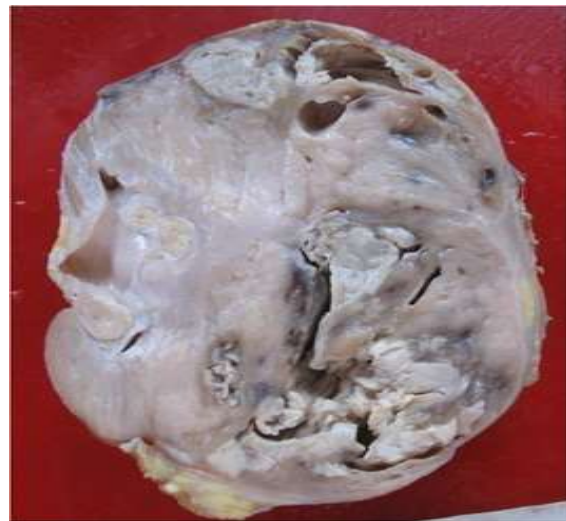

**Fig. 1A, B.** CECT Scan of the patient showing a 14x12x10cm heterogeneous mass at the upper pole of left kidney with calcified specks, areas of necrosis and degeneration suggestive of Wilms' tumor.



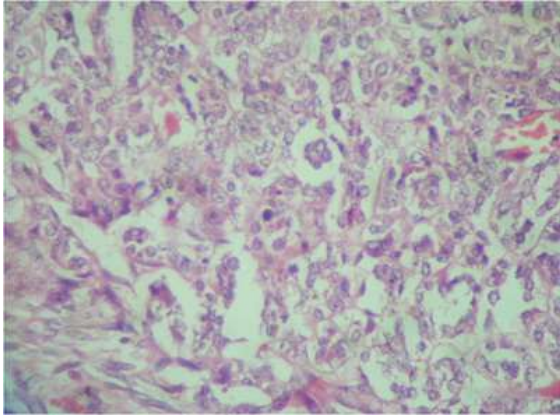
**Fig. 2.** HRCT Thorax of the patient showing no pulmonary metastases.

Patient received one cycle of neoadjuvant chemotherapy with Vincristine, Adriamycin, Actinomycin D and was reassessed 4 weeks later. A repeat ultrasound showed a decrease in the size of the lump. The AFP levels showed a middle decrease in levels on weekly assessment. A left radical nephroureterectomy was done [Fig. 3].



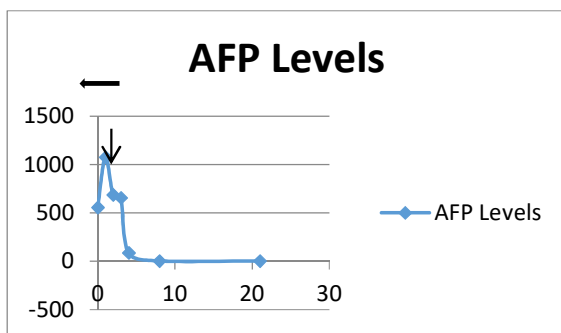
**Fig. 3.** The excised specimen.

There was no capsular breach or infiltration of hilum and the adrenal gland. Post-operative AFP level was 86ng/ml. Histopathology reported presence of dysplastic tubules with blastemal and stromal components suggestive of classic triphasic Wilms' tumor [Fig. 4].



**Fig. 4.** Histopathology presence of dysplastic tubules with blastemal and stromal components suggestive of classic triphasic Wilms' tumor.

Adjuvant chemotherapy was given. A follow up ultrasound was normal and AFP level at end of regimen was 3.5ng/ml [Fig. 5]. Patient has no complaints on follow up.



**Fig. 5.** Scatter diagram showing the trend of AFP levels (block arrow: start of chemotherapy and thin arrow: surgery)

### Discussion

Wilms' tumor was named after 19<sup>th</sup> century German pathologist and surgeon Carl Max

Wilhelm Wilms [4]. It is known to be derived from the primitive metanephric blastema and has marked histological diversity [1]. The histopathology of a classical Wilms' tumor consists of blastemal, stromal and epithelial cells [1]. However, the occurrence of the three cell types in same case is uncommon [1, 5].

The diagnosis of this tumor is generally based on the clinical findings of a firm to hard renal lump followed by radiological investigations. Pretreatment biopsy is based on the choice of the protocol (SIOP v/s NWTs) followed by the attending surgeon. Tumor markers have predictive value in diagnosis and follow-up of children with solid malignancies [6].

Elevated levels of some tumor markers such as neuron specific enolase, hyaluronic acid, carcinoembryonic antigen, erythropoietin and renin have reported in Wilms' tumor [7].

Additionally, an elevated level of serum AFP is mainly found in cases such as hepatoblastoma, hepatocellular carcinoma, malignant germ cell tumors, and some immature teratomas containing yolk salk elements [8].

However, very few reports describe association of raised AFP levels in Wilms' tumor [1]. The first such case of raised AFP in Wilms' tumor was reported in 1984 by Roth et al [1, 9]. They reported a case with prenatal diagnosis of bilateral renal tumor undergoing left polar nephrectomy and right nephrectomy after birth. Histopathological study showed an unusual type with both nephroblastomatous and teratomatous embryonal appearing cells [9]. Elevated AFP has been reported to occur in teratoid Wilms' tumor, in which the teratoid elements constitute more than 50% of the tumor [1]. This increase in AFP levels can be explained by AFP-producing teratoid elements present in this subtype of Wilms' tumor [2]. Ashworth et al reported that raised AFP

decreased to normal after nephrectomy in teratoid Wilms' tumor [1,10]. They demonstrated by immunohistochemistry that the AFP containing cysts lined by enteric-type epithelium within the tumor were the source of AFP [1, 10].

There are only few reports describing raised AFP in classic Wilms' tumor [1, 8, 9, 11, 12]. Patriarca et al in 1992, Kismet Erol in 2005, A. Crocoli in 2008, V. Kesik et al in 2010 and Dhungel et al in 2014 have reported elevated AFP in classic Wilms' tumors. They reported that the tumor did not show regression either on clinical or pathologic assessments and serum AFP levels decreased after preoperative chemotherapy, but returned to normal limits after nephrectomy. [1, 8, 9, 11,12]. Kismet et al [8] suggested that persistence of high AFP level during preoperative chemotherapy period could reflect a poor response to chemotherapy. In our case, the tumor showed dimensional regression after preoperative chemotherapy and the elevation of AFP middle responded to chemotherapy and returned to normal after nephrectomy. AFP levels have been reported to be higher in patients with metastatic disease, than in one case with thrombosis in inferior vena cava [1, 12].

This case also had an associated testicular swelling, which in fact was the reason for investigating the AFP levels. However the biopsy of the testicular swelling was reported as only inflammatory changes hence ascertaining the association of the AFP levels to the renal mass. The tumor marker as in other reported cases followed the trend of treatment and decreased after preoperative chemotherapy and normalized after nephrectomy.

## Acknowledgements

The author(s) declare that they have no competing interest and financial support.

## References

- [1]Dhungel S, Cheng LJ, Zhi Hai Z. Elevated serum alpha-fetoprotein in Wilms' tumor: A case report with review of literature. *J Ped Surg Case Reports*. 2014; 2(3):153 –5.
- [2]Kesik V, Ozcan A, Sari E, Guven A, Kismet E, Koseoglu V. Alpha-fetoprotein producing tumor cells in children with Wilms' tumor. *Fetal Pediatr Pathol*. 2010;29(3):127-32.
- [3]Singal AK, Agarwala S. Tumour markers in pediatric solid tumours. *J Indian Assoc Pediatr Surg*. 2005; 10(3): 183-190.
- [4]Ehrlich PF, Shamberger RC. Wilms' Tumour in: O'Neil JA Jr, Rowe MI, Grosfeld JL, Fonkalsrud EW, Coran AG, editors. *Pediatric Surgery*. 5th ed. Mosby, New York, USA. 1998. p. 423-40.
- [5]Ebb DH, Green DM, Shamberger RC, Tarbell NJ. Solid tumours of childhood. In *cancer principles and practice of oncology*. In: DeVita Jr VT, Hellman S, Rosenberg SA, editors. Philadelphia: Lippincott Williams and Wilkins; 2005.
- [6]Sandoval JA, Malkas LH, Hickey RJ. Clinical significance of serum biomarkers in pediatric solid mediastinal and abdominal tumors. *Int J Mol Sci*. 2012;13(1):1126-53.
- [7]Coppes M.J. Serum biological markers and paraneoplastic syndromes in Wilms tumor. *Med Pediatr Oncol*. 1993;21(3):213–21.
- [8]Erol K, Vedat K, Erkan D, Mustafa G, Duygu H, Avni AA, Suzi D. Wilms tumor associated with elevated alpha-fetoprotein level. *Pediatr Blood Cancer*. 2005;44(4):423-4.

- [9]Roth A. An unusual renal tumor, associating nephroblastoma, nephroblastomatosis teratoma, and cysticdysplasia with arterial hypertension and secretion of alpha fetoprotein. *J Urol (Paris)*.1984;90(1):7-10.
- [10]Ashworth MT, Pizer BL, Oakhill A, Spicer RD, Berry PJ. A teratoid Wilms' tumor with raised serum alpha-fetoprotein level. *Pediatric Pathol Lab Med*. 1996;16(5):853-9.
- [11]Patriarca C, Orazi A, Massimino M, Luksch R. A cystic partially differentiated nephroblastoma producing a-fetoprotein. *Am J Pediatric Hematol Oncol*. 1992;14(4):352–55.
- [12]Crocoli A, Madafferi S, Jenkner A, Zaccara A, Inserra A. Elevated serum alpha-fetoprotein in Wilms' tumour may follow the same pattern of other fetal neoplasms after treatment: evidence from three cases. *Pediatr Surg Int*. 2008; 24(4):499-502.

