



CODEN [USA]: IAJPBB

ISSN: 2349-7750

INDO AMERICAN JOURNAL OF PHARMACEUTICAL SCIENCES

<http://doi.org/10.5281/zenodo.1194805>

Available online at: <http://www.iajps.com>

Research Article

RETROSPECTIVE ANALYSIS OF SAFETY AND EFFICACY OF DIAGNOSTIC ENDOSCOPY V/S NONINVASIVE MARKERS IN U.G.I.B IN PATIENTS CO-PRESENTING WITH LIVER CIRRHOSIS & ACUTE STEMI

Muhammad Iqbal¹, Atif Ahmed², Sohail Baig³ and Hamid Nawaz Ali Memon⁴

¹Department of Medicine - Liaquat University of Medical & Health Sciences, Jamshoro

²Department of Medicine - Bilawal Medical College, Jamshoro

³Department of Medicine – Liaquat University Hospital, Hyderabad

Zulekha Hospital - Dubai, United Arab Emirates

Abstract:

Background: Endoscopy is routinely recommended as a diagnostic procedure in patients presenting with upper gastrointestinal tract bleeding (UGIB). An example being, instances where patients with liver cirrhosis present with UGIB stemming from probable esophageal varices. However, among many contraindication for the procedure, acute ST elevation myocardial infarction is perhaps the most absolute (whose, post-PCI adjuvant pharmaceutical treatment too may result in UGIB). Since comorbidities are common among chronic liver disease patients, instances of such contraindications are becoming common.

Objective: This study hopes to assess the efficacy and safety of diagnostic endoscopy v/s non-invasive markers of probable causes of UGIB in patients with a history of liver cirrhosis and acute ST elevation myocardial infarction.

Methodology: This retrospective analysis was conducted upon a total of 43 cases presenting with UGIB and a history of liver cirrhosis and acute STEMI to the medical out-patient department of Liaquat University Hospital, Hyderabad. Data was derived from patient files in the hospital record. The data obtained was analyzed using MS. Excel 2017 and SPSS v. 21.0.

Results: The safety of non-invasive markers and efficacy of diagnostic endoscopy are gold-standard. And hence the efficacy of the former and safety of the later where in question in this research. Out of the total cases co-presenting with liver cirrhosis and acute STEMI, only 43 had a complete work-up to yield ample information meriting inclusion in this study. 23 of the endoscopically evaluated cases encountered side-effects ranging from mild to severe, while 3 faced eventual mortality. The efficacy neither of the non-invasive markers for diagnosing a probable cause of upper gastro-intestinal bleeding, rose above 50%.

Conclusion: Safe and effective predictors (invasive and non-invasive) of probable cause of UGIB must be identified to act as a substitute in cases where diagnostic endoscopy is absolutely contraindicated. Unfortunately neither of the tested markers yielded satisfactory effects, thus more research is needed.

Keywords: Upper Gastro-Intestinal Bleeding, Liver Cirrhosis, Acute ST Elevation Myocardial Infarction, iagnostic Endoscopy, Therapeutic Endoscopy and Non-Invasive Markers.

Corresponding author:

Dr. Muhammad Iqbal,

Associate Professor of Medicine,

Liaquat University, Jamshoro

Email: muhammadiqbalshah22@gmail.com

Phone: +92-300-3034963

QR code



Please cite this article in press as Muhammad Iqbal et al., *Evaluation of Frequency and Severity of Anxiety and Mood Disorders among Patients with Graves 'disease, Indo Am. J. P. Sci, 2018; 05(02).*

INTRODUCTION:

Upper gastrointestinal bleeding (UGIB) is a medical situation that is common-found nowadays. The history of medical advancements beholds important changes that have occurred to influence the etiology and incidence of UGIB. [1] While the incidence has risen considerably [2] and the etiology has become more diverse and complex, [3] the outcome however, has not changed much. [2]

Widespread infection with *Helicobacter pylori* (*H. pylori*) hiked the incidence in 1983 [2] but it was brought down with the advent of proton pump inhibitors in 1988. [4] PPIs not only prevented *H. pylori* induced ulcer recurrence and complications, but also brought down UGIB associated with concomitant nonsteroidal anti-inflammatory drug use [5] and/or use of aspirin. [6]

Aspirin is also used alongside clopidogrel, inhibitors of glycoprotein IIb/IIIa and agents of anticoagulation namely (but not limited to), low molecular weight or unfractionated heparin, as part of therapy among patients of acute ST elevation myocardial infarction. Hence UGIB is also common among the patients taking aforementioned therapy. [7] In this regard, every 7 among 100 patients receiving the aforementioned therapy may encounter major hemorrhage following administration [8]. Although a great deal of said episodes are ultimately proven to be brought about by hemorrhage at vascular access sites [9], 2 out of every 100 patients on said therapy, provably experience gastrointestinal bleeding. [8]

As stated earlier, UGIB has many manifestations, among which, esophageal varices (secondary to liver cirrhosis) is common. [9] It is estimated that more than half of all patients with liver cirrhosis are found to have esophageal varices upon presentation to the hospital. Furthermore, an additional fifteen to twenty percent of patients with liver cirrhosis develop UGIB every year, owing to varices in their esophagus. In addition to that, twenty to thirty percent of the said patients encounter eventual mortality within the first four to six weeks because of this bleeding. [10]

Endoscopy is routinely advised as a diagnostic procedure to patients presenting with upper gastrointestinal tract bleeding. [11] An example being, instances where patients with liver cirrhosis present with UGIB stemming from probable esophageal varices. However, among many contraindication for the procedure, acute STEMI is

perhaps the most absolute (whose, post-PCI adjuvant pharmaceutical treatment too may result in UGIB). Nearly one percent of all patients undergoing diagnostic endoscopy within thirty days of an acute episode of STEMI face untimely mortality associated with the procedure. [12] When compared to the mortality rates of 0.1% following this procedure normally for evaluation of UGIB (and in absence of a history of such cardiac mal-events), there is a stark difference. [13]

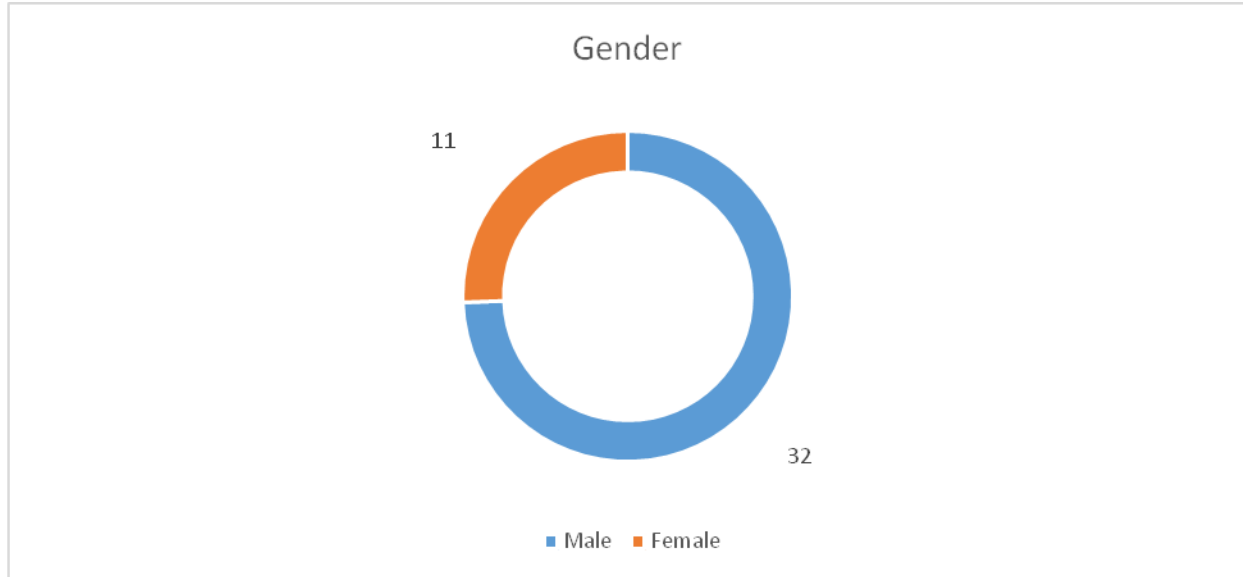
The decision of whether to perform endoscopy in a patient with recent AMI must consider these factors against the potential diagnostic and therapeutic yield of endoscopy. Since comorbidities, such as chronic liver disease are common among cardiac patients, instances of such contraindications are becoming common. This study hopes to assess the efficacy and safety of diagnostic endoscopy v/s non-invasive markers of probable causes of UGIB in patients with a history of liver cirrhosis and acute ST elevation myocardial infarction.

METHODOLOGY:

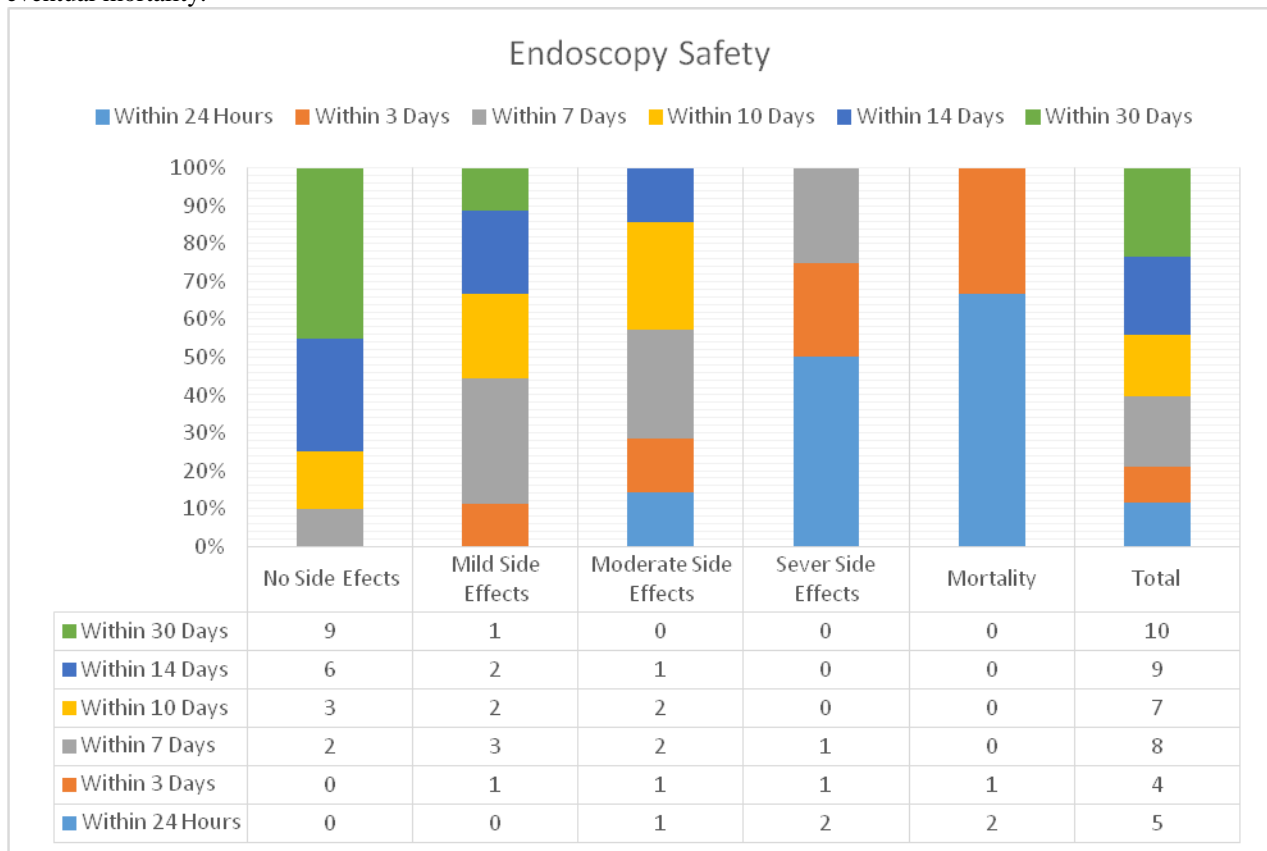
This retrospective analysis was conducted upon a total of 43 cases presenting with and a history of liver cirrhosis and acute STEMI to the medical out-patient department of Liaquat University Hospital, Hyderabad. The subjects were then referred and endoscopy was performed at the Liaquat University Teaching Hospital, Jamshoro. Data, such as the patients' diagnosis, time elapsed since development of liver cirrhosis and acute STEMI, in addition to the pharmaceutical therapy details that they were being administered and details pertaining to presenting complaint, history of presenting complaint, general health condition and others, was derived from patient files in the hospital record from January 2016 to March 2016. The data obtained was analyzed using MS. Excel 2017 and SPSS v. 21.0.

RESULTS:

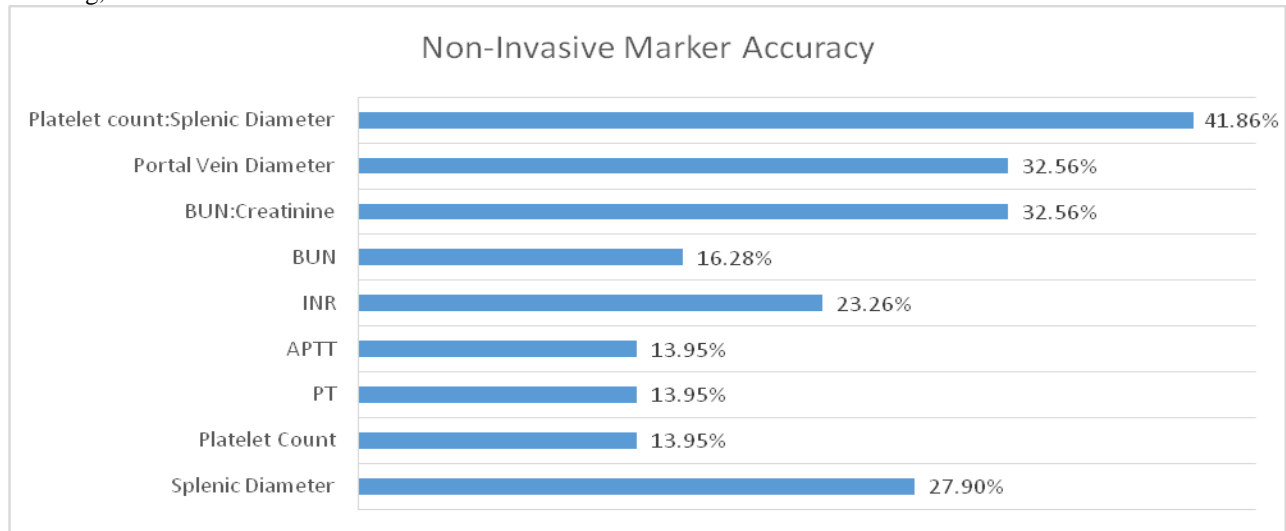
The safety of non-invasive markers and efficacy of diagnostic endoscopy are gold-standard. And hence the efficacy of the former and safety of the later where in question in this research. Out of the total cases co-presenting with liver cirrhosis and acute STEMI, only 43 had a complete work-up to yield ample information meriting inclusion in this study. 32 among the subjects were males, while 11 were females. The mean age of the sample stood at 54 years.



23 of the endoscopically evaluated cases encountered side-effects ranging from moderate to severe, while 3 faced eventual mortality.



The accuracy of neither of the non-invasive markers for diagnosing a probable cause of upper gastrointestinal bleeding, rose above 50%.



DISCUSSION:

All evidence based guidelines recommend the use of endoscopy as the prime diagnostic criteria for UGIB, especially the UGIB suspected due to esophageal varices among chronic liver disease patients. [14] These evidence based guidelines, however, are not feasible in the event of an acute ST elevation myocardial infarction. Thus, researchers have strived continuously to unearth different noninvasive markers for detecting the probable cause of UGIB. [15, 16] Our research put the following noninvasive markers to the test – platelet count, portal vein diameter, splenic diameter, platelet count: splenic diameter, blood urea nitrogen, blood urea nitrogen: creatinine level.

The pool of evidence based literature has abundant proof of a linear relationship of thrombocytopenia with the extent and severity of esophageal varices. [17 - 19] Thus, in addition to the markers investigated in abundance, we also took into the account, non-invasive markers such as PT, APTT and INR. Among the prominent examples, Jamil et al, found that thrombocytopenia is a good indicator of existing esophageal varices. [9].

Usage of transabdominal ultrasound to determine the diameter of portal vein, as a predictor for probable cause of UGIB, is debatable. According to Jamil et al, it yield unreliable results. Others too show similar findings with ultrasound assisted variables such as vessel diameter. [18] A few, however, report findings that contract those of Jamil et al, and suggest ultrasound assisted markers to be useful predictors for probable causes (such as esophageal varices) of UGIB. [20, 21]

Although mentioned earlier, the effects of aspirin, clopidogrel, inhibitors of glycoprotein IIb/IIIa and agents of anticoagulation namely (but not limited to), low molecular weight or unfractionated heparin, as part of therapy among patients of acute ST elevation myocardial infarction, merit further discussion because UGIB is also common among the patients taking aforementioned therapy. [7] Up to 7% of patients may experience major hemorrhage following administration of this therapy [8]. Thus markers such as, PT, APTT and INR too are important indicators of a probable cause of UGIB. Thus if these markers are significantly deranges, it may be feasible to start with adjusting the pharmaceutical therapy to maintain a suitable INR in cases of minor UGIB. If the UGIB halts with these measures, it is safe to postpone, if not altogether cancel diagnostic endoscopy till it becomes safe to perform the procedure in acute STEMI cases.

CONCLUSION:

Safe and effective predictors (invasive and non-invasive) of probable cause of UGIB must be identified to act as a substitute in cases where diagnostic endoscopy is absolutely contraindicated. Unfortunately neither of the tested markers yielded satisfactory effects, thus more research is needed.

REFERENCES:

1. Czernichow P, Hochain P, Nousbaum JB, et al. Epidemiology and course of acute upper gastrointestinal haemorrhage in four French geographical areas. *Eur J Gastroenterol Hepatol* 2000;12:175–81.

2. Van der Hulst RW, Rauws EA, Koycu B, et al. Prevention of ulcer recurrence after eradication of *Helicobacter pylori*: A prospective long-term follow-up study. *Gastroenterology* 1997;113:1082–6.
3. Graham DY, Hepps KS, Ramirez FC, et al. Treatment of *Helicobacter pylori* reduces the rate of rebleeding in peptic ulcer disease. *Scand J Gastroenterol* 1993;28:939–42.
4. Labenz J, Borsch G. Highly significant change of the clinical course of relapsing and complicated peptic ulcer disease after cure of *Helicobacter pylori* infection. *Am J Gastroenterol* 1994;89:1785–8.
5. Lai KC, Hui WM, Wong WM, et al. Treatment of *Helicobacter pylori* in patients with duodenal ulcer hemorrhage—a longterm randomized, controlled study. *Am J Gastroenterol* 2000; 95:2225–32
6. Yeomans ND, Tulassay Z, Juhasz L, et al. A comparison of omeprazole with ranitidine for ulcers associated with nonsteroidal antiinflammatory drugs. Acid Suppression Trial: Ranitidine versus Omeprazole for NSAID-associated Ulcer Treatment (ASTRONAUT) Study Group. *N Engl J Med* 1998;338: 719–26.
7. Eeley AC, Boura JA, Grines CL. Primary angioplasty versus intravenous thrombolytic therapy for acute myocardial infarction: a quantitative review of 23 randomised trials. *Lancet*. 2003;361:13–20.
8. Kinnaird TB, Stabile E, Mintz GS, et al. Incidence, predictors, and prognostic implications of bleeding and blood transfusion following percutaneous coronary interventions. *Am J Cardiol*. 2003;92:930–935.
9. Jamil Z, Malik M, Durrani AA. Platelet count to splenic diameter ratio and other noninvasive markers as predictors of esophageal varices in patients with liver cirrhosis. *Turk J Gastroenterol*. 2017 Sep 1;28:347-52.
10. Kang W, Kim SU, Ahn SH. Non-invasive prediction of forthcoming cirrhosis-related complications. *World J Gastroenterol* 2014; 20: 2613-23.
11. Abbas AE, Brodie B, Dixon S, et al. Incidence and prognostic impact of gastrointestinal bleeding after percutaneous coronary intervention for acute myocardial infarction. *Am J Cardiol*. 2005;96:173–176.
12. Lin S, Konstance R, Jollis J, et al. The utility of upper endoscopy in patients with concomitant upper gastrointestinal bleeding and acute myocardial infarction. *Dig Dis Sci*. 2006;51:2377–2383.
13. Gilbert DA, Silverstein FE, Tedesco FJ. National ASGE survey on upper gastrointestinal bleeding: complications of endoscopy. *Dig Dis Sci*. 1981;26:55S–59S,
14. Garcia-Tsao G, Sanyal AJ, Grace ND, Carey W. Prevention and management of gastroesophageal varices and variceal hemorrhage in cirrhosis. *Hepatology* 2007; 46: 922-38
15. Cho EJ, Kim MY, Lee J-H, et al. Diagnostic and Prognostic Values of Noninvasive Predictors of Portal Hypertension in Patients with Alcoholic Cirrhosis. *PLoS One* 2015;h10: e0133935.
16. Nashaat EH, Abd-Elaziz H, Sabry M, Ibrahim AA. Non-endoscopic predictors of esophageal varices and portal hypertensive gastropathy. *Nat Sci* 2010; 8: 43-50.
17. Abbasi A, Butt N, Bhutto AR, Munir SM. Correlation of thrombocytopenia with grading of esophageal varices in chronic liver disease patients. *J Coll Physicians Surg Pakistan* 2010; 20: 369-72.
18. Giannini E, Botta F, Borro P, et al. Platelet count/spleen diameter ratio: proposal and validation of a non-invasive parameter to predict the presence of oesophageal varices in patients with liver cirrhosis. *Gut* 2003; 52: 1200-5.
19. Abd-Elsalam S, Habba E, Elkhawany W, et al. Correlation of platelets count with endoscopic findings in a cohort of Egyptian patients with liver cirrhosis. *Medicine (Baltimore)* 2016; 95: e3853.
20. Zhuang Y, Ding H, Han H, et al. Clinical value of contrast-enhanced ultrasound in evaluating portal hypertension in patients with decompensated liver cirrhosis. *Zhonghua Gan Zang Bing Za Zhi* 2016; 24: 270-4.
21. Sudha Rani KVL, Sudarsi B, Siddeswari R, Manohar S. Correlation of portal vein size with esophageal varices severity in patients with cirrhosis of liver with portal hypertension. *IJSRP* 2015; 5: 1-5.